

Periosteal Anchoring Sutures: A Simple Method to Prevent Postoperative Ectropion

Defects involving the internal canthus or the anterior lamella of the lower eyelid are relatively common in dermatological surgery. These defects are usually due to the excision of basal cell carcinomas, squamous cell carcinomas, and malignant melanomas, although xanthelasmas and other benign conditions may also lead to similar lower eyelid defects. Regardless of the chosen reconstructive technique, vertical tension vectors are often created, potentially leading to functional and/or aesthetic deformities.^[1] Chronic ectropion results in exposure keratinization of the conjunctiva, which contributes to ocular irritation and may lead to loss of vision.^[2] We report a simple method using periosteal anchoring sutures to prevent postoperative ectropion.

A 78-year-old woman was referred to our Dermatologic Surgery Department due to a nodular basal cell carcinoma

in the internal canthus of the left eye, confirmed by skin biopsy [Figure 1A]. Surgery was performed under local anesthesia with 2% lidocaine and 1:100,000 epinephrine. The tumor and a margin of 5 mm were excised, resulting in a 2.1 cm × 1.9 cm × 1.4 cm defect, involving the internal canthus and the anterior lamella of the left inferior eyelid [Figure 1B]. A lateral based malar advancement flap was performed to reconstruct the defect. However, after the advancement of the flap, 3 superficial small linear incisions were made, 5 mm away from the flap's superior margin. A 4-0 Vicryl suture was then passed through each incision to reach the orbital margin of the maxillary periosteum [Figure 1C]. After crossing the periosteum, the subcutaneous fat and the dermis was once again sutured, and a standard knot was tied at the surface of the incision [Figure 1D]. Ultimately, the redundant flap was trimmed, and the wound was closed using a 5/6-0 nonabsorbable,

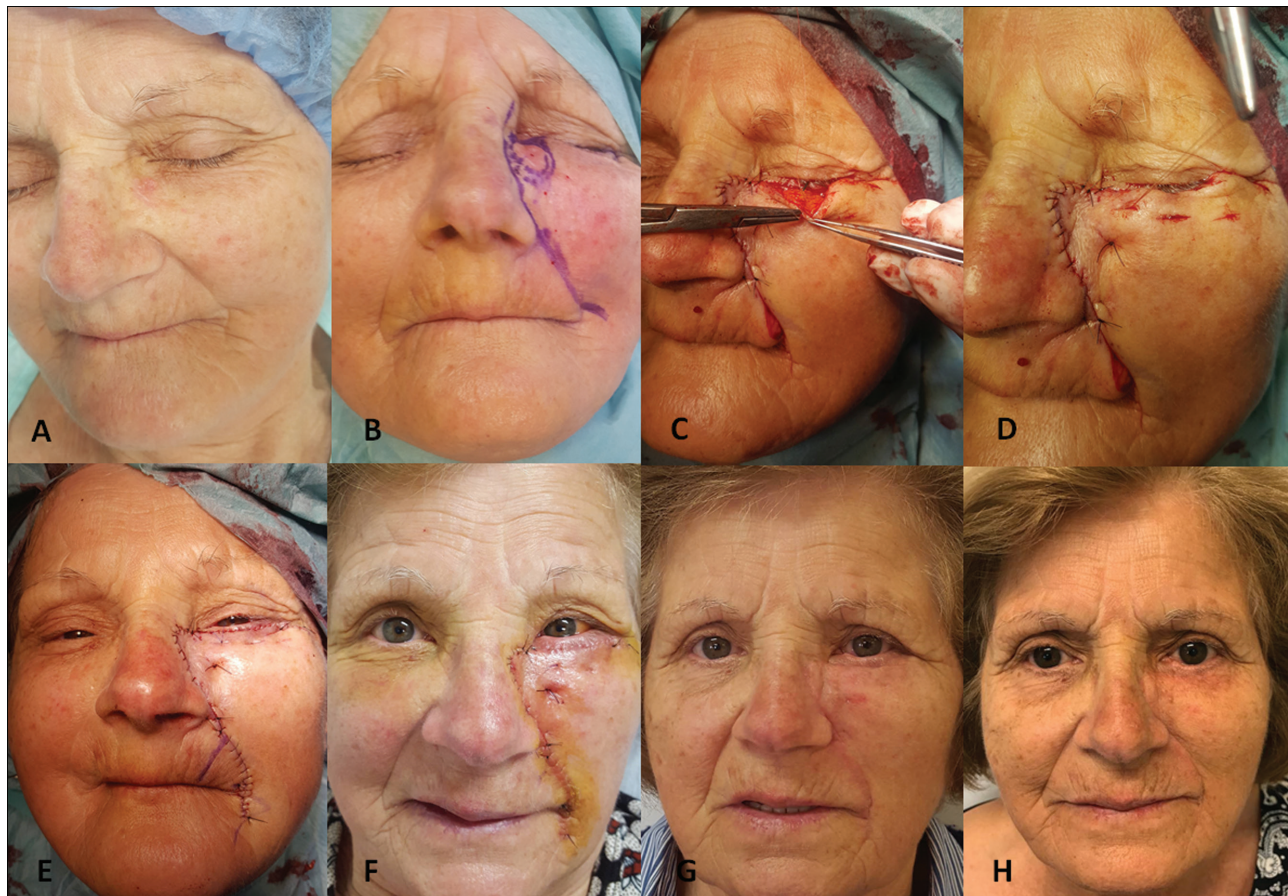


Figure 1: (A) Basal cell carcinoma in the left inner canthus. (B) Surgical planning with malar advancement flap. (C) Anchoring suture reaching orbital rim periosteum. (D) Periosteal anchoring suture in place. (E) Intraoperative result. (F) 1-week follow-up. (G) 1-month follow-up. (H) 6-month follow-up

sterile monofilament suture [Figure 1E]. No postoperative complications were noted [Figure 1F–G]. The margins of the specimen were disease-free. Six months after surgery, an excellent cosmetic outcome was observed [Figure 1H].

From a technical perspective, it is important to note that anchoring a soft tissue to a rigid structure, prevents the creation of vertical stress vectors on the lower eyelid, that would possibly contribute to the formation of postoperative ectropion. In addition, the placement of more than one anchoring suture along the orbital rim allows the tensions vectors to be more evenly distributed and cause less retraction in a single point of application.

We highlight with our case that the use of periosteal anchoring sutures in the reconstruction of lower eyelids defects is a simple and effective method to avoid postoperative ectropion, resulting in excellent aesthetic results and minimal scar formation. Another potential advantage of this technique is its applicability to different reconstructive options including primary closure, grafts, and other types of flaps.

Declaration of patient consent

The authors certify that they have obtained all appropriate patient consent forms. In the form the patient(s) has/have given his/her/their consent for his/her/their images and other clinical information to be reported in the journal. The patients understand that their names and initials will not be published and due efforts will be made to conceal their identity, but anonymity cannot be guaranteed.

Financial support and sponsorship

Nil.

Conflicts of interest

There are no conflicts of interest.

Diogo Cerejeira, Frederico Bonito, Joao Goulao

Department of Dermatology, Hospital Garcia de Orta, Almada, Portugal

Address for correspondence: Dr. Diogo Cerejeira,
Department of Dermatology, Hospital Garcia de Orta, Rua Marta Mesquita da
Câmara nº110 A3 4ºDto. 4150-485 Porto, Portugal.
E-mail: diogo_cerejeira@hotmail.com

REFERENCES

1. Hayano SM, Whipple KM, Korn BS, Kikkawa DO. Principles of periocular reconstruction following excision of cutaneous malignancy. *J Skin Cancer* 2012;2012:438502.
2. Jelks GW, Jelks EB. Prevention of ectropion in reconstruction of facial defects. *Clin Plast Surg* 2001;28:297-302, viii.

This is an open access journal, and articles are distributed under the terms of the Creative Commons Attribution-NonCommercial-ShareAlike 4.0 License, which allows others to remix, tweak, and build upon the work non-commercially, as long as appropriate credit is given and the new creations are licensed under the identical terms.

For reprints contact: reprints@medknow.com

Access this article online	
Quick Response Code: 	Website: www.jcasonline.com
	DOI: 10.4103/JCAS.JCAS_17_20

How to cite this article: Cerejeira D, Bonito F, Goulao J. Periosteal anchoring sutures: A simple method to prevent postoperative ectropion. *J Cutan Aesthet Surg* 2020;13:368-9.