

Use of Plastic Syringe as a Splint for Contracted Fingers

Dear Editor,

Splints are used to immobilise the body parts following injury and surgeries which help in faster healing. Here, we report the innovative use of a plastic syringe as a post-operative splint to straighten contracted middle and ring fingers. The present case is a 69-year-old female who presented to the outpatient department with a history of an ulcer over the dorsal aspect of right hand since 1 year. She gave history of a burn injury at 10 years of age. On examination, there was an ulcer of 4 cm × 3 cm size on the dorsal aspect of right hand and contracture of the middle and ring fingers at proximal and interphalangeal joint [Figure 1]. Incisional biopsy from the ulcer was reported as squamous cell carcinoma. After wide excision of the ulcer over dorsum of hand, the area was covered with split skin graft. Contractures on the ventral aspect of the fingers were released with multiple Z-plasty incision. After straightening the fingers, skin graft was also placed on the defect. We used a sterile 10 ml plastic syringe as a splint, which was cut open longitudinally and splinted on the dorsum to straighten right middle and ring fingers [Figure 2]. Sterile pad dressing was done over the splint and grafted area. This helped the fingers remain straight. It also immobilised the operated site including grafted area of ventral aspect of the fingers. We have used the easily available plastic syringes instead of aluminium or other newer splints.^[1,2] The patient was discharged on the 5th postoperative day with the splint in place. The splint was removed on the 14th postoperative day which showed complete healing of the grafted site and straightening of the fingers. Final histopathology was reported as well differentiated squamous cell carcinoma with free resected margin. Further, patient was advised for physiotherapy and regular follow-up.

We report the use of plastic syringe as a splint for stabilising the fingers which is an easily available and cost effective material.

Financial support and sponsorship

Nil.

Conflicts of interest

There are no conflicts of interest.

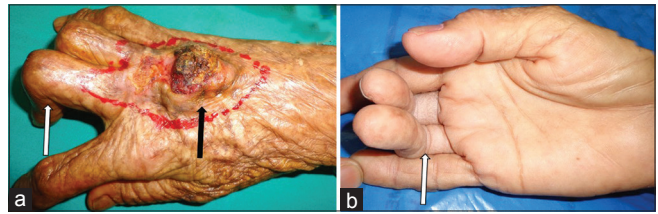


Figure 1: (a) Ulcer on the dorsal aspect of right hand and contracture (arrow) of the middle and ring fingers at proximal and interphalangeal joint on dorsal aspect. (b) Contracture (arrow) of the middle and ring finger at proximal and interphalangeal joint on ventral aspect

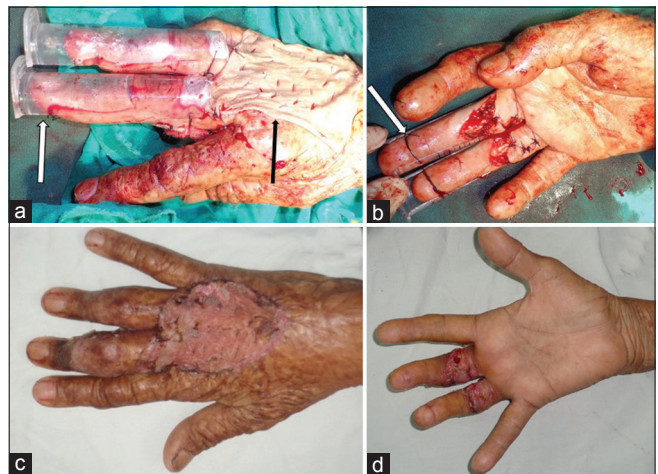

Figure 2: (a) Syringe splint on middle and ring fingers and skin graft on right hand. (b) Release of contracture by Z-plasty incision and syringe splint. (c) Dorsal aspect of healed and straightened contracted fingers on removal of splint. (d) Ventral aspect of healed and straightened contracted fingers on removal of splint

**Amitabh Jena, Gajjala Venkata Sivanath Reddy,
Naru Ramana Reddy, Rashmi Patnayak¹,
Banoth Manilal**

Departments of Surgical Oncology and ¹Pathology,
Sri Venkateswara Institute of Medical Sciences, Tirupati,
Andhra Pradesh, India

Address for correspondence: Dr. Amitabh Jena,
Department of Surgical Oncology, Sri Venkateswara Institute
of Medical Sciences, Tirupati - 517 507, Andhra Pradesh, India.
E-mail: dramitabh2004@yahoo.com

REFERENCES

1. Acartürk TO, Ashok K, Lee WP. The use of external skeletal fixation to facilitate the surgical release of wrist flexion and thumb web space contractures. *J Hand Surg Am* 2006;31:1619-25.
2. Sarifakioglu N, Aslan G, Bingül F. The multipurpose syringe: Finger splints. *Plast Reconstr Surg* 2002;110:1190-1.

This is an open access article distributed under the terms of the Creative Commons Attribution-NonCommercial-ShareAlike 3.0 License, which allows others to remix, tweak, and build upon the work non-commercially, as long as the author is credited and the new creations are licensed under the identical terms.

Access this article online

Quick Response Code:**Website:**

www.jcasonline.com

DOI:

10.4103/0974-2077.184053

How to cite this article: Jena A, Reddy GV, Reddy NR, Patnayak R, Manilal B. Use of plastic syringe as a splint for contracted fingers. *J Cutan Aesthet Surg* 2016;9:132-3.