

Structural Changes of Fat Tissue After Nonaspirative Ultrasonic Hydrolipoclasys

Background: Hydrolipoclasys is an alternative technique less invasive than liposuction. Hydrolipoclasys uses normal saline or hypotonic solution and ultrasound waves that act directly on local adiposity. In the literature there are few reports of morphostructural changes on adipose tissue. **Materials and Methods:** This study was aimed to evaluate the amount of fat cells injured immediately after treatment and after three days and also cell migration to the area treated using 8 pigs as experimental models, as well as cellular changes by transmission electron microscopy (TEM). **Results:** The Wilcoxon test was conducted, and a difference was found between the treated side and the corresponding control side on the number of viable cells. The treated side showed a smaller number of viable cells compared to the control side both immediately after treatment and 3 days later. Also occurring 3 days after treatment was the migration of lymphoid cells and fibroblasts, which shows the local inflammatory process and conjunctive neoformation. Soon after treatment there was fluid accumulation within adipocytes. **Conclusions:** The results shown in this paper demonstrate Ultrasonic Hydrolipoclasys as a viable alternative for the treatment of localized fat deposits without the side effects of traditional surgical procedures. Better results are expected when hypotonic solution is used, since it penetrates into the cell.

KEYWORDS: Adipose tissue, alternative technique, ultrasound

INTRODUCTION

Ultrasonic hydrolipoclasys (HLC) was officially proposed in 1990 in Italy during the national congress of the International Society of Aesthetic Medicine and in 1991 at the World Congress of Aesthetic Medicine in Rio de Janeiro by Italian physician Ceccarelli. This technique consists of applying a hypotonic solution directly into the fatty tissue and then subjecting the tissue to the application of 3 MHz ultrasound. This makes the already swollen adipocytes become more susceptible to the action of ultrasonic waves; and, due to the phenomenon of

cavitation, “explode,” releasing fat from within. These will be removed from the site via the lymphatic system.^[1,2]

Doctors worldwide have been using HLC successfully, but the experiments are still restricted to few centers, such as those in Rome, Italy, by Ceccarelli. The research conducted on the microstructural changes of adipose tissue using the HLC, however, are not always easy since there is a need to use animals as experimental models. Mice are not suitable models, because they are very small and would probably not withstand the effects of ultrasound. An animal that could be used as a model would be the pig, due to its size and morphofunctional similarities with the human species.

Due to the importance of esthetic medicine in the world, the frequent demand of alternatives for control of local adiposity and the scarcity of scientific studies with experimental models, this study aims to assess the morphological and microstructural changes of

Access this article online	
Quick Response Code:	Website: www.jcasonline.com
	DOI: 10.4103/0974-2077.85025

Fúlvio B Godoy, Belchiolina B Fonseca¹, Marcelo A Levenhagen¹, Mariane A Franco¹, Roberta T Melo¹,

Marcelo E Beletti¹

Medicine Department of University Presidente Antonio Carlos – UNIPAC, ¹Histology Laboratory and Electronic Microscopy Center of Biomedical Sciences Institute of Uberlândia Federal University - ICBIM-UFU.

Address for correspondence:

Dr. Belchiolina B Fonseca, Biomedical Sciences Institute, Av. Pará, 1720, Campus Umuarama, CEP 38400-902, Uberlândia-MG, Brazil. E-mail: bialucas@yahoo.com.br

adipocytes caused by using ultrasonic hydrolipoclasia upon Landrace pigs, which have thin adipose tissue, to better understand the effectiveness of this technique in humans.

MATERIALS AND METHODS

Eight 90-day-old female Landrace pigs, weighing 75 kg on average with about 2 cm of adipose tissue in the abdominal region were used. The animals were raised on a farm located in the industrial region of the Triângulo Mineiro, Brazil, where the HLC and the removal of tissue were performed.

For containment, procedure, and sample collection, animals were anesthetized with tiletamine associated to Zoletil intramuscularly. After restraint, a midline abdominal division was drawn (corresponding topographically to the ventral midline) and, using a tape measure, points were predefined and scored for completion of hydrolipoclasia and collection of tissues to be analyzed. The left side was predetermined as the test side and the contralateral (right) as the control side. On the test side, after cleansing with iodine alcohol, 120 ml of hypotonic solution (distilled water) was injected with a 30 G 1/2 hypodermic needle and the area was subsequently treated with ultrasound in continuous mode in the protocol for hydrolipoclasia, with 3 MHz ultrasound, at a power of 1.9 Watts/cm² for 30 mins. After this period, with the same equipment used in hydrolipoclasia, lymphatic drainage was performed with ultrasound in pulsed mode at 50% power (1 Watt/cm²) for 10 mins.

On the control side no substance was injected nor any treatment performed with the device. Soon after the procedure (zero hour) and after 3 days skin fragments from the skin to the first layer of abdominal muscle were removed from both sides measuring approximately 2.5 cm³. Each fragment was divided into two, with one of the shares fixed in 10% formaldehyde in 0.1 M phosphate buffer, pH 7.2, to perform optical microscopy and the other part fixed in 3% glutaraldehyde in phosphate buffer at 0.1 M, pH 7.2, for transmission electron microscopy (TEM). The material was sent to the Laboratory of Histology and Electron Microscopy Center, Federal University of Uberlândia, for processing the material.

Optical microscopy

After 48 h of storage, samples were cut into smaller segments and washed in water, then dehydrated in increasing alcohol series to 50%, 70%, 85%, 90%, 95%, and 100% being 30 min at each concentration, washed in xylene (100%) and embedded in histological paraffin. Histological specimens 5–7 µm thick were stained with

hematoxylin–eosin and mounted in Canada balsam.

The number of fat cells intact for µm² was evaluated at zero hours and 3 days after treatment. To do this, digital images were captured on an Olympus BX40 binocular microscope with a 10× objective coupled to an Olympus OLY-200 camera that was connected to a PC via a Data Translation 3153 digitizer board. The images were evaluated using HL Image software. The counting was done in the first layer of fatty tissue underlying the skin and the result was an average of 8 different fields for each sample.

In addition to analyzing adipose cells three days after treatment, a count of cell nuclei by µm² to check cell migration to repair tissue (lymphoid cells, fibroblasts, and adipocytes) was performed. The counting was automated using the same microscope and program described above, the result being the average of 8 different fields for each sample.

Electron microscopy

The fragments for TEM were cut into cubes of about one cubic millimeter and placed in a 1:1 solution of osmium tetroxide and 0.1 M phosphate buffer, pH 7.2, for 1 h and subsequently treated with potassium ferrocyanide (1.25%) for 30 mins. The fragments were dehydrated in increasing series of acetone. Subsequently, the material was placed in a 2:1 solution of Epon resin and propylene oxide for 12 h. After this period, the solution containing the material was placed in an oven at 37°C for 4 h and then the solution of resin and propylene oxide was replaced by a solution of pure resin in which the material was soaked for 4 h more. Finally, the cubes were embedded in Epon resin to be cut by ultramicrotome to obtain ultrathin cuts.^[3]

The ultrathin sections were stained with uranyl acetate and subsequently with lead for 30 mins at room temperature.^[3] The assessment and photographic documentation were made on an electron microscope (Zeiss Electron Microscope EM 109) and captured by MEGAVIEW^{G2} OLYMPUS SOFT IMAGE SOLUTION (Zeiss).

Ethics

We used the method of stunning indicated for swine and the method of euthanasia indicated by the law Conselho Federal de Medicina Veterinária, Brazil, number 714 from June 20, 2002.

Statistics

The statistical design was randomized using the nonparametric Wilcoxon test^[4] with a significance level of $P = 0.05$. Analyses of variables were performed using the statistical program S-Plus 2000 (MathSoft, Inc.).

RESULTS

In light microscopy there was a difference between the amount of viable cells per field both immediately after the procedure and after 3 days of completion of HLC between test and control groups, whereas the test group showed a smaller number of cells per 100,000 μm^2 ($P < 0.05$). Figure 1 shows pictures with the differences between test and control groups at zero hour; Figure 2, the difference 3 days after the procedure of HLC. Table 1 shows the number of cells per 100,000 μm^2 .

The test group had a higher number of migration cells per 10,000 μm^2 in the control group 3 days after treatment. The last line of table 1 shows the number of cells per 10,000 μm^2 . Figure 3 shows that there was migration of lymphocytic cells and connective tissue formation, indicating a healing process.

Another important finding in light microscopy is that the first animal, due to differences in skin thickness and consistency of human and pig tissues, suffered a puncture accident in infiltration with subsequent muscle necrosis and hemorrhage [Figure 4], showing the importance of the procedure to be performed by a physician knowledgeable in human anatomy.

TEM showed that fluid had accumulated within the adipocytes of the test group immediately after the procedure at both superficial and deep levels [Figures 5a-c]. These accumulations were not found in the control group at any time, nor in the test group after 3 days of the experiment. Furthermore, the presence of vesicles in some micropinocitose adipocytes was shown [Figure 6].

DISCUSSION

The differences between the number of viable cells

presented between test and control groups in OM [Figures 1 and 2, Table 1] shows that hydrolypoclasia is an effective procedure for local adiposity. For over 30 years, ultrasound has been widely used by medical professionals.^[5] The frequencies of the transducers play an important role in the treatment. Ultrasound with a frequency of 1 MHz is absorbed by tissues at depths between 3 and 5 cm. Longer treatments with a frequency of 3 MHz can promote therapeutic effects at depths between 1 and 3 cm.^[6-8]

Knowledge and proper use of ultrasound is essential to achieve the best result of the technique, so the physician should be responsible for stating power, frequency and length of use of ultrasound in each case. This is necessary because low doses of ultrasound do not have the capacity to promote dissolution in fat cells. In general, the frequency of the transducer used in cosmetic procedures is equal to 3 MHz and intensity may reach 3 w/cm². It is noteworthy that all the above procedures are classics in esthetic medicine.^[9,10]

The accumulation of water seen in TEM for the test group but not found in the control group shows that the use of a hypotonic solution would likely improve the application of the technique, since it

Table 1: Average number of intact fat cells per 10,000 μm^2 of adipose tissue on zero hour and 3 days after the procedure of hydrolypoclasia (HLC) and number of cells per field 3 days after the procedure of HLC per 100,000 μm^2 of adipose tissue

	Control	Test	P value
CI zero	14.15 ^a	2.28 ^b	0.0074
CI 3 days	13.22 ^c	2.60 ^d	0.0021
MI	2.63 ^e	6.32 ^f	0.001

a, b: Different letters in the same row indicates significant difference ($P \leq 0.05$). CI, intact cells per 100,000 μm^2 ; MI, cell migration (lymphoid cells, fibroblasts, and adipocytes) per 10,000 μm^2 .




Figure 1: (a) Pig fat tissue of the control side at zero hour (bar = 200 μm); (b) Pig fat tissue of test side after treatment with hydrolypoclasia (HLC) at zero hour (bar = 200 μm)

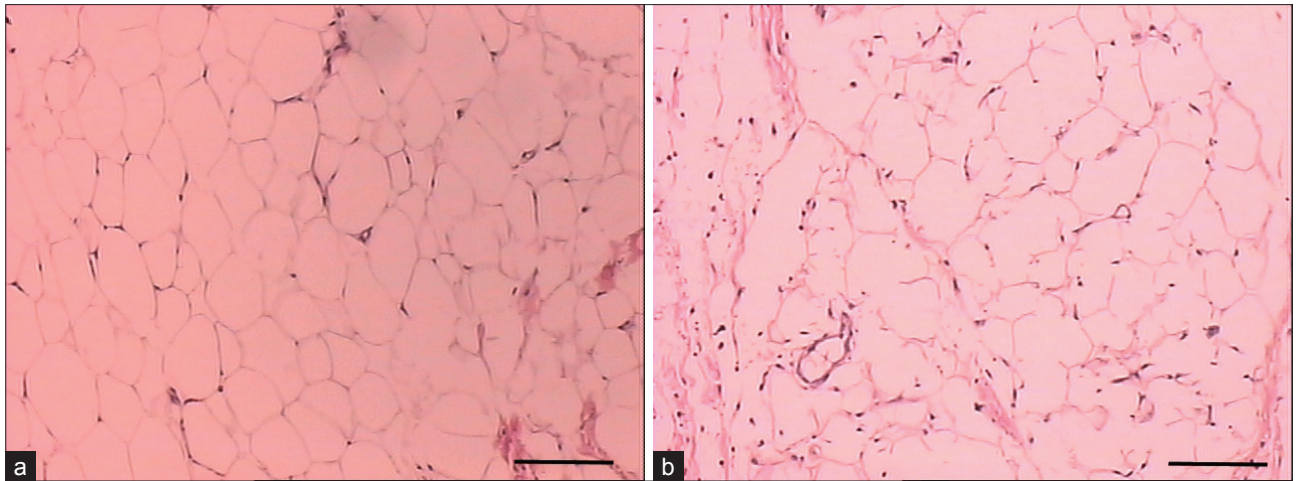


Figure 2: (a) Pig fat tissue of the control side 3 days after treatment with HLP (bar = 200 μ m); (b) Pig fat tissue of test side 3 days after treatment with HLP (bar = 200 μ m)

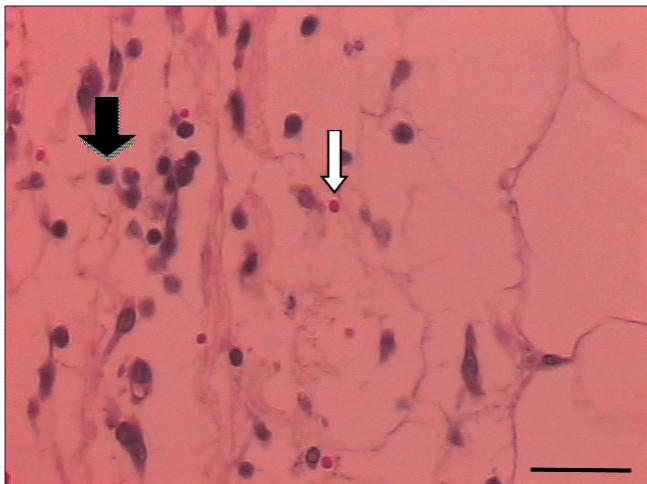


Figure 3: Cell migration in adipose tissue of pigs 3 days after treatment with HLP with a predominance of lymphocytes (black arrow). Red blood cells are also visible (white arrow) (bar = 50 μ m)

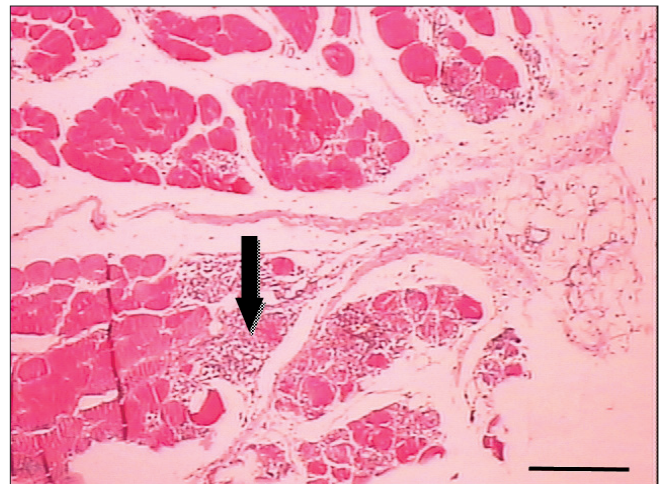


Figure 4: Areas of muscle necrosis 3 days after treatment with HLP, indicated by arrow, are caused by accidental puncture due to injection of the hypotonic solution into the skeletal muscle underlying the fatty tissue of a pig (bar = 500 μ m)

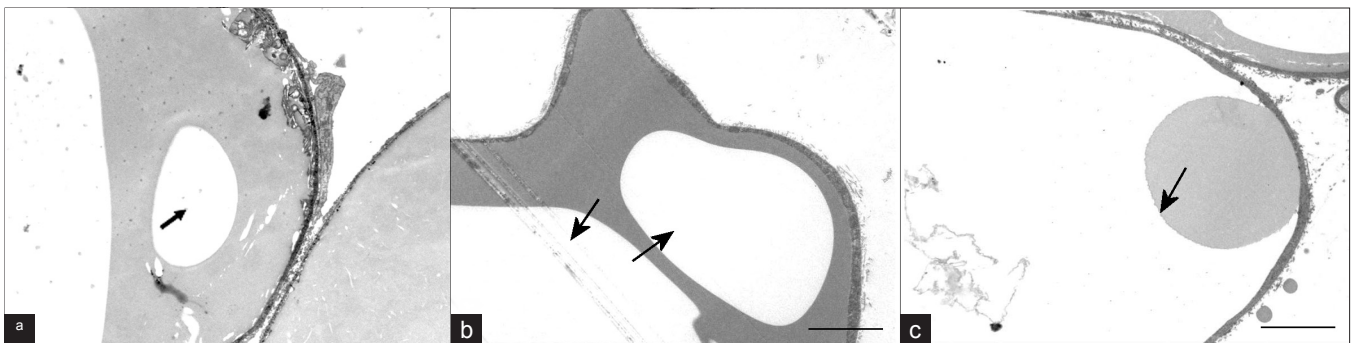


Figure 5: Areas of fluid accumulation within adipocytes immediately after the hydrolipoclasia procedure; (a) superficial portion (near the skin); (b) medium; and (c) deep portion (near the muscle)

penetrates further into the cell and could cause greater intracellular cavitation. Figure 6 shows that, in some cells in the test group, micropinocytose vesicles are formed, indicating that some cells still maintain their normal function. Thus, despite being an efficient and

noninvasive technique, the field of action is restricted to contact with the solution and application of the device.

In the published literature there are no studies that



Figure 6: Formation of microvesicles of pinocytosis in adipocyte membrane

include the changes in adipose tissue after treatment with HLC, but the effect of HLC on the lysis of adipocytes found in this study can be explained by Cecarelli's^[11] hypothesis which states that the effect of classical cavitation is amplified by the infiltration of hypotonic solution before application of ultrasound.

The hypotonic solution (distilled water) has a double effect: the adipocytic lysis by osmotic effect and an increase in the damage done by cavitation (cavitation of the water, the formation of microbubbles, which rupture, and explosion of these surrounding the biological material). The fine and delicate tissues (fat cells) are more easily damaged than the tough and resistant structures (connective tissue and bones). Note that the application of ultrasound to biological material soaked in water determines the damage not by cavitation of the biological material, but by the explosion of microbubbles produced by the cavitation of water present.^[11]

Figure 3 shows that there was migration of lymphocytic cells and connective tissue formation, indicating a healing process. This is because there is release of vasoactive kinins by intracellular lysosomal rupture, causing a localized mild inflammatory reaction. Tissue damage of any kind (physical, chemical, or biological) triggers an immediate series of signaling events initiated by chemical structures that are made by ruptured cells (portions of the cell membrane and organelles), fragments of inert elements of tissues (collagen, elastin, fibronectin, and others), and the action performed by inflammatory mediators (granules released mainly from platelets, mast cells, and peripheral nerve endings) or neosynthesized (eicosanoids and platelet activating factors).^[12] Continuance of the process occurs in the injured tissue with infiltration of circulating cells and the migration of cells from adjacent areas, such as

fibroblasts. The latter, in cooperation with the local cells that were previously activated, will be the protagonists of fibroplasia and depositors of extracellular matrix, angiogenesis, and wound healing in the region.^[13]

Most lymphoid cells found 3 days postprocedure were lymphocytes with few neutrophils and macrophages. The low number of neutrophils is probably due to excellent asepsis of the area, which highlights the importance of the procedure being performed by a trained medical professional.

Because this tissue injury is closed and the microorganisms are not present, the lymphocytes are the most abundant leukocyte subsystem in this site.^[14] Lymphocytes are not only immune effectors, but also producers of growth factors,^[15] responsible for the rebuilding of regional cellularity or restoring their homeostasis by tissue neoformation.

Another important finding is that in the first animal, due to differences in skin thickness and consistency of human and pig tissues, there was a puncture accident in infiltration, with subsequent muscle necrosis and hemorrhage [Figure 4], once again highlighting the need for specific medical knowledge to perform the procedure.

Regarding the volume of solution to be injected in a session of hydrolyplasty, there is no risk, since 200–400 mL is usually injected, and on tumescent liposuction more than 2000 mL can be safely injected.^[16]

CONCLUSION

HLC is effective both in producing lipolysis and in the reduction of fat mass adjacent to skin. Thus, such treatment is indicated for localized adiposity with the advantage of being minimally invasive and without significant side effects, provided it is performed by a physician who is a professional and who knows human anatomy and physiology in detail. The result depends on the number of treatment sessions (usually between 10 and 20 once-weekly sessions per treated area) that will also be directed by a doctor since TEM revealed some still-functional cells by TEM.

From the above we see that hydrolyplasty is a technique that, due to its safety, simplicity, and low cost, is a good option for treating localized fat deposits of small and medium volumes—especially for those patients who would not like to undergo any other type of surgical treatment under general or other types of anesthesia.

ACKNOWLEDGMENTS

This study was financed by the “Fundação de Amparo a Pesquisa de Minas Gerais” (FAPEMIG) (Minas Gerais

Research Support Foundation), CAPES (Coordenação de Aperfeiçoamento de Pessoal de Nível Superior), and “Conselho Nacional de Desenvolvimento Científico e Tecnológico” (CNPq) (Federal Brazilian Research Support Foundation).

REFERENCES

1. Ceccarelli M, Pignatelli V. Biochemical evaluation of the effects of classical ultrasonic hydrolipoclasia. *La Med Estét* 1993;17:1.
2. Ceccarelli M, Pignatelli V, Bartoletti CA. Ultrasonic hydrolipoclasia in the treatment of localized fat excess: A modification of the protocol and further evaluation. *La Med Estét* 1995;19:2.
3. Bozzola JJ, Russel LD. *Electron microscopy: Principles and techniques for biologists*. 2nd ed. Boston: Jones and Bartlett Publishers; 1998. p. 542.
4. Conover WJ. *Practical nonparametric statistics*. 3rd ed. New York: John Wiley; 1998. p. 584.
5. Lehmann JF, Krusen FH. Therapeutic application of ultrasound in physical medicine. *Am J Phys Med* 1958;37:173-83.
6. Van der Wint DA, Van Der Heijden GJ, Van Der Berg SG, ter Riet G, de Winter AF, Bouter LM. Ultrasound therapy for musculoskeletal disorders: A systematic review. *Pain* 1999;81:257-71.
7. Spped CA. Therapeutic ultrasound in soft tissue lesions. *Rheumatology* 2002;40:1331-6.
8. Berná-Serna JD, Sánchez-Garre JJ, Madriga M, Zuazu I, Béna-Mestre JD. Ultrasound therapy in rectus sheath hematoma. *Phys Ther* 2005;85:352-7.
9. Kinney BM. Body contouring with external ultrasound. Plastic Surgery Educational Foundation DATA Committee. Device and Technique Assessment. *Plast Reconstr Surg* 1999;103:728-9.
10. Rosenberg GJ, Cabrera RC. External ultrasonic lipoplasty: An effective method of fat removal and skin shrinkage. *Plast Reconstr Surg* 2000;105:785-91.
11. Ceccarelli M, Colantonio A, Santarelli Marino AR, Chimenti S. The nuclear magnetic resonance in the control of the treatment of lipomas with ultrasonic hydrolipoclasia. *La Med Estét* 1993;17:1.
12. Contran RS, Kumar V, Collins T, Robbins T. Structural and functional pathology. Rio de Janeiro, BR: Guanabara Koogan; 2001. p. 44-100.
13. Singer AJ, Clark RA. Cutaneous wound healing. *N Engl J Med* 1999;341:738-46.
14. Engelhard E, Toksoy A, Goobeler M, Debus S, Brücker EB, Gillitzer R. Chemokines IL-8, Groa, MCP-1, IP-10, and Mig are sequentially and differentially expressed during phasespecific infiltration of leucocyte subsets in human wound healing. *Am J Pathol* 1998;153:1849-60.
15. Blotnik S, Peoples GE, Freeman MR, Eberlein TJ, Klagsbrun M. T Lymphocytes synthesize and export heparin-binding epidermal growth factor-like growth factor and basic fibroblast growth factor, mitogens for vascular cells and fibroblast: Differential production and release by CD4+ and CD8+ T cells. *Proc Natl Acad Sci U S A* 1994;91:2890-4.
16. Martinez MA, Okajima RM, Proto RS, Lourenço LM, Machado Filho CD. Study of 543 patients subjected to tumescent liposuction. *Surg Cosmet Dermatol* 2010;2:155-8.

How to cite this article: Godoy FB, Fonseca BB, Levenhagen MA, Franco MA, Melo RT, Beletti ME. Structural changes of fat tissue after nonaspirative ultrasonic hydrolipoclasia. *J Cutan Aesthet Surg* 2011;4:105-10.

Source of Support: Nil. **Conflict of Interest:** None declared.

Author Help: Online submission of the manuscripts

Articles can be submitted online from <http://www.journalonweb.com>. For online submission, the articles should be prepared in two files (first page file and article file). Images should be submitted separately.

1) **First Page File:**

Prepare the title page, covering letter, acknowledgement etc. using a word processor program. All information related to your identity should be included here. Use text/rtf/doc/pdf files. Do not zip the files.

2) **Article File:**

The main text of the article, beginning with the Abstract to References (including tables) should be in this file. Do not include any information (such as acknowledgement, your names in page headers etc.) in this file. Use text/rtf/doc/pdf files. Do not zip the files. Limit the file size to 1 MB. Do not incorporate images in the file. If file size is large, graphs can be submitted separately as images, without their being incorporated in the article file. This will reduce the size of the file.

3) **Images:**

Submit good quality color images. Each image should be less than 4 MB in size. The size of the image can be reduced by decreasing the actual height and width of the images (keep up to about 6 inches and up to about 1200 pixels) or by reducing the quality of image. JPEG is the most suitable file format. The image quality should be good enough to judge the scientific value of the image. For the purpose of printing, always retain a good quality, high resolution image. This high resolution image should be sent to the editorial office at the time of sending a revised article.

4) **Legends:**

Legends for the figures/images should be included at the end of the article file.