

Lip Repositioning, Aesthetic Crown Lengthening, and Gingival Depigmentation: A Combined Approach for a Gummy Smile Makeover

Rishi A. Bhimani, Nabila D. Sofia¹

Periodontist, Dr. Rishi's Dental Clinic, Navi Mumbai, Maharashtra, India, ¹Head Dentist, Health Care Centre, Mumbai, Maharashtra, India

Abstract

This clinical report describes the successful use of aesthetic crown lengthening, lip-repositioning technique as well as gingival depigmentation for the reduction of excessive gingival display and dark gums, respectively. Lip-repositioning technique was performed with the main objective of reducing gummy smile by limiting the retraction of elevator muscles (e.g., zygomaticus minor, levator anguli oris, orbicularis oris, and levator labii superioris) during smiling, thereby restricting the upper lip from shifting apically while smiling. This technique includes removing a strip of mucosa from the maxillary labial and buccal vestibule, creating a partial-thickness flap between mucogingival junction and upper lip musculature, and suturing the lip mucosa with mucogingival junction, resulting in a narrow vestibule and restricted muscle pull, thereby reducing gingival display. The results obtained with lip repositioning for the treatment of gummy smile are substantial and it is a simple and effective procedure, well accepted by patients. Proper case selection is important for using this procedure.

Keywords: Excessive gingival display, gingival depigmentation, gummy smile, lip repositioning, periodontal plastic surgery

BACKGROUND

Smile is an important determinant of the facial attractiveness of an individual. A perfect smile is an immaculate harmony between the pink gums and the white teeth. A normal smile has 1–2 mm of gingival display from the inferior border of upper lip to the gingival margin of upper central incisors. Greater than 4 mm of gingival display is aesthetically not pleasing for most patients and is known as excessive gingival display (EGD) leading to a gummy smile (GS).^[1] The prevalence of EGD ranges from 10.5% to 29% worldwide, more common in women than men.^[2] EGD has a multifactorial etiology including altered passive eruption, enlarged gingiva, and vertical maxillary excess, short, or hypermobile upper lip. Its management varies according to the etiology and degree of gingival display during smile. Lip training exercises, gingivectomy, aesthetic crown lengthening, lip repositioning, and orthognathic surgery are performed to address the condition.^[3]

A disturbance in the color of the gingiva gets highlighted in an individual with GS. A normal healthy gingiva appears coral pink,^[4] but physiologic variations may produce pigmented patches. Gingival depigmentation is a procedure performed to eliminate the pigmented superficial gingival epithelium.

This report describes a smile makeover performed by lip repositioning and other minor cosmetic periodontal surgeries for the correction of EGD.

CASE PRESENTATION

A 23-year-old man reported to Health Care Center, Mumbai, Maharashtra, India, with a chief complaint of excessive gum display as well as dark gums while smiling.

Address for correspondence: Dr. Rishi Bhimani,
Dr. Rishi's Dental Clinic, Shop 9 and 10, Sai Palace, Plot 36,
Sector 14, Vashi, Navi Mumbai 400703, Maharashtra, India.
E-mail: rishibhimani@gmail.com

This is an open access journal, and articles are distributed under the terms of the Creative Commons Attribution-NonCommercial-ShareAlike 4.0 License, which allows others to remix, tweak, and build upon the work non-commercially, as long as appropriate credit is given and the new creations are licensed under the identical terms.

For reprints contact: reprints@medknow.com

How to cite this article: Bhimani RA, Sofia ND. Lip repositioning, aesthetic crown lengthening, and gingival depigmentation: A combined approach for a gummy smile makeover. *J Cutan Aesthet Surg* 2019;12:240-3.

Access this article online

Quick Response Code:



Website:
www.jcasonline.com

DOI:
10.4103/JCAS.JCAS_25_19

On clinical examination, he had gingival display of approximately 8mm with a high smile line and a wide smile extending from maxillary right first molar (16) to maxillary left first molar (26) with dark brown pigmented patches on attached gingiva, whereas the marginal and interdental gingiva were pale pink [Figure 1]. His wheatish complexion did not coincide with the intensity of gingival pigmentation. All the anterior teeth were small [Figure 2]. The patient's upper lip significantly drifted apically exposing excessive amount of gingiva while smiling. He had no adverse habits as well as a noncontributory medical history. Therefore, the following treatment plan was selected to correct the smile problems:

- Crown lengthening from upper right first premolar (14) to upper left first premolar (24) to correct the teeth size.
- Lip-repositioning surgery to restrict the hypermobility of upper lip while smiling.
- Gingival depigmentation using electrocautery to eliminate the pigmented patches.

All the three surgical techniques were performed together.

CASE MANAGEMENT

A written informed consent was obtained before the procedure. Standard aseptic protocols and skin preparation was carried out. Local infiltration was performed using local anesthetic solution Lignox (2% lignocaine with 1:200,000 adrenaline, Indoco Remedies Ltd., Mumbai, India) in the vestibular mucosa and lip extending from right first molar to left first molar.

Crown lengthening was carried out initially from 14–24 by gingivectomy technique (without osseous recontouring as probing depth was 4–5mm) with a 15C Bard-Parker blade (Kehr Surgical Pvt. Ltd., Kanpur, India). After crown lengthening, the gingival display while smiling was reduced to approximately 6mm [Figure 3].

Dotted incision lines were outlined using an indelible pencil. A partial-thickness incision was made following the mucogingival junction extending from right second premolar (15) to left second premolar (25). Followed by the first incision, another second horizontal incision parallel to first was made in the labial mucosa 10–12mm apical to mucogingival junction joining the previous incision in elliptical pattern [Figure 4]. The partial-thickness flap was excised [Figure 5] leaving the underlying connective tissue exposed [Figure 6].

Complete hemostasis was achieved by pressure pack. The incised margins were approximated with an interrupted stabilization suture using Vicryl 4-0 at the midline. Before complete suturing, the pigmented gingival mucosa was peeled off using a radio frequency electrocautery (Alis India Pvt. Ltd., Mumbai) [Figure 7]. Multiple interrupted simple loop sutures were placed at nearly equal distances [Figure 8].

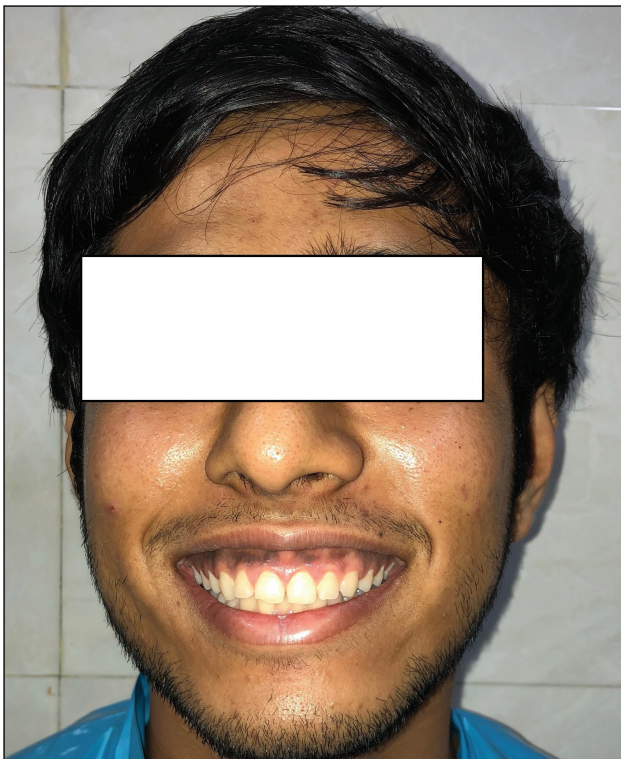

Figure 1: Pretreatment smile showing EGD and pigmented gingiva

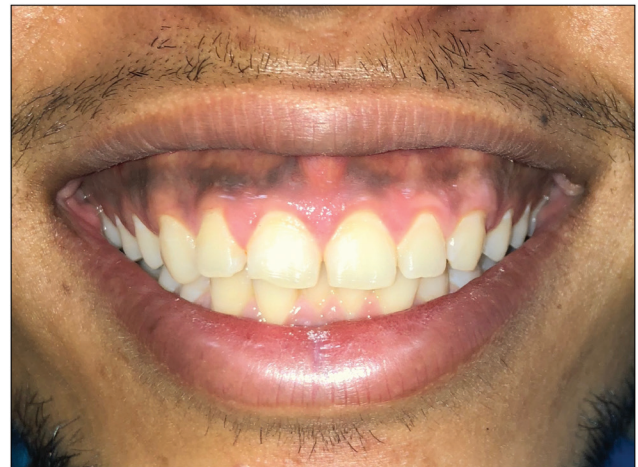

Figure 2: Pretreatment: smile showing small teeth and a high smile line and a wide smile extending to first molars on either sides

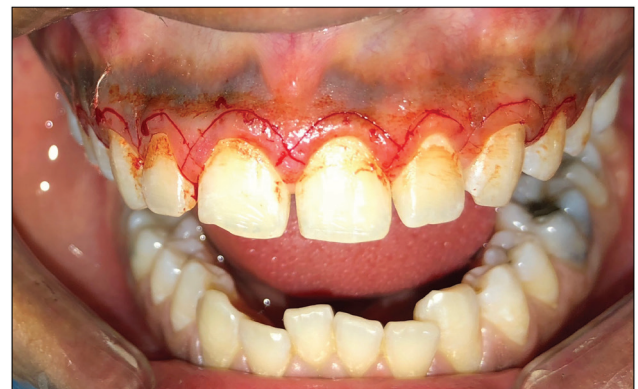

Figure 3: Incision of crown lengthening marked

Analgesic (tablet Aceclofenac, 100 mg BD) was prescribed for three days along with antibiotics (tablet Augmentin, 625mg BD) for five days postoperatively. The patient was instructed to apply immediately intermittent ice pack postoperatively for few hours over the upper lip and to minimize lip movement while smiling and talking.

CLINICAL OUTCOME

Postoperative symptoms included mild swelling with feeling of tension on the upper lip while smiling.

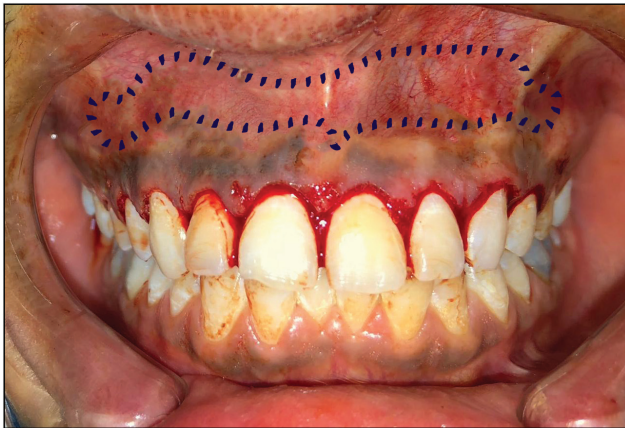


Figure 4: Dotted incision lines marked, inferior line along the mucogingival junction and superior line 10–12mm away from the inferior line meeting in an elliptical pattern on either sides

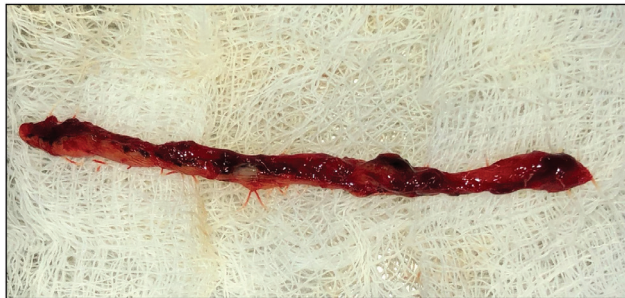

Figure 5: Band of partial thickness tissue excised between the incision lines

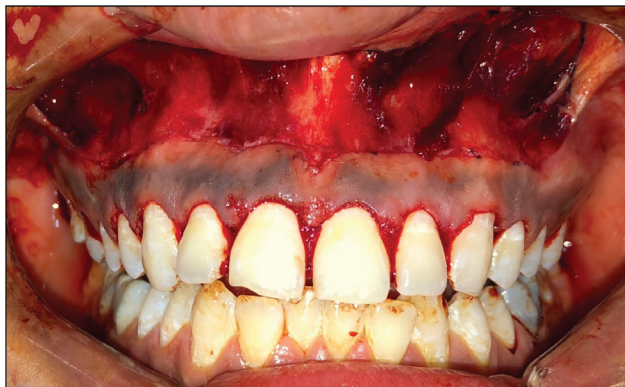


Figure 6: Exposed connective tissue after excision of the superficial partial thickness flap

Sutures were removed after two weeks. The site healed uneventfully with scar formation at the suture line, which was concealed under the lip and was not apparent while smiling [Figure 9]. The patient was recalled every three months for follow-up [Figure 10]. He was pleased and satisfied with the aesthetic outcome.

DISCUSSION

When a person smiles, the crowns of maxillary central incisors and 1 mm of pink attached gingiva are evident. Approximately 2–3mm of exposed gingiva can be cosmetically acceptable if it is not unduly conspicuous. In this case, after one month of healing, there was 2 mm

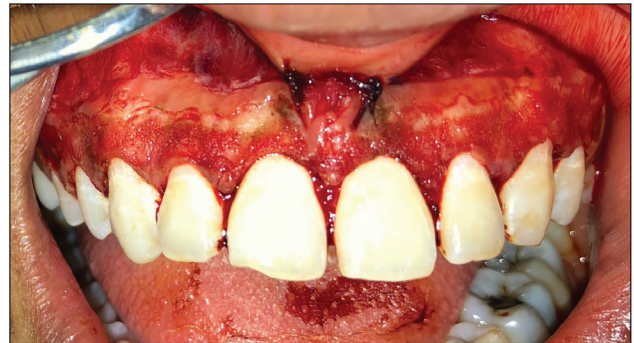

Figure 7: Midline suture placed repositioning the lip midline with depigmentation of pigmented patches with electrocautery

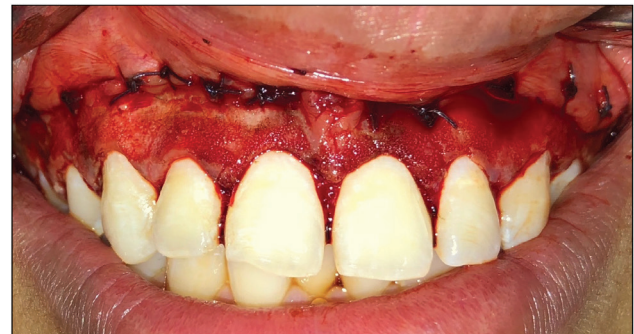

Figure 8: Equidistant sutures placed

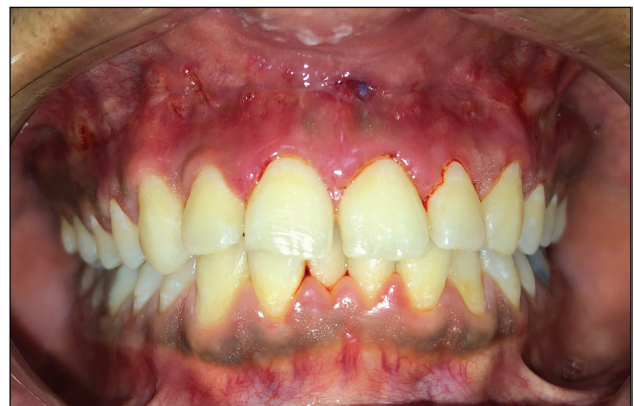

Figure 9: Posttreatment: two weeks healing by scarring

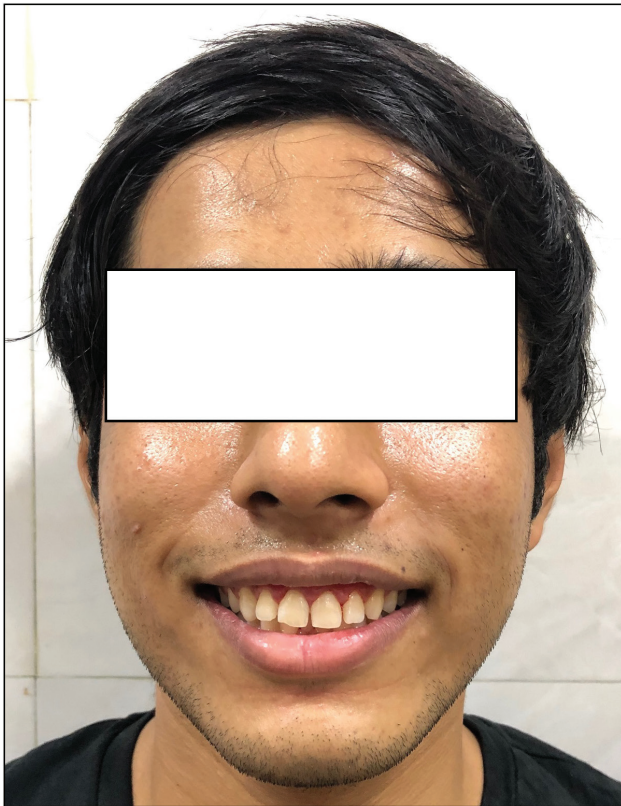

Figure 10: Posttreatment: final result at three months showing significant reduction of gingival display and an optimal 1–2 mm of gingival display during smiling

of pink healthy gingival display, which was a significant change for the patient.

In most patients, the lower edge of the upper lip assumes a “gum-wing” profile, which limits the amount of gingiva that is exposed when a person smiles. Patients with high lip line expose a broad zone of gingiva, resulting in GS.^[5]

The objective of lip repositioning is surgical correction of unaesthetic GS by limiting the retraction of the elevator smile muscles (zygomaticus minor, levator anguli oris, orbicularis oris, and levator labii superioris), resulting in a narrow vestibule and restricted muscle pull, thereby reducing gingival display during smiling.^[6] As the patient had hypermobile upper lip, it created an ideal situation for this case. Lip repositioning was first described in the literature of plastic surgery in 1973 by Rubinstein and Kostianovsky,^[7] advocated later by Litton and Fournier^[8] for correction of EGD for short upper lip. This procedure has been a plastic surgical procedure rather than a dental. A plastic surgeons’ perspective of a smile comprises the lips and facial musculature, whereas a dental surgeon incorporates the teeth and gums as well as the other facial anatomical features because a smile is incomplete without an ideal balance between the white teeth and pink gums.

This case is unique as it amalgamates a plastic surgery technique (lip repositioning) with two different dental procedures (crown lengthening surgery and gingival depigmentation) to correct a GS, short teeth, and dark pigmented gums, all together.

Advantage of lip-repositioning technique over other treatments for GS correction is that it is simple, safe, and effective with stable and satisfactory treatment results after healing. Individuals who have EGD due to excessive maxillary prominence are not ideal candidates for lip repositioning. Hence, the establishment of a proper diagnosis before selection of this technique is mandatory.

CONCLUSION

Surgical lip repositioning is an effective and promising alternative procedure in the field of periodontal plastic surgery for the correction of GS by restricting the lip movement.

Declaration of patient consent

The authors certify that they have obtained all appropriate patient consent forms. In the form the patient(s) has/have given his/her/their consent for his/her/their images and other clinical information to be reported in the journal. The patients understand that their names and initials will not be published and due efforts will be made to conceal their identity, but anonymity cannot be guaranteed.

Financial support and sponsorship

Nil.

Conflicts of interest

There are no conflicts of interest.

REFERENCES

- Sheth T, Shah S, Shah M, Shah E. Lip reposition surgery: a new call in periodontics. *Contemp Clin Dent* 2013;4:378-81.
- Kokich V, Kiyak HA, Shapiro P. Comparing the perception of dentists and lay people to altered dental esthetics. *J Esthet Dent* 1999;11:311-24.
- Bhola M, Fairbairn PJ, Kolhatkar S, Chu SJ, Morris T, de Campos M. Lipstat: the lip stabilization technique—indications and guidelines for case selection and classification of excessive gingival display. *Int J Periodontics Restorative Dent* 2015;35:549-59.
- Fiorellini JP, Kim DM, Ishikawa SO. The gingiva. In: Newman MG, Takei H, Carranza FA, and Klokkevold PA, editors. *Carranza’s Clinical Periodontology*. St. Louis, MO: 2006. pp. 46-67.
- Sharma A, Sharma S, Garg H, Singhal V, Mishra P. Lip repositioning: A boon in smile enhancement. *J Cutan Aesthet Surg* 2017;10:219-22.
- Rosenblatt A, Simon Z. Lip repositioning for reduction of excessive gingival display: a clinical report. *Int J Periodontics Restorative Dent* 2006;26:433-7.
- Rubinstein AM, Kostianovsky AS. Cirugiaestetica de la malformacion de la sonrisa. *Pren Med Argent* 1973;60:952.
- Litton C, Fournier P. Simple surgical correction of the gummy smile. *Plast Reconstr Surg* 1979;63:372-3.