

Radio-frequency Ablation for Matricectomy in the Management of Ingrown Toenail: A Pilot Study

Archana Singal, Ishmeet Kaur

Department of Dermatology and STD, University College of Medical Sciences and Guru Teg Bahadur Hospital, University of Delhi, Delhi, India

Abstract

Introduction: Ingrown toenail is one of the most commonly encountered nail disorders that adversely affect the quality of life. The common surgical intervention includes partial nail avulsion with chemical matricectomy but it has a relatively longer recovery period. We attempted to study the efficacy and safety of radio frequency (RF) for matricectomy. **Materials and Methods:** Eight patients with total 10 ingrown toenails (grade 2) were recruited. Partial nail avulsion with RF ablation of matrix was performed. The radio-frequency electrode was placed over the lateral matrix horn for the duration of 3–5s, two to three times. Patients were followed up at regular interval. Outcome was measured in terms of ooze, erythema, pain, and swelling of the lateral nail folds. **Results:** Of the eight patients, six were males and two were females. Total 10 nails were treated as two patients had bilateral toenail involvement. Average number of days required for postprocedural healing was 7.5 days. Significant improvement was observed in terms of erythema, pain as well as swelling within 4 days of surgery. None of the cases showed any adverse effects or relapse within 3–5 months of follow-up. **Conclusion:** Matricectomy by radio-frequency ablation is a safe and effective method in the management of ingrown toenail with significant reduction in downtime.

Keywords: Ablation, ingrown nail, matricectomy, partial nail avulsion, radio frequency

INTRODUCTION

Ingrown nail, also known as onychocryptosis, is a common nail disorder of the big toes, characterized by pain, swelling, and discharge. It carries a significant negative impact on the quality of life.^[1,2] Majority of grade 1 cases can be managed conservatively that includes anti-inflammatory drugs with or without antibiotics, packing, taping, and nail braces. However, significant proportion of patients with grade 2 severity, especially with recurrent episodes and those with grades 3 and 4 require surgical measures.^[3] One of the most common surgical interventions is partial nail avulsion with chemical matricectomy with 88% phenol. In this pilot study, we have attempted to study the efficacy and safety of partial nail avulsion followed by matricectomy with radio-frequency (RF) ablation in grade 2 ingrown toenails in Indian population.

MATERIALS AND METHODS

Patient selection

Eight patients with grade 2 ingrown toenail were recruited for the study after excluding contraindications such as

coagulation disorders, diabetes mellitus, or a history of pacemaker insertion. Prior consent was obtained and the patients were planned for partial nail avulsion with RF ablation of matrix.

Surgical technique

1. The concerned digit was cleaned with povidone-iodine.
2. Proximal digital block was administered with 1% lidocaine, and finger tourniquet was applied to attain a clean bloodless field.
3. Partial nail avulsion was performed as per the standard protocol.^[1,2] On the affected side, the nail plate was separated from the nail bed in a controlled manner using nail elevator, starting from the edge.
4. A 2–4mm longitudinal strip of the nail plate was removed along with the lateral horn.

Address for correspondence: Dr. Archana Singal,
University College of Medical Sciences and Guru Teg Bahadur Hospital,
University of Delhi, Delhi 110095, India.
E-mail: archanasingal@hotmail.com

This is an open access journal, and articles are distributed under the terms of the Creative Commons Attribution-NonCommercial-ShareAlike 4.0 License, which allows others to remix, tweak, and build upon the work non-commercially, as long as appropriate credit is given and the new creations are licensed under the identical terms.

For reprints contact: reprints@medknow.com

How to cite this article: Singal A, Kaur I. Radio-frequency ablation for matricectomy in the management of ingrown toenail: A pilot study. *J Cutan Aesthet Surg* 2019;12:212-4.

Access this article online

Quick Response Code:



Website:
www.jcasonline.com

DOI:
10.4103/JCAS.JCAS_3_19

5. The lateral horn of the matrix was ablated by RF using a tungsten electrode that was flat and bent at an angle as shown in Figure 1. The electrode was placed for 3–5 s and it was repeated two to three times.
6. Tourniquet was released and a bulky dressing was carried out for the digit using liberal amount of antibiotic cream.
7. In addition to general precautions, the patients were prescribed pain killers and a course of broad-spectrum antibiotics.

Postprocedural care and assessment

Dressing was changed at day 2, 4, 7, and 15. The patients were followed up at 1 month and then every month for at least 3 months along with photographic assessment. Outcome at each visit was measured in terms of ooze, erythema, pain and swelling, or tissue damage.

Pain was perceived by the patient on a visual analog scale (VAS) of 0–10 (0 being no pain and 10 being unbearable pain). Drainage/ooze was graded as grade 0: no discharge, grade 1: minimal soakage of dressing with no visible discharge, grade 2: mild discharge on pressing the folds only, grade 3: discharge visible on the toe, and grade 4: excessive discharge.

RESULTS

Eight adult patients were recruited for the study with an involvement of total 10 nails. Of these, six were males and two were females and their age ranged from 18 to 42 years. Two patients had bilateral toenail involvement, whereas the rest showed unilateral involvement only. All patients had grade 2 ingrown nail, that is, the presence of inflammation, pain, and mild granulation tissue. They were treated with a conservative approach, which brought no relief to any of them. Patients were screened for diabetes and coagulation disorders. History of pacemaker

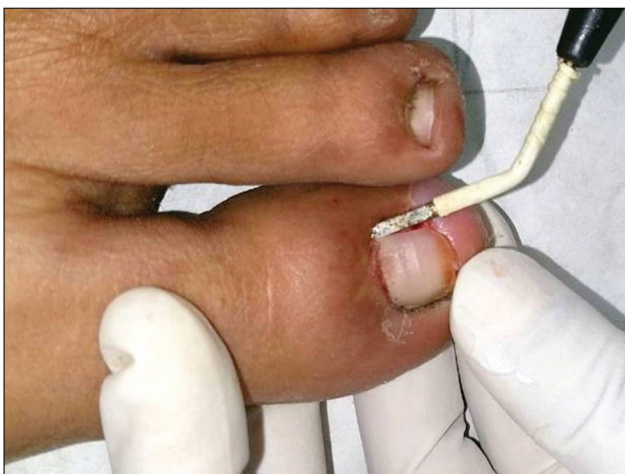


Figure 1: Radio-frequency ablation for partial matricectomy using a tungsten electrode flat and bent at an angle

insertion was taken as this is an absolute contraindication for RF procedures.

On follow-up, the average number of days required for postprocedural healing was 7.5 days (range, 5–8 days) as shown in Figures 2 and 3. Significant improvement was observed in terms of erythema, pain as well as swelling within 5 days of surgery. Postoperative ooze was minimal on day 2 (grade 1 in eight and grade 2 in two nails) and absent (grade 0) on second visit, that is, by day 4 in all the patients (100%). Postoperative pain was minimal. Mean VAS score for pain on day 0, 2, and 4 was 4.5, 2, and 0, respectively. All the patients were pain free by the second visit (day 4).

Complications such as prolonged ooze/discharge or secondary infection were encountered in none of the cases. All the patients were ambulatory by day 2. No recurrence was noticed in any of them in 3–6 months.

DISCUSSION

Ingrown nail can be a very painful condition and can negatively affect the daily activities of the patient. Management can be conservative or surgical, which depends on the grade of the disease.^[1,2] It has been classified into four grades according to Mozena classification. Grade 1 requires conservative approach. Grade 2 often requires partial matricectomy, whereas for grade 3 and 4, treatment is always surgical intervention, namely partial nail plate avulsion with matricectomy or wedge resection.^[3]

Matricectomy can be performed by either chemical or mechanical destruction. Chemical matricectomy is usually performed with the help of phenol (88%), trichloroacetic acid (100%), and sodium hydroxide (10%).^[4] Though

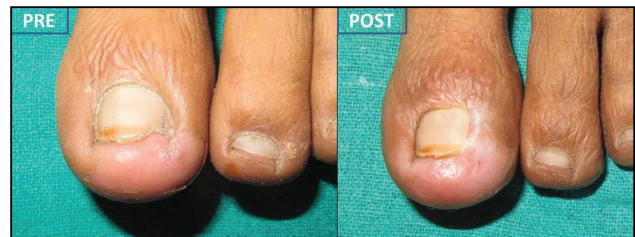

Figure 2: Pre- and postoperative (day14) clinical picture showing quick healing and grade 0 drainage

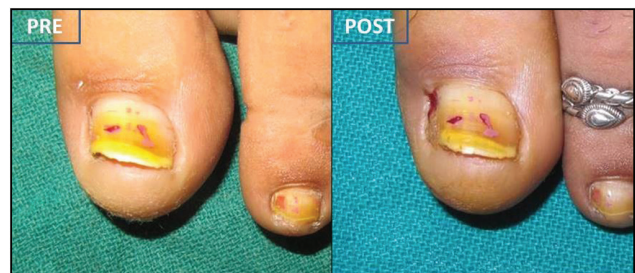

Figure 3: Pre- and postoperative (day14) clinical picture showing grade 0 drainage and fast tissue recovery

chemical matricectomy is a simple and inexpensive technique, healing time is relatively longer. In addition, there can be unpredictable collateral tissue damage. There is also prolonged drainage resulting from epidermal slough caused by the chemical burn and the possible infection.^[4-6] In a study comparing the efficacy of 88% phenol and 10% sodium hydroxide, median duration of postoperative pain was reported to be 16.25 and 7.92 days, respectively. The postoperative discharge continued for a median period of 18.13 and 15.42 days and the healing time was 15.63 and 7.50 days, respectively.^[7] On the contrary, our study showed a shorter duration of both postoperative pain and swelling (5 days) and postoperative healing (7.5 days). In addition, postoperative ooze was markedly less in our patients (minimal/absent by day 4).

Matricectomy by surgical excision has a low recurrence rate, but it can be tedious and a lengthy procedure. It is also associated with higher postoperative pain and prolonged drainage. Mechanical matricectomy can also be performed with the help of carbon dioxide (CO₂) laser, and cryotherapy has been reported to offer more effective and selective destruction of the nail matrix than chemical matricectomy but it is very expensive and requires technical expertise. High cost of laser, prolonged healing time, and poor cosmetic outcome limit the use of this technique.^[4,5,8,9]

RF ablation of the matrix horn is a faster, less painful option that causes selective tissue damage. There is less lateral heat spread and tissue damage with better control. Recurrence rate is lower and healing is faster with this technique. This poor man's laser has shown to be more effective and versatile in comparison to the CO₂ laser.^[4,10]

In our study, all 10 nails treated with partial nail avulsion with matricectomy by radio-frequency ablation showed faster healing within a week time. There was a significant reduction in ooze, pain, and swelling. Adverse effects such as postoperative pain and drainage and secondary infections were nil. Recurrence was not observed in any of the patients after 3–5 months follow-up. Thus, RF ablation may be considered as a relatively inexpensive, safe, and effective alternative for nail matricectomy for the treatment of ingrown toenail.

CONCLUSION

Matricectomy by radio-frequency ablation is a safe and effective method of partial matricectomy with lower complications and recurrence rate. It can therefore be used as an alternative method in surgical management of ingrown nail.

Declaration of patient consent

The authors certify that they have obtained all appropriate patient consent forms. In the form the patient(s) has/have given his/her/their consent for his/her/their images and other clinical information to be reported in the journal. The patients understand that their names and initials will not be published and due efforts will be made to conceal their identity, but anonymity cannot be guaranteed.

Financial support and sponsorship

Nil.

Conflicts of interest

There are no conflicts of interest.

REFERENCES

1. Zuber TJ, Pfenninger JL. Management of ingrown toenails. *Am Fam Physician* 1995;52:181-90.
2. Haneke E. Controversies in the treatment of ingrown nails. *Dermatol Res Pract* 2012;2012:783-924.
3. Martinez-Nova A, Sanchez-Rodriguez R, Alonso-Pena D. A new onychocryptosis classification and treatment plan. *J Am Podiatr Med Assoc* 2007;97:389-93.
4. Khunger N, Kandhari R. Ingrown toenails. *Indian J Dermatol Venereol Leprol* 2012;78:279-89.
5. Baran R, Haneke E. Matricectomy and nail ablation. *Hand Clin* 2002;18:693-6.
6. Karaca N, Dereli T. Treatment of ingrown toenail with proximolateral matrix partial excision and matrix phenolization. *Ann Fam Med* 2012;10:556-9.
7. Grover C, Khurana A, Bhattacharya SN, Sharma A. Controlled trial comparing the efficacy of 88% phenol versus 10% sodium hydroxide for chemical matricectomy in the management of ingrown toenail. *Indian J Dermatol Venereol Leprol* 2015;81:472-7.
8. Ozawa T, Nose K, Harada T, Muraoka M, Ishii M. Partial matricectomy with a CO₂ laser for ingrown toenail after nail matrix staining. *Dermatol Surg* 2005;31:302-5.
9. Sonnex TS, Dawber RP. Treatment of ingrowing toenails with liquid nitrogen spray cryotherapy. *Br Med J (Clin Res Ed)* 1985;291:173-5.
10. Sachdeva S, Dogra A. Radiofrequency ablation in dermatology. *Indian J Dermatol* 2007;52:134-7.