

# Safety and Efficacy of Intralesional Vitamin D3 in Cutaneous Warts: An Open Uncontrolled Trial

Manjunath Kavya, Basavapura Madegowda Shashikumar, Muddanahalli Rajegowda Harish, Bhadbhade P Shweta

Department of Skin and STD, Mandya Institute of Medical Sciences, Mandya, Karnataka, India

## Abstract

**Background:** Cutaneous warts are treated primarily with destructive methods such as cryotherapy or electrocautery. These modalities of treatment are time-consuming and may be associated with scarring in multiple warts. Immunotherapy is emerging as a new modality of treatment which acts on enhancing cell-mediated immunity against human papillomavirus for clearance of both treated and distant warts. **Aims:** This study aims to evaluate the safety and efficacy of intralesional Vitamin D3 for the treatment of cutaneous warts. **Materials and Methods:** Patients with multiple warts were selected for immunotherapy. Vitamin D3 (0.2 ml, 15 mg/ml) was injected to the base of warts after injecting with lignocaine (0.2 ml, 20 mg/ml). The injections were repeated 2 weeks apart for a maximum of 4 sessions or until complete clearance, whichever was earlier. A maximum of 2 warts were treated per session and patients were followed up for 6 months after the last injection. **Results:** Forty-two patients with multiple warts were recruited for the study who completed the 6-month follow-up period and were available for analysis. Of these, 23 had palmoplantar warts, 18 had verruca vulgaris and 1 patient had filiform wart. In total, 33 of 42 patients (78.57%) showed complete response, 6 patients (14.28%) showed moderate response and three patients (7.14%) showed mild response. Recurrence was observed in one patient with the palmoplantar wart. No serious adverse effects were reported. **Limitations:** Lack of control group was the main drawback in our study. **Conclusion:** Intralesional Vitamin D3 is safe and effective for treatment of multiple cutaneous warts.

**Keywords:** Cutaneous warts, intralesional treatment, Vitamin D3

## INTRODUCTION

Warts or verrucae are benign epidermal proliferations of the skin and mucosa caused by human papillomavirus (HPV). Although spontaneous resolution occurs within 2 years in 65%–78% of warts, most patients seek treatment of warts as they are cosmetically disfiguring and sometimes painful, especially on the soles.<sup>[1]</sup> Local destruction of warts is a commonly employed treatment modality performed by using either topical keratolytics, electrocoagulation, cryotherapy or laser therapy.<sup>[2-5]</sup> All these modalities of treatment can be painful and may be associated with scarring and frequent recurrences. In addition, destructive modalities are not suitable for the treatment of multiple and refractory warts as they clear only treated lesions and not the distant ones. Hence, to overcome these shortcomings, immunotherapy is being tried widely for the treatment of warts over the last few years. It acts on the basic principle of enhancing the cell-mediated immunity for the clearance of warts.<sup>[6]</sup> Various antigens have been tried including measles, mumps, rubella (MMR); tuberculin purified

protein derivative (PPD); *Mycobacterium w* vaccine and *Candida* antigen.<sup>[7-10]</sup>

Few studies have been published showing the efficacy of topical Vitamin D3 derivatives in the treatment of warts.<sup>[11,12]</sup> However, intralesional Vitamin D3 injection was tried first time by Aktas *et al.* for the treatment of plantar warts and reported encouraging results.<sup>[13]</sup> Herein, we report the treatment response of intralesional Vitamin D3 injections for the treatment of cutaneous warts.

## MATERIALS AND METHODS

The study was conducted from August 2015 to November 2016 in the Department of Dermatology and Venereology of

**Address for correspondence:** Dr. Manjunath Kavya,  
Department of Skin and STD, Mandya Institute of Medical Sciences,  
Mandya - 571 401, Karnataka, India.  
E-mail: kavyam216@gmail.com

### Access this article online

Quick Response Code:



Website:  
www.jcasonline.com

DOI:  
10.4103/JCAS.JCAS\_82\_16

This is an open access article distributed under the terms of the Creative Commons Attribution-NonCommercial-ShareAlike 3.0 License, which allows others to remix, tweak, and build upon the work non-commercially, as long as the author is credited and the new creations are licensed under the identical terms.

**For reprints contact:** reprints@medknow.com

**How to cite this article:** Kavya M, Shashikumar BM, Harish MR, Shweta BP. Safety and efficacy of intralesional vitamin D3 in cutaneous warts: An open uncontrolled trial. *J Cutan Aesthet Surg* 2017;10:90-4.

our institute. The study was approved by the institute Ethical Committee. A total of 42 patients were enrolled in the study and were available for analysis.

### Study design

All consecutive patients, both male and female, having cutaneous warts (with no prior treatment with either topical or destructive modalities for at least 6 months prior) were primarily selected for the study. Patients <12 and >70 years, pregnant and lactating females, any evidence of immunosuppression including HIV and with a prior history of hypersensitivity to Vitamin D3 were excluded from the study.

Cutaneous warts were diagnosed by history and clinical features. Baseline evaluation was made at the first visit, and the demographic data were recorded in a structured questionnaire designed for this study. A graphical wart map was prepared for each patient; location, number, size and type of wart were recorded on it at each visit. Photographs were taken at each visit to support the recorded data.

Clinical response was documented by recording the decrease in number and size of warty lesions at each visit i.e., at 2 weekly intervals for 4 sessions and 6 months after the last injection. Complete clearance was considered if all the warts both treated and distant warts resolved completely. Moderate response if there were 50 to <100% reductions in both size and number of lesions, mild response was considered if response was between 1% and <50%.<sup>[14]</sup>

Larger warts were considered for the injection. A maximum of 2 warts were treated at each session.

The injections were repeated at 2 weekly intervals for a maximum of four injections. If complete clearance was achieved before four injections, the treatment was stopped, and patient was followed up for recurrence. Patients were evaluated for treatment efficacy and adverse reactions every 2 weeks for first 2 months and monthly thereafter to record for any recurrence for 6 months.

### Method of administration of Vitamin D3 injection

Vitamin D3 for injection is available in vials containing 6,00,000 IU of cholecalciferol in 1 ml (15 mg). The selected warts were injected first with 0.2 ml of lignocaine (20 mg/ml); after few minutes, 0.2 ml of Vitamin D3 (15 mg/ml) was slowly injected into the base of each wart with a 27-gauge insulin syringe. Post-treatment, the patients were advised not to use any topical and oral medications.

## RESULTS

A total of 42 patients received Vitamin D3 injections. The demographic and clinical data of 42 patients are shown in Table 1.

The study included 27 males and 15 females. Age of the patients ranged from 12 to 66 years, with a mean of 20 years. The duration of warts ranged from 1 month to 96 months, with a mean of 6 months. The number of warts ranged from

2 to <30. Twenty-three patients had palmoplantar warts, one patient had filiform wart over face and 18 patients had verruca vulgaris. Multiple non-contiguous sites were involved in 16 patients (38.09%).

The mean number of intralesional injections required for complete clearance which was seen in 33 patients was 3.

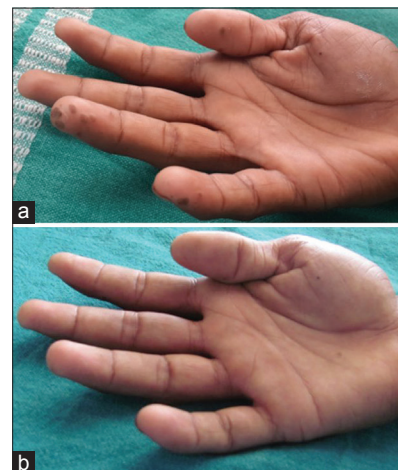
Complete clearance was seen in 19 (82.60%) out of 23 patients with palmoplantar warts and 14 (77.77%) of 18 patients with verruca vulgaris. Representative patients showing complete response are depicted in [Figures 1-4]. Six patients (14.28%) i.e., three each in palmoplantar and verruca vulgaris group showed moderate response. One each in all subtypes of warts showed improvement which ranged from 1 to <50%. The response rate of various types of warts is shown in Table 2.

Adverse effects were seen in 34 (80%) patients, but all were minor with no life-threatening complications. Swelling at the site of injection was the most common adverse effect seen in 33 (78.57%) patients which resolved without any treatment in 4 weeks [Figure 5]. Dyspigmentation was seen in one patient [Figure 6].

Recurrence was observed in one patient with palmoplantar wart during 6-month follow-up period.

**Table 1: Summary of the demographic and clinical data**

Total patients	42
Gender ratio (male:female)	1.8:1
Mean age in years (range)	20±9.69 (12-66)
Mean duration of disease in months (range)	6±20.08 (1-96)
Mean number of warts (range)	4.5±6.97 (2-30)
Type (%)	
Verruca vulgaris	18 (42.85)
Filiform wart	1 (2.38)
Palmoplantar wart	23 (54.76)
>1 non-contiguous site involved	16 (38.09)



**Figure 1:** (a) Multiple palmar warts before treatment. (b) Complete clearance after three injections

**DISCUSSION**

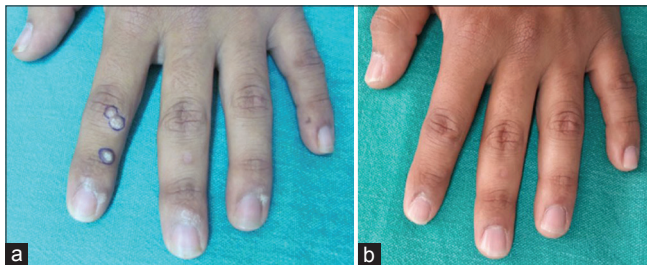
Treatment of multiple warts especially palmoplantar warts is difficult and it needs multiple sittings by destructive methods such as cryotherapy and electrocautery. These destructive procedures are usually associated with scarring and pigmentation. In addition, some warts are resistant to these treatments and recurrence rate is also high. Hence, immunotherapy is the best available option in treating warts as it boosts the immune system to HPV virus leading to clearance of both treated and untreated warts. Recurrence rate is also low when compared to destructive methods.<sup>[1-4]</sup> Immunotherapy has been tried with various antigens and vaccines such as bleomycin, PPD, MMR, *Candida albicans* and *Mycobacterium w* vaccine.<sup>[9,10,15-18]</sup> In this present study, we used intralesional Vitamin D3 which was a relatively new treatment option for warts. Several studies have been published showing the efficacy of topical Vitamin D for the treatment of warts. Refractory wart in a 41-year-old renal transplant patient was treated successfully with calcitriol solution by Moscarelli *et al.*<sup>[19]</sup> Rind *et al.*<sup>[11]</sup> reported complete clearance of anogenital wart in an infant by calcipotriene ointment. In both case reports, the effect of Vitamin D3 derivatives on warts was speculated to be derived from its potential to regulate epidermal cell proliferation

and differentiation and to modulate cytokine production. Recently, it was observed that there is toll-like receptor activation of human macrophages which upregulated the expression of Vitamin D receptor (VDR) and Vitamin D-1-hydroxylase genes, leading to induction of the antimicrobial peptide.<sup>[20]</sup>

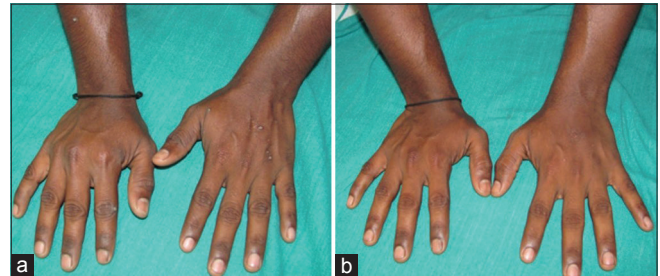
Aktas *et al.* used intralesional Vitamin D3 for plantar warts. Twenty patients were included in the study, and 7.5 mg of Vitamin D3 injection was given at monthly intervals for a maximum of 2 sessions. They reported complete clearance in 80% of patients at the end of 8 weeks.<sup>[13]</sup> The results were similar with our study as shown in Table 3.

The exact mechanism of action of Vitamin D in the clearance of warts is not known. Experimental evidence suggests that it has immunomodulatory effects by inhibiting the expression of interleukin-6 (IL-6), IL-8, tumour necrosis factor (TNF)- $\alpha$  and TNF- $\gamma$  mediated through VDR-dependent pathway.<sup>[21]</sup>

Various other antigens/vaccines used for immunotherapy and their response rate are shown in Table 4. The response rate achieved in our study was 78.57% in maximum of 4 sessions which was superior to the results achieved with PPD, Bleomycin, MMR vaccine, *C. albicans* antigen and *Mycobacterium indicus pranii* vaccine. However, treatment



**Figure 2:** (a) Verruca vulgaris before treatment. (b) Complete clearance after two injections



**Figure 3:** (a) Verruca vulgaris before treatment. (b) Complete clearance after two injections

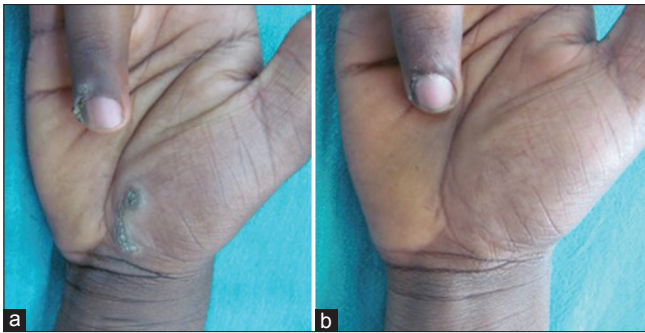
**Table 2: Treatment response according to type of wart**

	Palmoplantar wart (n=23)	Verruca vulgaris (n=18)	Filiform wart (n=1)	Total (n=42) (%)
Complete clearance	19	14	0	33 (78.57)
Moderate response (50%-<100%)	3	3	0	6 (14.28)
Mild response (1%-<50%)	1	1	1	3 (7.14)
Total (%)	23 (54.76)	18 (42.85)	1 (2.38)	42

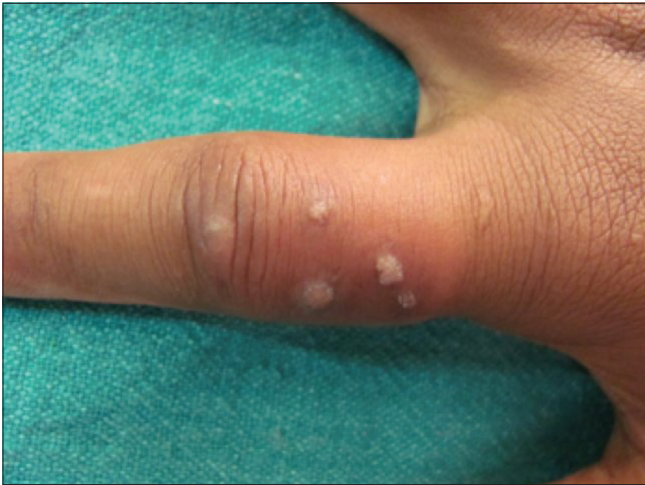**Table 3: Comparison with select study with intralesional Vitamin D3**

Study	Number of patients	Type of wart	Treatment	Interval between sessions	Maximum number of sessions	Adverse effects	Results (%)
Aktas <i>et al.</i> 2014	20	Plantar warts	Vitamin D3 + lignocaine	4	2	Pain during prilocaine injection	CR: 80 R: 0
Present study 2016	42	Common and palmoplantar warts	Vitamin D3 + lignocaine	2	4	Swelling at injection site Pigmentary change	CR: 78.57 R: 2.38

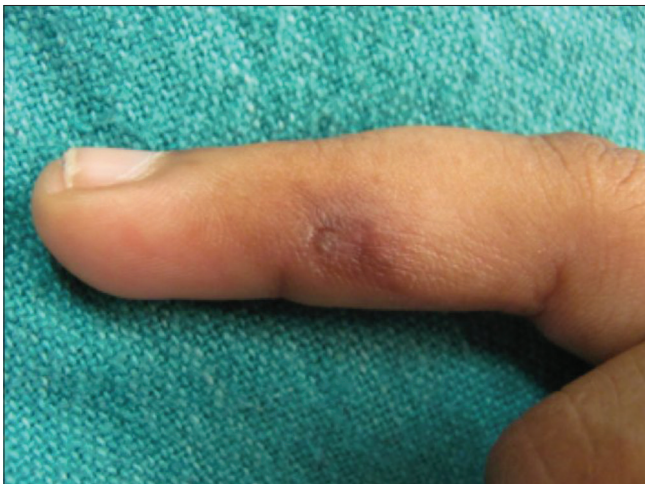CR: Complete response, R: Recurrence



**Figure 4:** (a) Palmar and periungual wart before treatment. (b) Complete clearance after four injections



**Figure 5:** Swelling at the injection site



**Figure 6:** Pigmentation after clearance

with *Mycobacterium w* vaccine was superior to that of Vitamin D3, but the number of sessions was more i.e., 10 as compared to our study which was 4. Hence, higher response rate i.e., 93% reported in the Garg and Baveja study<sup>[9]</sup> can be attributed to more number of sessions. Furthermore, they reported systemic and local complications such as high-grade fever and redness, swelling, induration and ulcer formation at the

**Table 4: Response rate of various antigens/vaccine**

Study	Antigen/vaccine	Number of sessions given	Clearance rate (%)
Garg and Baveja <sup>[9]</sup>	<i>Mycobacterium w</i> vaccine	10	93
Saoji et al. <sup>[15]</sup>	PPD	4	76
Lee et al. <sup>[16]</sup>	Bleomycin	6	73
Nofal et al. <sup>[17]</sup>	MMR vaccine	5	63
Majid et al. <sup>[10]</sup>	<i>Candida albicans</i>	3	56
Singh et al. <sup>[18]</sup>	<i>Mycobacterium indicus pranii</i> vaccine	10	54
Present study	Vitamin D3	4	78.57

PPD: Purified protein derivative, MMR: Measles, mumps and rubella vaccine

injection site. Hence, compared to these adverse effects, we did not experience any serious systemic and local complications which needed medications hence it is very safe procedure than *Mycobacterium w* vaccine.

## CONCLUSION

Intralesional Vitamin D3 injection is an innovative approach for the treatment of warts. It is inexpensive, safe and special value to treat multiple warts in developing countries. Although our study is limited by its small sample size and lack of randomisation, the results are encouraging. Well-designed, large randomised placebo-controlled studies are required in future to confirm the efficacy of intralesional Vitamin D3 injection for the treatment of multiple warts in clinical practice.

## Financial support and sponsorship

Nil.

## Conflicts of interest

There are no conflicts of interest.

## REFERENCES

1. Sterling JC, Handfield-Jones S, Hudson PM; British Association of Dermatologists. Guidelines for the management of cutaneous warts. *Br J Dermatol* 2001;144:4-11.
2. Gibbs S, Harvey I, Sterling J, Stark R. Local treatments for cutaneous warts: Systematic review. *BMJ* 2002;325:461.
3. Savant SS, Gore D. Electrosurgery. In: Savant SS, Shah RA, Gore D, editors. *Textbook and Atlas of Dermatotomy and Cosmetology*. Mumbai: ASCAD; 2005. p. 305-14.
4. Bourke JF, Berth-Jones J, Hutchinson PE. Cryotherapy of common viral warts at intervals of 1, 2 and 3 weeks. *Br J Dermatol* 1995;132:433-6.
5. Tan OT, Hurwitz RM, Stafford TJ. Pulsed dye laser treatment of recalcitrant verrucae: A preliminary report. *Lasers Surg Med* 1993;13:127-37.
6. Gonçalves MA, Donadi EA. Immune cellular response to HPV: Current concepts. *Braz J Infect Dis* 2004;8:1-9.
7. Nofal A, Nofal E. Intralesional immunotherapy of common warts: Successful treatment with mumps, measles and rubella vaccine. *J Eur Acad Dermatol Venereol* 2010;24:1166-70.
8. Shaheen MA, Salem SA, Fouad DA, El-Fatah AA. Intralesional tuberculin (PPD) versus measles, mumps, rubella (MMR) vaccine in treatment of multiple warts: A comparative clinical and immunological study. *Dermatol Ther* 2015;28:194-200.

9. Garg S, Baveja S. Intralesional immunotherapy for difficult to treat warts with *Mycobacterium w* vaccine. *J Cutan Aesthet Surg* 2014;7:203-8.
10. Majid I, Imran S. Immunotherapy with intralesional *Candida albicans* antigen in resistant or recurrent warts: A study. *Indian J Dermatol* 2013;58:360-5.
11. Rind T, Oiso N, Kawada A. Successful treatment of anogenital wart with a topical Vitamin D(3) Derivative in an infant. *Case Rep Dermatol* 2010;2:46-49.
12. Imagawa I, Suzuki H. Successful treatment of refractory warts with topical Vitamin D3 derivative (maxacalcitol, 1alpha, 25-dihydroxy-22-oxacalcitriol) in 17 patients. *J Dermatol* 2007;34:264-6.
13. Aktas H, Ergin C, Demir B, Ekiz Ö. Intralesional Vitamin D injection may be an effective treatment option for warts. *J Cutan Med Surg* 2016;20:118-22.
14. Gamil H, Elgharib I, Nofal A, Abd-Elaziz T. Intralesional immunotherapy of plantar warts: Report of a new antigen combination. *J Am Acad Dermatol* 2010;63:40-3.
15. Saoji V, Lade NR, Gadegone R, Bhat A. Immunotherapy using purified protein derivative in the treatment of warts: An open uncontrolled trial. *Indian J Dermatol Venereol Leprol* 2016;82:42-6.
16. Lee JY, Kim CW, Kim SS. Preliminary study of intralesional bleomycin injection for the treatment of genital warts. *Ann Dermatol* 2015;27:239-41.
17. Nofal A, Nofal E, Yosef A, Nofal H. Treatment of recalcitrant warts with intralesional measles, mumps, and rubella vaccine: A promising approach. *Int J Dermatol* 2015;54:667-71.
18. Singh S, Chouhan K, Gupta S. Intralesional immunotherapy with killed *Mycobacterium indicus pranii* vaccine for the treatment of extensive cutaneous warts. *Indian J Dermatol Venereol Leprol* 2014;80:509-14.
19. Moscarelli L, Annunziata F, Mjeshtri A, Paudice N, Tsalouchos A, Zanazzi M, *et al.* Successful treatment of refractory wart with a topical activated Vitamin D in a renal transplant recipient. *Case Rep Transplant* 2011;2011:368623.
20. Liu PT, Stenger S, Li H, Wenzel L, Tan BH, Krutzik SR, *et al.* Toll-like receptor triggering of a Vitamin D-mediated human antimicrobial response. *Science* 2006;311:1770-3.
21. AlGhamdi K, Kumar A, Moussa N. The role of Vitamin D in melanogenesis with an emphasis on vitiligo. *Indian J Dermatol Venereol Leprol* 2013;79:750-8.