

A Severe Case of Levamisole-Induced Vasculitis Requiring Extensive Surgery and Skin Grafts

Dear Editor,

A 48-year-old African-American female with a past medical history of hypertension, gastroesophageal reflux disease (GERD), and cocaine abuse presented to the emergency department with a 3-day history of a purpuric and reticular rash that began as a single patch on her gluteal region and progressed to encompass the majority of her buttocks, thighs, cheeks, and ear lobes. The patient admitted to cocaine insufflation several days before the rash ensued. Additionally, the patient denied any associated symptoms or any previous occurrence of the symptoms. She denied family history of autoimmune disease or vasculitides.

Vital signs on presentation were blood pressure (BP) of 172/78 mmHg, body temperature 36.3°C, respiratory rate (RR) 18 bpm, heart rate (HR) 113 bpm, O₂ Sat. 99% on room air. Physical examination demonstrated large, erythematous, reticular, nonblanching, and violaceous lesions covering her buttocks, with two open necrotic wounds, and several superficial bullae on thighs [Figure 1b]. Lesions were found bilaterally on the patient's face and earlobes [Figure 1a and c]. Her purpura progressed to full-thickness skin necrosis involving [Figures 2 and 3] ~20% of the total body surface area (TBSA). This presentation caused suspicion of a levamisole-induced vasculitis (LIV) from cocaine insufflation.

An initial basic metabolic profile showed a decreased glomerular filtration rate (GFR) of 59 mL/min and hyponatremia (129 mEq/L); all other values fell within a normal range. Urinalysis revealed proteinuria (~300 mg/dL) and ketonuria (15 mg/dL), 6-8 cast/hyaline per LPF and 3-6 red blood cells per high powered focus (HPF). The patient displayed a mixed nephrotic/nephritic disease profile. A urine drug screen was unable to detect any cocaine. C-reactive protein (CRP) and erythrocyte sedimentation rate (ESR) were markedly elevated (25.41 mg/dL and 122 mm/h, respectively). Her anti-dsDNA and rheumatoid factor were 3 unremarkable. Her perinuclear and cytoplasmic antinuclear cytoplasmic antibodies (p-ANCA and c-ANCA) titer screen fell within normal limits. An incisional biopsy of the right thigh and immunofluorescence were inconsistent with our patient's clinical presentation.

Wound care included intravenous methylprednisolone sodium succinate 60 mg q24h, wound washing with 500 U bacitracin PRN, silver sulfadiazine topical,

topical benzocaine 20%, morphine 4 mg IV every 4 hours PRN, acetaminophen, and 0.9% saline 50 mL IV every 8 h. Wound cultures of bilateral lower extremities yielded *Escherichia coli* and vancomycin-resistant *Enterococcus faecalis*, treated with intravenous antibiotics.

The patient was admitted to the burn intensive care unit. On day 29 of hospital admission, the buttocks and the lower extremities were debrided due to purulent and full-thickness necrosis of the lesions [Figure 3]. Negative pressure vacuum wound therapy was then placed on both lower extremities to enhance the healing process [Figure 4]. The patient had five more surgeries, which included five lower extremity and buttock debridement and four split-thickness skin grafts (STSG) before discharge.

The diagnosis of Levamisole-Induced Vasculitis (LIV) is a diagnosis of exclusion, and there are four criteria in addition to a positive history of cocaine use to consider this diagnosis as follows:

1. Cutaneous manifestations with palpable retiform purpura or bullae, particularly on ears, nose or thighs;^[1]
2. Arthralgia;
3. Leukopenia; and
4. High titers positive for ANCA.^[2,3]

A positive anti-hydroxynonenal (HNE) result points to cocaine use associated with LIV and has been used clinically as a diagnostic marker.^[1,3,4] Confirmation in this patient was not possible, as anti-HNE test was not available, and our report is limited by a negative urine toxicology screen.^[3]

Although there have been nearly 200 documented cases of LIV, only some have presented with extensive TBSA loss of 15% and 52%.^[1] Due to the restricted skin involvement and novelty of the condition, treatment, and management guidelines have yet to be implemented.^[5] Literature supports the early excision and grafting strategy for full-thickness dermal injury that contributes to a shorter hospital stay, lower costs for the patient, fewer complications from infections, and less cosmetic dissatisfaction.^[1,6] The current consensus for LIV includes cessation of levamisole with adjunctive steroid/immunosuppressive therapy (with limited evidence of effectiveness).^[6]

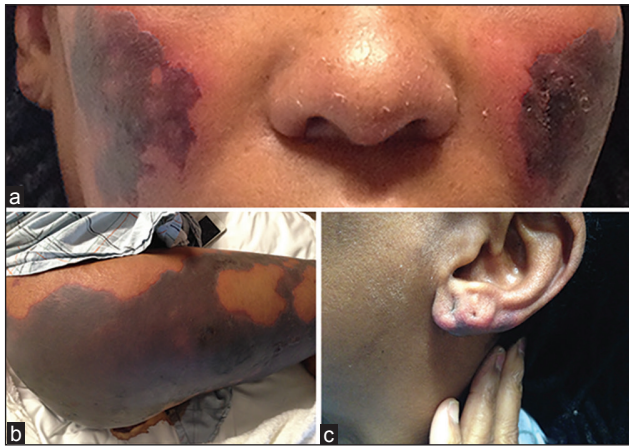


Figure 1: Negative pressure wound therapy (KCI Vacuum Assisted Closure®) seal of the lower extremities. The V.A.C. dressings were placed following the first tissue debridement procedure. (a) Levamisole-induced purpura: Bilateral erythema and necrosis of the cheeks. (b) Levamisole-induced purpura: Reticular, necrotic lesions with several bullae, the largest measuring 3 cm in diameter, of the right thigh and buttocks. (c) Levamisole-induced purpura: The pathognomonic lesion of levamisole-induced vasculitis of the ear lobe

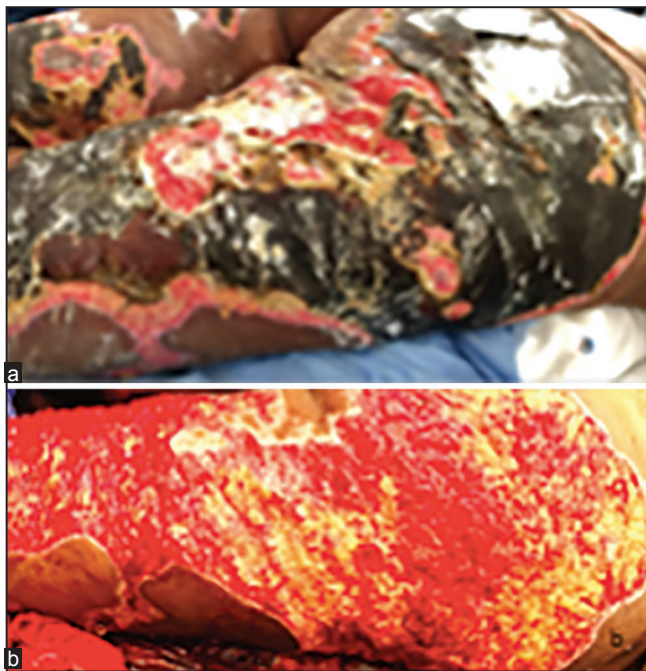

Figure 3: (a) Full-thickness excisional debridement of the posterolateral lower extremities. Day 29 of hospital admission, the patient underwent excisional debridement, prompted by the progression of her lesions to full-thickness necrosis and complicated by a superimposed bacterial infection, identified by purulent discharge from the wounds – pre-debridement. (b) full-thickness excisional debridement of the posterolateral lower extremities. Day 29 of hospital admission, the patient underwent excisional debridement, prompted by the progression of her lesions to full-thickness necrosis and complicated by a superimposed bacterial infection, identified by purulent discharge from the wounds – post-debridement

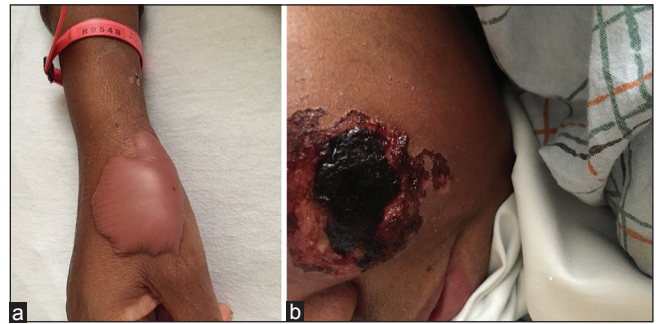


Figure 2: (a) Progression of LIV on day 8 of hospital admission: Demonstration of a superficial bullous lesion that measures 7.62 cm × 5.08 cm on the right dorsum of the hand. (b) Progression of LIV on day 8 of hospital admission. Full-thickness necrosis of the lesion previously illustrated, taken from the patient's cheek

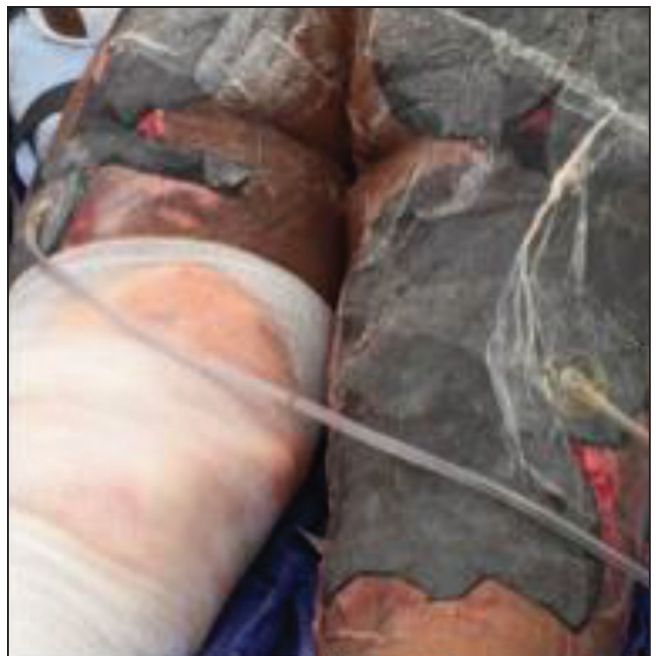

Figure 4: Negative pressure wound therapy (KCI Vacuum Assisted Closure®) seal of the lower extremities. The V.A.C. dressings were placed following the first tissue debridement procedure

Financial support and sponsorship

Nil.

Conflicts of interest

There are no conflicts of interest.

Kirill Alekseyev, Ida Micaily¹, Nirupama Parikh

Department of Internal Medicine, Staten Island University Hospital, Staten Island, New York, USA, ¹St. George's University School of Medicine, St. George, Grenada, West Indies

Address for correspondence: Dr. Kirill Alekseyev, Department of Internal Medicine, 475 Seaview Avenue, Staten Island, New York 10305, USA. E-mail: kirill.alekseyev@gmail.com

REFERENCES

1. Miner J, Gruber P, Perry TL. Early excision and grafting, an alternative approach to the surgical management of large body surface area levamisole-adulterated cocaine induced skin necrosis. *Burns* 2015;41:e34-40.
2. Gillis JA, Green P, Williams J. Levamisole-induced vasculopathy: Staging and management. *J Plast Reconstr Aesthet Surg* 2014;67:e29-31.
3. Álvarez Díaz H, Mariño Callejo AI, García Rodríguez JF, Rodríguez Pazos L, Gómez Buela I, Bermejo Barrera AM. ANCA-positive vasculitis induced by levamisole-adulterated cocaine and nephrotic syndrome: The kidney as an unusual target. *Am J Case Rep* 2013;14:557-61.
4. Rongioletti F, Ghio L, Ginevri F, Bleidl D, Rinaldi S, Edefonti A, *et al.* Purpura of the ears: A distinctive vasculopathy with circulating autoantibodies complicating long-term treatment with levamisole in children. *Br J Dermatol* 1999;140(5): 948-51.
5. Ching JA, Smith DJ Jr. Levamisole-induced necrosis of skin, soft tissue, and bone: Case report and review of literature. *J Burn Care Res* 2012;33:e1-5.
6. Vinita P, Khare NA, Chandramouli M, Nilesh S, Sumit B. Comparative analysis of early excision and grafting vs delayed grafting in burn patients in a developing country. *J Burn Care Res* 2014. [Epub ahead of print]

Access this article online

Quick Response Code:



Website:
www.jcasonline.com

DOI:
10.4103/0974-2077.178550

This is an open access article distributed under the terms of the Creative Commons Attribution-NonCommercial-ShareAlike 3.0 License, which allows others to remix, tweak, and build upon the work non-commercially, as long as the author is credited and the new creations are licensed under the identical terms.

For reprints contact: reprints@medknow.com

How to cite this article: Alekseyev K, Micaily I, Parikh N. A severe case of levamisole-induced vasculitis requiring extensive surgery and skin grafts. *J Cutan Aesthet Surg* 2016;9:41-3.