

# Use of Implanters in Premade Recipient Sites for Hair Transplantation

Arika Bansal, Pradeep Sethi, Abhinav Kumar, Alok K. Sahoo, Priyadarshini Das  
Department of Dermatology, Eugenix Hair Sciences, Gurugram, Haryana, India

## Abstract

**Background:** Techniques of hair transplantation are evolving with time both in terms of use of better methods of graft harvestment and implantation. The result of the procedure ultimately depends on the tenderness with which grafts are handled. **Aims:** The aim of this study was to evaluate efficacy and feasibility of using implanter in premade slits for implantation of the graft. **Materials and Methods:** This technique was used in 104 patients who were willing to undergo hair transplantation by follicular unit extraction. After administration of local anesthesia, the recipient sites were created. Thereafter, the processes of scoring the skin with a motorized punch, graft extraction, and implantation using implanter into the premade slits were performed simultaneously. These patients were followed up to look for the time period of initiation of hair growth. Improvement was assessed by comparing basic and specific classification (BASP) at the baseline and during subsequent follow-up. **Results:** Of 104 patients, 103 (99%) were men and one (1%) was woman. According to pretransplant BASP score, 98 (94.2%) patients were having severe type and 6 (5.8%) were having mild type. As per the posttransplant BASP score, patients having severe and mild type were 24 and 80, respectively. Improvement in the BASP score (from severe to mild type) was seen in 74 (71%) patients and no change was seen in 30 (29%) patients. Hair growth started becoming visible after two to five months and “good” results were obtained in all except two patients after a follow-up period varying from 8 to 18 months. **Conclusion:** Placement of the grafts into premade slits using implanter will help in improved results because of minimal graft handling, more graft placement in less time, and thereby reducing body out of time. **Limitation:** No objective assessment was carried out to document regrowth of hair in our study.

**Keywords:** Follicular unit extraction, hair transplantation, implanter, premade slits

## INTRODUCTION

A good hair transplant is evaluated by the naturalness of the end result in terms of hair growth, hairline, and density.<sup>[1]</sup> These parameters depend on the total number of grafts extracted, planted, and grown.<sup>[2]</sup> One of the main drawbacks of the follicular unit extraction (FUE) technique is that the grafts are “skinny” and can be easily damaged by handling during the process of transplantation.<sup>[3]</sup> The use of implanters has circumvented this problem by decreasing the handling of the graft to the minimum.<sup>[4]</sup>

We used a modification of the conventional implanter technique by creating premade slits in the recipient area.

## MATERIALS AND METHODS

Our modified FUE technique was performed in all the patients for hair transplantation.

The procedure can be divided into the following three steps:

1. Premade slits
2. Scoring, graft extraction, and graft placement
3. Graft placement

### Premade slits

Slits were made in a sagittal plane using a 20-G needle in the hairline zone, and the areas posterior to this were made using a 19-G needle. In total, 40–50 slits were made in each square centimeter [Figure 1].

**Address for correspondence:** Dr. Arika Bansal,  
Department of Dermatology, Eugenix Hair Sciences, 935 P,  
Sector 51, Opposite to Amity International School,  
Gurugram, Haryana-122018, India.  
E-mail: arika9ab@gmail.com

This is an open access journal, and articles are distributed under the terms of the Creative Commons Attribution-NonCommercial-ShareAlike 4.0 License, which allows others to remix, tweak, and build upon the work non-commercially, as long as appropriate credit is given and the new creations are licensed under the identical terms.

**For reprints contact:** reprints@medknow.com

**How to cite this article:** Bansal A, Sethi P, Kumar A, Sahoo AK, Das P. Use of implanters in premade recipient sites for hair transplantation. *J Cutan Aesthet Surg* 2019;12:250-4.

### Access this article online

#### Quick Response Code:



**Website:**  
www.jcasonline.com

**DOI:**  
10.4103/JCAS.JCAS\_33\_19

### Scoring, graft extraction, and graft placement

After the desired numbers of slits were made, the patient is made to lie to on the left lateral or right lateral position. Scoring was carried out by using sharp, Serrounded Cole punches of 0.85–0.95 mm, and simultaneous placements of the grafts were carried out using an implanter (SAVATM, Ahmedabad, India). Finally, the patient was shifted to the prone position for scoring and harvesting grafts from the occipital area [Figure 2].

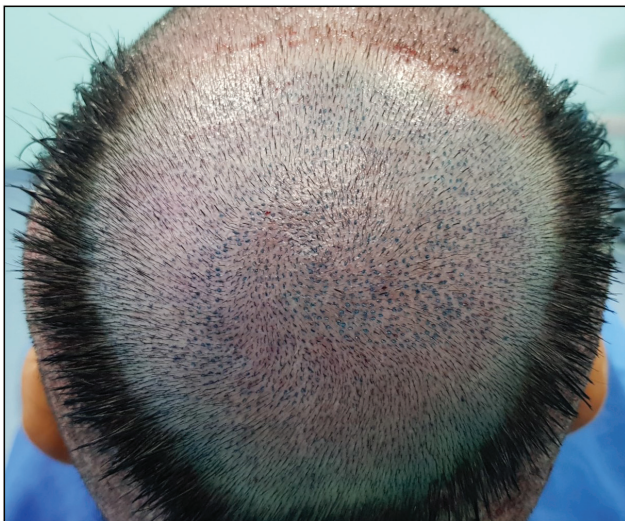
### Graft implantation by dull needle implanters in premade slits

After completion of simultaneous extraction and plantation, the patient was made to lie in supine position. These harvested grafts then implanted into the premade slits with the help of implanters from both the sides of the head by two assistants [Figure 3].

Meticulous attempts were made to implant some 20%–50% of the grafts, which were scored by the surgeon, into the premade slits by the end of the scoring. It means around 200–500 grafts were already implanted into the slits by the completion of scoring of 1000 grafts in 30 min–1 h. The rest of the grafts were implanted in supine position by two surgical assistants simultaneously to reduce the out of body time of the grafts. We could carry out the implantation in right lateral, left lateral, and prone positions.

Patients were followed up on day seven and then at monthly intervals. The time periods at which the growth started becoming noticeable and became significantly appreciable were noted. The results were classified into the following two categories:

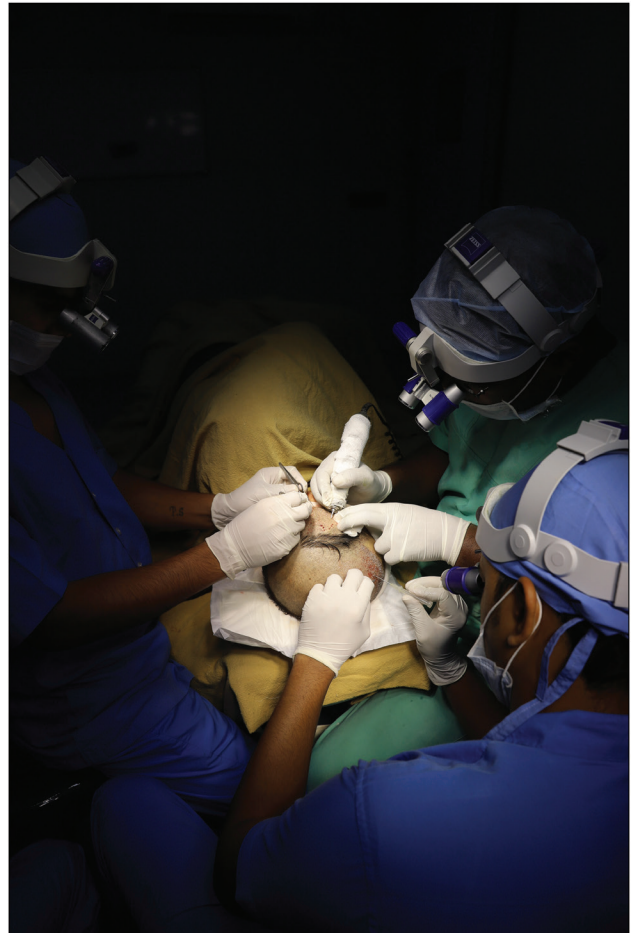1. *Patients with good growth.* Those who had noticeable photographic improvement and reduction in baldness grade according to the basic and specific classification (BASP) of male patterned baldness.



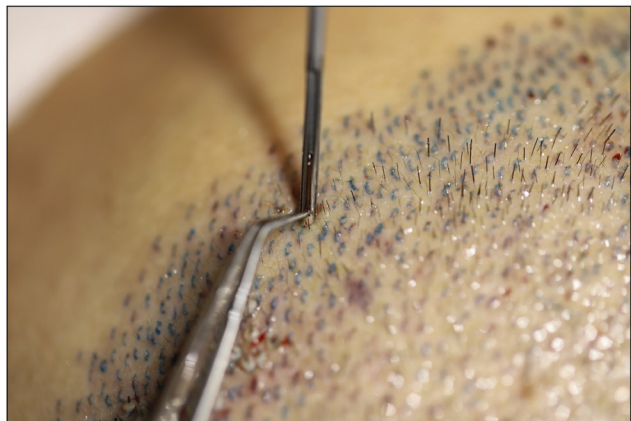
**Figure 1:** Slits are made before starting the process of simultaneous extraction and implantation

2. *Patients with poor growth.* Those who did not have noticeable photographic improvement and no reduction in the baldness grade according to the BASP of male patterned baldness.

Patients with BASP scales M1, M2, C1, V1, and F1 were recorded as “mild,” and patients with BASP scales M3,



**Figure 2:** Graft scoring, extraction, and placement being performed in the patient



**Figure 3:** Unloading of grafts from SAVATM implanters by pushing it from the epidermal end. The grafts were protruding slightly above the epidermis

C2, C3, U1, U2, U3, V2, V3, F2, and F3 were recorded as “severe.” A comparison of pre- and post-BASP classification was made.

## RESULTS

A total of 104 patients were recruited for the study. The age of the patients ranged from 25 to 51 years (mean age: 39 years). All male patients had androgenic alopecia with Norwood grades ranging from grades I to VII. Numbers of grafts transplanted were ranging from 1400 to 10410 by FUE technique either in one or two sessions.

According to pretransplant BASP classification, 98 (94.2%) patients were having severe type and 6 (5.8%) were having mild type. As per the posttransplant BASP classification, patients having severe and mild type were 24 (23%) and 80 (77%), respectively. Improvement in the BASP score (from severe to mild type) was seen in 74 patients (71%) and no change was seen in 30 patients (29%). Of 30 patients with no change in BASP classification, 24 patients were having severe type both at pre- and post-hair transplantation and 6 were having mild type. None of the patients noticed worsening of BASP classification.

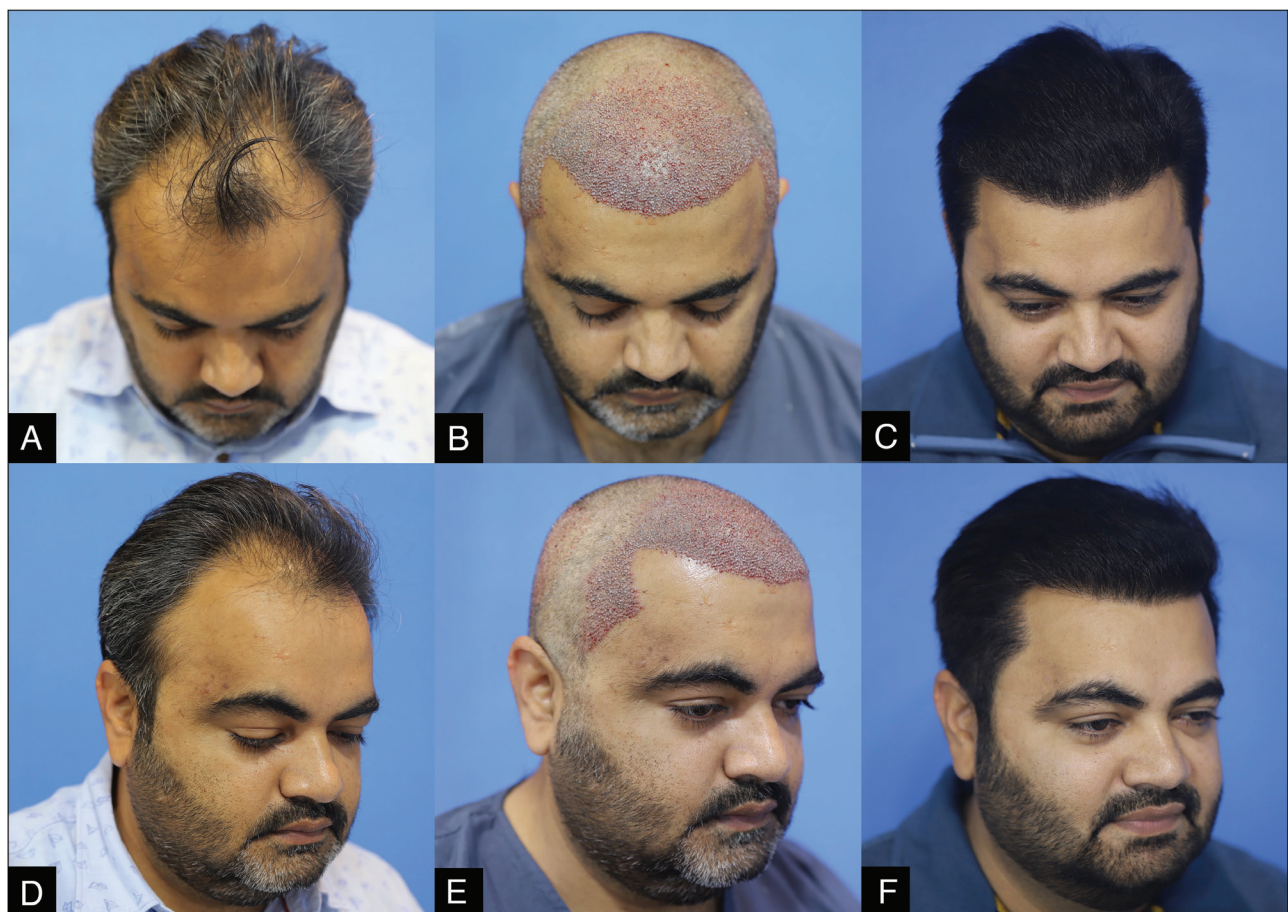Hair growth started becoming visible after two to five months and “good” results were obtained in all except two patients after a follow-up period varying from 8 to 18 months [Figures 4 and 5]. The patients who had “poor” result were a 50-year-old man with Norwood grade VII and a woman with Ludwig grade II.

The complications noticed after the procedure included donor area necrosis (one patient), persistent numbness of recipient zone for more than two months (five patients), burning sensation in donor site (four patients), and persistent folliculitis (six patients).

## DISCUSSION

Traditionally, there are three methods of implantation:<sup>[5]</sup>

1. Stick and place method
2. Premade recipient sites: It can be made using cut to size blades or needles. The graft can be inserted using jeweler’s forceps (holding the grafts just below or lateral to the bulb) or can be inserted by dilating the recipient site using a jeweler’s forceps.
3. Implanter<sup>[6]</sup>.



**Figure 4:** The above series of photographs depicts a patient where 4200 grafts were planted (scalp grafts). Front bend view (A, B, and C): A, preoperative; B, immediate postoperative; C, after five months. Right oblique view (D, E, and F): D, preoperative; E, immediate postoperative; F, after five months

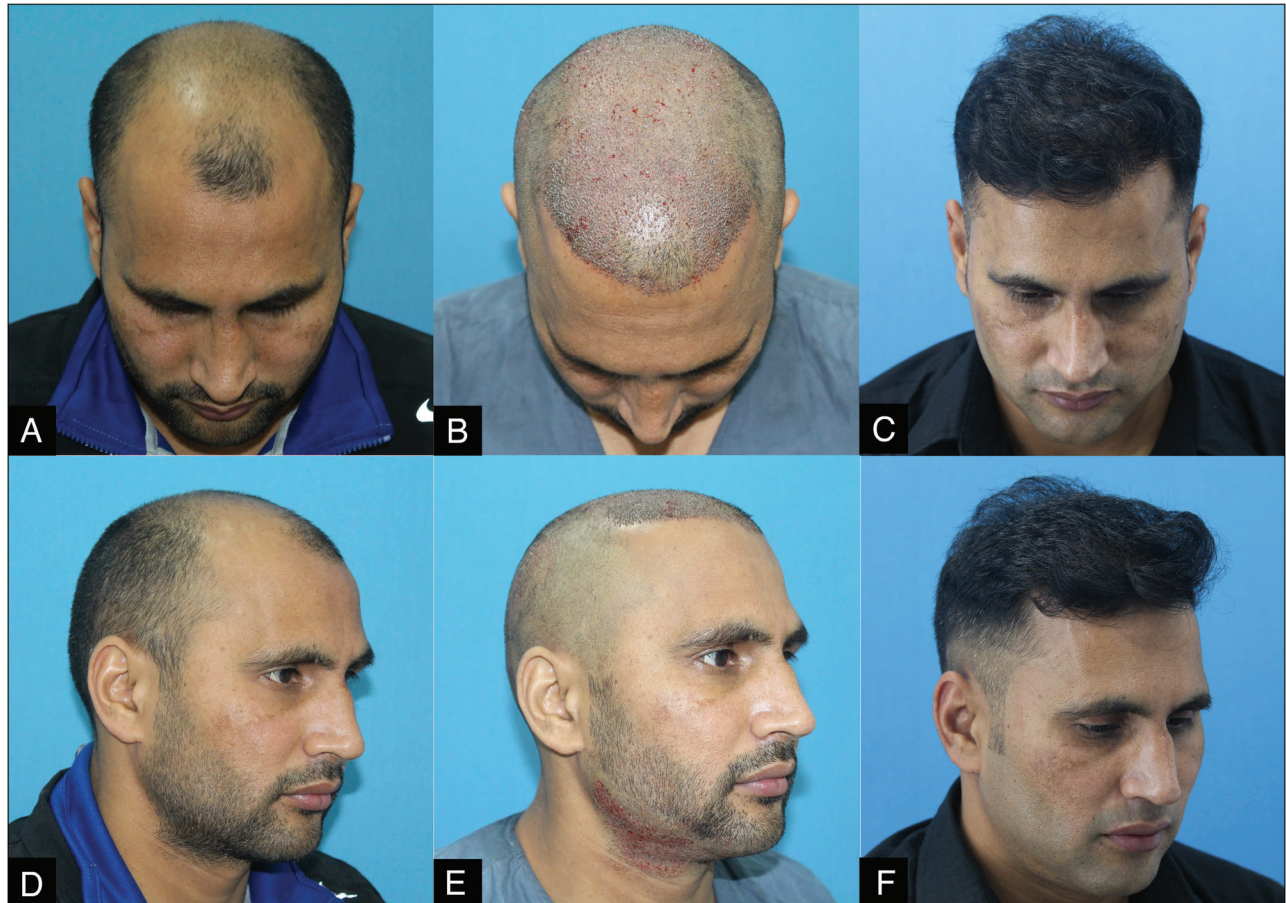Our technique is a modification of the conventional FUE, which combines the latter two methods described above [Table 1].

During the past decade, several instruments have been developed for implantation of the follicles, so as to reduce the mechanical handling of the graft during the process of implantation.<sup>[7]</sup>

In the case of direct implantation, their needles must be replaced frequently due to loss of sharpness and have been associated with popping of the graft and graft loss especially when the grafts are placed close together. To

overcome this problem, Lee *et al.*<sup>[8]</sup> suggested preparing the recipient site with premade slits using a 23-G needle. We improved on this technique and devised a system with which not only is the graft handling minimal but also the duration of the surgery and the out of body time are significantly reduced as all the steps of hair transplant can be performed simultaneously by various members of the team. The advantages of our modification over the other techniques are as follows [Table 1]:

1. Nearly zero mechanical handling of the follicular unit graft.



**Figure 5:** The above series of photographs depicts a patient where 5060 grafts were planted (scalp 3250 grafts and beard 1810 grafts). Front bend view (A, B, and C): A, preoperative; B, immediate postoperative; C, after 9.5 months. Right oblique view (D, E, and F): D, preoperative; E, immediate postoperative; F, after 9.5 months

Table 1: Comparison of various techniques for graft placement used in follicular unit extraction					
Serial no.	Particulars	Stick and place method	Premade recipient sites	Implanter	Our technique
1.	Performed by	Physician	Physician and assistant	Physician	Physician and assistant
2.	Mechanical graft handling	Present	Present (one-hand technique) Absent (two-hand technique)	Very less	Very less
3.	Popping risk	High	Less	High	Less
4.	Learning curve	High	High	Less	Less
5.	Cost	Less	Less	High	Less
6.	Position of patient's head	Supine	Supine	Supine	All positions

2. The force required to insert the graft into the scalp is minimized because of premade site. As the skin is already incised, while inserting the implanter into premade site, the lateral tension is less and thus popping is very less.
3. Less number of sharp implanters is required, thus cutting the cost of surgery.
4. The physician's time is saved as they can plan the shape of hairline, density, direction, and angulation of implanted grafts. If premade sites are not made, then the grafts need to be implanted by the physician himself.
5. It is made possible to implant in any position, whether the patient is lying in prone, supine, or lateral positions.
6. Simultaneous extraction is also made possible because the implantation continues unabated in spite of slight vibrational movement of patient's head.
7. Implantation can be done with the patient's head in any position.

We prefer the SAVA™ implanter. The following design aspects of the device make it superior to the other implanters:

- It is broad from above making it easy to introduce the graft into the implanter (loading).
- As we advance inferiorly, there is a mild constriction that holds the grafts inside the lumen of implanter.
- The exit of the needle is beveled with a sharp tip that ensures that it moves into the premade recipient site smoothly.
- Curl can be maintained.
- No longer a blind: The visibility of graft within the lumen of implanter is maintained.

It has been observed that use of sharp needle Choi implanters used to implant FUE grafts without making premade recipient sites attenuates the chances of graft damage. While placing, implanters prevent crushing and most of the hooking of FUE grafts. In experienced hands, the risk of “distal hooking” and “bulb decapitations” is marginal.<sup>[9]</sup>

## CONCLUSION

By using implanter to implant grafts in premade slits, the ease of plantation is increased a lot. At the same

time, implantation process becomes much faster and we can plant in any position. Thus, we encourage the FUE surgeon to try this modification and incorporate in their practice. However, we have not made the comparison of results of different implantation techniques. We have just documented another way of performing it.

## Declaration of patient consent

The authors certify that they have obtained all appropriate patient consent forms. In the form the patient(s) has/have given his/her/their consent for his/her/their images and other clinical information to be reported in the journal. The patients understand that their names and initials will not be published and due efforts will be made to conceal their identity, but anonymity cannot be guaranteed.

## Financial support and sponsorship

Nil.

## Conflicts of interest

There are no conflicts of interest.

## REFERENCES

1. Rose PT. Hair restoration surgery: challenges and solutions. *Clin Cosmet Investig Dermatol* 2015;8:361-70.
2. Sethi P, Bansal A. Direct hair transplantation: a modified follicular unit extraction technique. *J Cutan Aesthet Surg* 2013;6:100-5.
3. Harris JA. Follicular unit extraction. *Facial Plast Surg Clin North Am* 2013;21:375-84.
4. Lee SJ, Lee HJ, Hwang SJ, Kim DW, Jun JB, Chung SL, *et al.* Evaluation of survival rate after follicular unit transplantation using the KNU implanter. *Dermatol Surg* 2001;27:716-20.
5. Kim JC. Graft implanters. In: Ungerand W, Shapiro R, editors. *Hair transplantation*. 5th ed. New York: Informa; 2011. pp. 404-6.
6. Caroli S, Pathomvanich D, Amonpattana K, Kumar A. Current status of hair restoration surgery. *Int Surg* 2011;96:345-51.
7. Bicknell LM, Kash N, Kavouspour C, Rashid RM. Follicular unit extraction hair transplant harvest: a review of current recommendations and future considerations. *Dermatol Online J* 2014;20.
8. Lee DY, Lee JH, Yang JM, Lee ES. New instrument for hair transplant: multichannel hair transplanter. *Dermatol Surg* 2005;31:379.
9. Speranzini M. Graft placement using the dull needle implanter (DNI) technique. *Hair Transplant Forum Int* 2017;27:52-6.