

# Noncultured Extracted Hair Follicle Outer Root Sheath Cell Suspension versus Noncultured Epidermal Cell Suspension in the Treatment of Stable Vitiligo

Ashraf Mahmoud Hamza, Tarek Mahmoud Hussein, Hadir AbdelGawad Ragab Shakshouk

Department of Dermatology, Venereology and Andrology, Faculty of Medicine, University of Alexandria, Alexandria, Egypt

## Abstract

**Background:** Various treatment modalities exist for vitiligo, yet none of them are curative. Vitiligo is still considered a challenging disease to manage. Surgical treatment offers an excellent option for patients with stable vitiligo, especially those who fail to respond to medical treatment. Cell suspension techniques carry the advantage of covering large surface areas. **Objective:** To compare noncultured extracted hair follicle outer root sheath cell suspension (NCORSHFS) and noncultured epidermal cell suspension (NCES) in producing repigmentation. **Subjects and Methods:** Twenty patients were randomly allocated into two groups. They were objectively evaluated for the extent of repigmentation (after 1, 2, and 3 months), complications, cosmetic outcome, and satisfaction. **Results:** In NCORSHFS group, 10% showed excellent pigmentation, 20% showed good pigmentation, 50% fair, and 20% poor pigmentation. In NCES group, 10% showed excellent pigmentation, 10% good pigmentation, 40% fair, and 40% poor pigmentation. This difference was not statistically significant. Excellent color match was observed in 80% of NCORSHFS and in 70% of NCES. Donor area complications were absent in NCORSHFS group, whereas in NCES, mild scarring in 20% and hyperpigmentation in 40% of patients was observed. The difference in patients' satisfaction between the two groups was not statistically significant. **Conclusion:** Both NCORSHFS and NCES are effective in producing good repigmentation with perfect color match and patients' satisfaction. NCORSHFS has no donor area complications because it is a scarless procedure.

**Keywords:** Dermatologic surgery, pigmentation, vitiligo

## INTRODUCTION

Vitiligo represents the most common depigmenting disorder, affecting 0.4%–2% of the world population.<sup>[1]</sup> It is a psychologically devastating autoimmune disorder with significant impairment of the patient's quality of life.<sup>[2]</sup> Vitiligo is a disease lacking definitive and completely effective therapies. Numerous medical and surgical treatments are available.

Surgical transplantation techniques for vitiligo are classified according to the nature of the graft into tissue and cellular grafts. Cellular grafting techniques include cultured epidermal cell suspension, cultured melanocyte suspension, noncultured epidermal cell suspension (NCES), and noncultured extracted hair follicle outer root sheath cell suspension (NCORSHFS).<sup>[3]</sup>

The potential advantage of techniques based on cell separation and/or culture is to allow the treatment of larger lesions than techniques based on whole tissue. However, these techniques require special personnel and additional equipment/supplies, therefore creating limitations regarding the cost and availability of these procedures. Thanks to the ongoing research that is conducted over the years to simplify these procedures, various modifications are made to render them easier and more available with less cost.<sup>[4]</sup>

**Address for correspondence:** Dr. Hadir AbdelGawad Ragab Shakshouk,  
Department of Dermatology,  
Venereology and Andrology, Faculty of Medicine,  
University of Alexandria, Alexandria, Egypt.  
E-mail: drhadir58@gmail.com

### Access this article online

Quick Response Code:



Website:  
[www.jcasonline.com](http://www.jcasonline.com)

DOI:  
10.4103/JCAS.JCAS\_136\_18

This is an open access journal, and articles are distributed under the terms of the Creative Commons Attribution-NonCommercial-ShareAlike 4.0 License, which allows others to remix, tweak, and build upon the work non-commercially, as long as appropriate credit is given and the new creations are licensed under the identical terms.

**For reprints contact:** [reprints@medknow.com](mailto:reprints@medknow.com)

**How to cite this article:** Hamza AM, Hussein TM, Shakshouk HAR. Noncultured extracted hair follicle outer root sheath cell suspension versus noncultured epidermal cell suspension in the treatment of stable vitiligo. *J Cutan Aesthet Surg* 2019;12:105-111.

NCORSHFS is an emerging technique with promising results and it is considered an excellent option for treating large areas of vitiligo, which is a shared advantage with NCES technique. The aim of this study was to compare the effectiveness of autologous NCORSHFS and autologous NCES in producing repigmentation in patients with stable vitiligo. In addition to comparing the two techniques in terms of complications, cosmetic outcome and patients' satisfaction were also compared.

## SUBJECTS AND METHODS

This study was carried out on 20 patients of both sexes presenting with stable vitiligo to the department of dermatology, venereology, and andrology outpatient and phototherapy clinics in Alexandria Main University Hospital, Alexandria, Egypt, between August 2017 and January 2018.

Patients with stable vitiligo for at least 6 months were included in the study. Stability is defined as no appearance of new lesions and no progression of existing lesions for the past 6 months or more. Patients with a history of hypertrophic and keloidal scars or bleeding disorders and pregnant or lactating females were excluded.

This study was approved by the local ethics committee, and an informed written consent was obtained from every patient included in the study.

Patients were randomly allocated, by closed-envelope method, into the following two equal groups, 10 patients each: Group A: patients that underwent autologous NCORSHFS, Group B: patients that underwent autologous NCES.

### Technique of autologous NCORSHFS

The hair follicles were obtained by the follicular unit extraction (FUE) method. Hairs from occipital region were trimmed to a length of approximately 2 mm. The area was surgically prepared using povidone-iodine lotion, then anesthetized using 2% lignocaine local infiltration. A disposable 1-mm skin biopsy punch was used to obtain follicular units; the punch was rotated in the direction of the hair follicle until it reached the mid-dermis. Then, the follicular unit was pulled out gently using fine forceps by holding the skin surrounding the hair shaft. This was aided by the use of surgical loupes with 3.5× magnification. Approximately 15–25 pigmented follicles were extracted per patient. Then, the follicular units were collected in sterile Petri dish containing approximately 4 mL of 0.25% trypsin-EDTA (trypsin-ethylenediaminetetraacetic acid) solution (Lonza Bioscience, Falcon® Corning company, New York, USA).<sup>[5]</sup>

The Petri dish containing the hair follicles was placed in the incubator at 37°C for 90 min to prepare the single-cell suspension. Every 30 min, the follicles are removed and placed in a new Petri dish containing 0.25% trypsin-EDTA

and the reaction in the previous was terminated by adding fetal bovine serum (HL-1 Fetal Bovine Serum Substitute, Lonza Bioscience), which is a substitute for trypsin inhibitor. This was carried out to prevent digestion of separated cells by trypsin. The cell suspensions of all the three Petri dishes were combined and filtered through a Falcon 70-µm cell strainer in one Falcon tube (Falcon® Corning company, New York, USA) to prepare a single-cell suspension.<sup>[6]</sup>

The cell suspension was centrifuged for 5 min at 1000 rpm to obtain a cell pellet, which was resuspended in a small amount of phosphate-buffered saline (PBS) solution (Lonza Bioscience) for transplantation.<sup>[7]</sup>

### Technique of autologous NCES

The donor area used was a normally pigmented area of approximately 3–5 cm<sup>2</sup> in the gluteal region or upper thigh. The area was surgically prepared using povidone-iodine lotion, then anesthetized using 2% lignocaine local infiltration. The skin is stretched to help providing a very thin sheet of skin. An ultrathin skin graft was obtained using a razor blade attached to artery forceps. The superficial wound was then covered with a sterile vaselinated gauze.

The specimen was placed in a sterile Petri dish containing approximately 4 mL of 0.25% trypsin-EDTA solution. It was immediately put in incubator at 37°C for 45 min. The mixture was neutralized with PBS solution to stop the action of trypsin. The epidermis was manually broken down into small fragments using two jeweler forceps. The epidermal parts suspended in PBS were placed in a Falcon tube and then centrifuged at 2000 rpm speed for 10 min to prepare the cell suspension. The cell pellet obtained was resuspended in 0.5–1 mL of PBS.<sup>[8,9]</sup>

### In both groups

The recipient area was dermabraded superficially using high-speed motorized dermabrader 20,000 rpm, fitted with a diamond fraise. The dermabrasion was performed in at least two different directions. It was extended 3 mm beyond the borders of the lesion to avoid a halo of depigmentation. Appearance of pinpoint bleeding spots was considered the end point as it indicates reaching the level of dermo-epidermal junction. The denuded area was washed with saline solution and kept under moistened gauze for few minutes to ensure that bleeding has stopped. A thin film of the prepared suspension either NCORSHFS or NCES was applied over the dermabraded area using a pipette and spread evenly on the whole area. The recipient site was then covered with collagen, which helps transplanted cells to remain in place and thereby promotes cellular growth and vascularization. Paraffin-embedded nonadherent sterile gauze (Sufra-tulle, Hoechst Marion Roussel, Kansas, USA) is then applied, followed by Tegaderm (3M™ Tegaderm™ Transparent Film Dressing, USA) transparent dressing to

hold it in place. If a limb was operated on, then the patient was advised restricted movements for 1 week. Dressings were removed after 7 days.

Starting 2 weeks after the removal of the dressing, the patients were treated with narrow band-ultraviolet B (NB-UVB, Herbert Waldmann GmbH & Co. KG, Germany) as monotherapy using a Waldmann Lichttechnik unit as the light source for NB-UVB, containing a bank of eight fluorescent tubes (Philips TL-01) with an emission spectrum of 310–315nm, and a maximum wavelength of 311nm. NB-UVB-phototherapy was continued for 3 months twice weekly.

### Follow-up

The patients in both groups were asked to follow up at the clinic on day 8, and 1, 2, and 3 months after the transplantation procedure. On day 8, the dressing was removed by the researcher.

At 1, 2, and 3 months of follow-up visits, digital photographs were taken for evaluating the extent of repigmentation along different intervals.

After 3 months, the patients were evaluated for the color match and any possible complications. Also, they were asked about their satisfaction and expressed as satisfied, fair, and unsatisfied.

Repigmentation results were evaluated by the researcher using the digital images. Their scores were confirmed by objective measurement of the extent of repigmentation by the ImageJ (ImageJ, US National Institutes of Health, Bethesda, Maryland), a digital image analysis system. Using this simple morphometric software, the treated site surface area and the surface area of repigmentation could be objectively measured, and the percentage of repigmentation was then calculated by highlighting the vitiliginous patch and the repigmented area and then calculating the surface area using this software as shown in Figure 1.

Repigmentation was graded after 3 months as shown in Table 1.<sup>[6]</sup>

Color matching of the grafted skin was evaluated by the researcher using the digital images. It was graded as excellent, denoting perfect color match with surrounding skin; good, which could be slightly darker or lighter than the surrounding skin but still cosmetically accepted; and fair, denoting grossly unacceptable hyper- or hypopigmentation.

### Statistical analysis

Data were fed to the computer and analyzed using the Statistical Package for the Social Sciences (SPSS; IBM, New York, USA) software package, version 20.0. Qualitative data were described using number and percent. Quantitative data were described using range (minimum

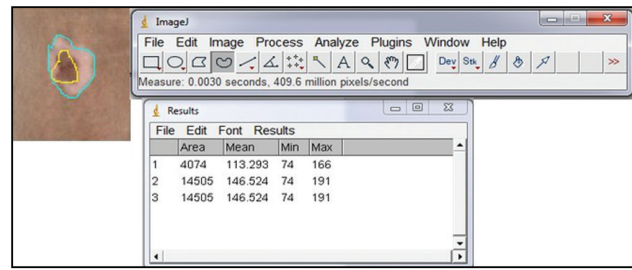


Figure 1: Using ImageJ software to calculate the extent of repigmentation

Table 1: Grading to assess the extent of repigmentation

Repigmentation calculated	Grade
<50%	Poor repigmentation
50%–74%	Fair repigmentation
75%–89%	Good repigmentation
90%–100%	Excellent repigmentation

and maximum), mean, standard deviation (SD), and median. Significance of the obtained results was judged at the 5% level.

The chi-square test was used for categorical variables to compare between different groups. The Monte Carlo correction was performed as correction for chi-square when more than 20% of the cells have expected count less than 5.

Wilcoxon signed-rank test was carried out for abnormally quantitative variables to compare between two periods. Spearman coefficient was used to correlate between two abnormally quantitative variables.

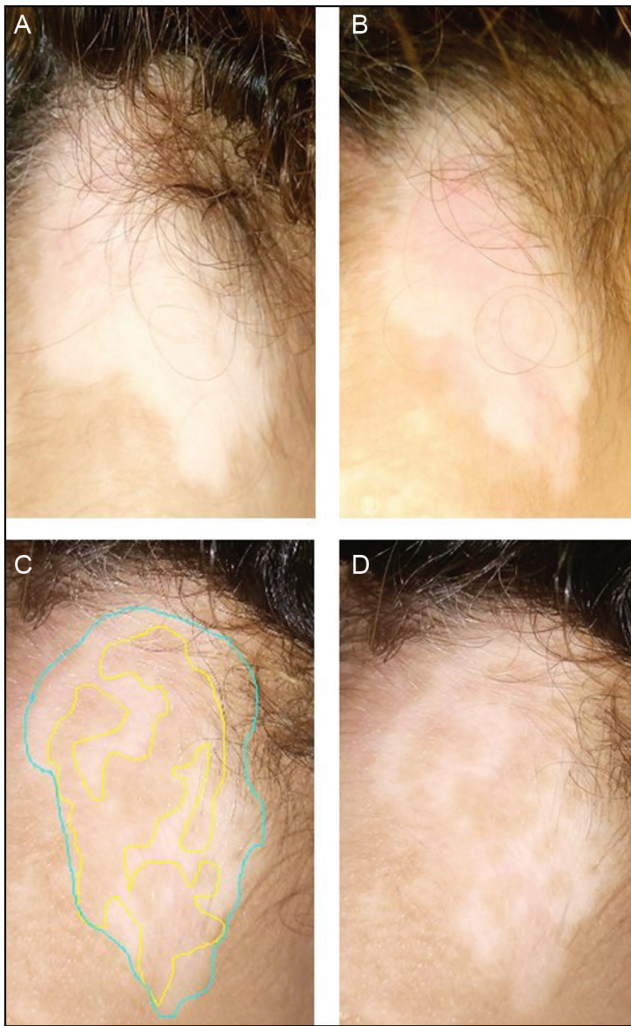
## RESULTS

All the patients completed the study of 3 months and were included in the final analysis.

No statistical significance was observed between the two studied groups regarding demographic characteristics. Males constituted 40% and females 60% in NCORSHFS group, whereas in NCES group, 70% were males and 30% were females ( $\chi^2 = 1.81$ ,  $P = 0.37$ ). The median age in NCORSHFS group was 27 years, with a range from 15–45 years, whereas in NCES group, the median age was 39 years with a range from 14–52 years.

No statistical significance between the two studied groups was noted regarding the clinical data, Fitzpatrick skin type (multiple comparison procedures (MCP) = 0.109), type of vitiligo (MCP = 0.311), duration of the disease ( $U = 26$ ,  $P = 0.075$ ), and duration of the stability ( $U = 35$ ,  $P = 0.28$ );  $U$  is the value calculated from the Mann-Whitney Test in SPSS.

*Extent of repigmentation:* Among the NCORSHFS group, a slight significant difference in the extent of repigmentation was noted after 1st and 2nd month ( $P = 0.057$ ; \* here indicates statistically significant) of



**Figure 2:** A patient with focal vitiligo on the nape of the neck treated with NCORSHFS showing excellent pigmentation (90%) after 3 months with excellent color match. (A) Before surgery. (B) After 1 month. (C) After 2 months. (D) After 3 months

treatment. Also, a statistically significant difference was noted between 1 and 3 months postoperative follow-up ( $P < 0.0001^*$ ). However, no statistically significant difference was noted between 2nd and 3rd month of follow-up ( $P = 0.133$ ).

Similarly, among the NCES group, a slightly significant difference in the extent of repigmentation was noted when comparing between 1st and 2nd month of follow-up ( $P = 0.057$ ). This difference is highly significant between 1st and 3rd month ( $P < 0.0001$ ) although no difference in the extent of repigmentation was observed between 2nd and 3rd month.

Comparing the two groups, the extent of repigmentation between the two groups along 1, 2, and 3 months follow-up assessment showed no statistically significant difference.

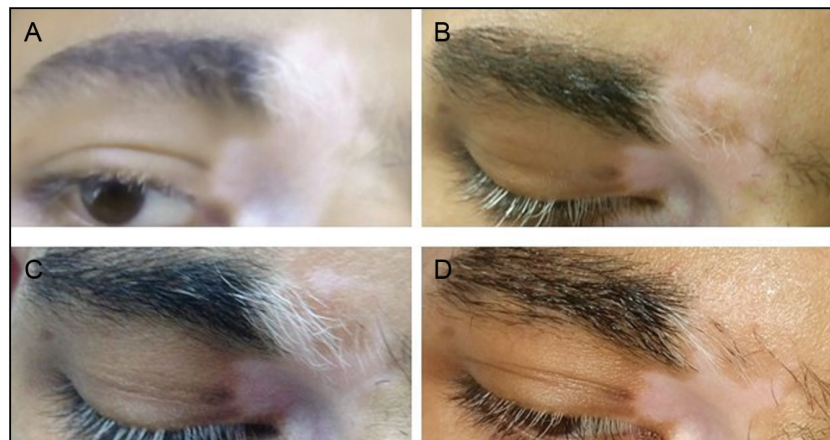
After 1 month, the NCORSHFS group showed mean repigmentation of 15.5%, whereas the NCES group showed 14.5%, which was statistically insignificant ( $P = 0.971$ ).

After 2 months, the NCORSHFS group showed mean repigmentation of 31.5%, whereas the NCES group showed 26%, which was statistically insignificant ( $P = 0.19$ ).

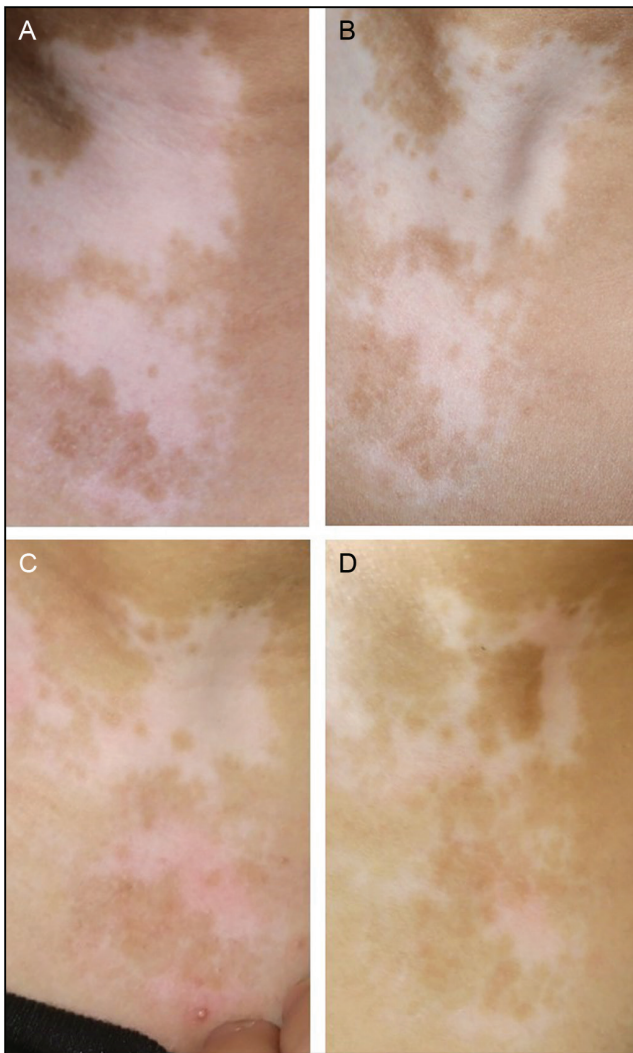
After 3 months, the NCORSHFS group showed mean repigmentation of 57.5%, whereas the NCES group showed 50%, which was statistically insignificant ( $P = 0.105$ ).

In the NCORSHFS group, 10% showed excellent pigmentation, 20% showed good pigmentation, 50% showed fair pigmentation, and 20% showed poor pigmentation.

In the NCES group, 10% showed excellent pigmentation, 10% showed good pigmentation, 40% showed fair pigmentation, and 40% showed poor pigmentation.



**Figure 3:** A patient with segmental vitiligo treated with NCORSHFS showing fair pigmentation (50%) after 3 months with excellent color match. (A) Before surgery. (B) After 1 month. (C) After 2 months. (D) After 3 months. Note that the eyebrow hair also started to repigment



**Figure 4:** A 14-year-old female patient with segmental vitiligo on the neck treated with NCES showing excellent pigmentation (90%) after 3 months with excellent color match. (A) Before surgery. (B) After 1 month. (C) After 2 months. (D) After 3 months

By comparing the two studied groups regarding the extent of repigmentation after 3 months as a final outcome in this study, no statistically significant difference was observed between the two groups (MCP = 0.319).

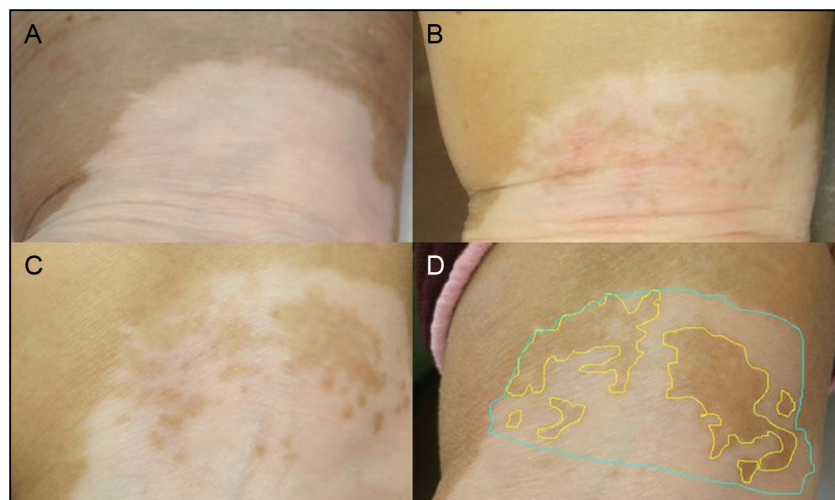
Regarding the color match, in NCORSHFS group, 80% showed excellent color match perfectly matching the surrounding skin and 20% showed good color match, which was slightly darker than the surrounding skin but still cosmetically accepted. In NCES group, excellent color match was observed in 70% of patients and also good color match, slightly darker in 30% of patients. The difference between the two groups was not statistically significant.

Complications were evaluated in donor area and were totally absent in NCORSHFS group, whereas in NCES group, mild scarring was observed in 20% of patients and hyperpigmentation in 40% of patients. The difference was statistically significant (MCP = 0.007\*).

Patients' satisfaction was roughly assessed by asking the patients about the procedure itself and the outcome and it was graded as satisfied, fair, and unsatisfied. In NCORSHFS, eight of 10 patients were satisfied and two of 10 responded as fair. In NCES, five of 10 patients were satisfied, three responded as fair and two patients were unsatisfied. The difference between the two groups was not statistically significant (MCP = 0.09).

## DISCUSSION

Various treatment modalities exist for vitiligo, yet none of them are curative. Vitiligo is still considered a challenging disease to manage. Surgical treatment offers an excellent option for patients with stable vitiligo, especially those who fail to respond to medical treatment. NCES and NCORSHFS are considered simple and cheap methods of cellular grafts requiring minimal infrastructure. Also,



**Figure 5:** A 40-year-old female patient with generalized vitiligo. A patch on her wrist treated with NCES showing fair pigmentation (53%) after 3 months with excellent color match. (A) Before surgery. (B) After 1 month. (C) After 2 months. (D) After 3 months

both share the advantage of treating large areas of vitiligo.<sup>[10]</sup>

Despite the variety of surgical procedures, they all share the same principle. Typically, skin is removed from normally pigmented skin at the donor site, which is then either directly transferred or manipulated and transferred to the recipient site aiming to introduce missing melanocytes in the depigmented lesions of vitiligo.<sup>[11]</sup>

Surgical treatment is classified into tissue grafts and cellular grafts. In tissue grafts, intact pieces of uninvolved epidermis are used to transfer melanocytes. On the contrary, in cellular grafts, cells are extracted from an unaffected skin or hair sample and transplanted as a suspension.

The NCES technique is not a new method, it dates back to 1992, when Gauthier and Surleve-Bazeille<sup>[12]</sup> suggested it as a treatment option for stable vitiligo. Since then, NCES went through many modifications aiming to simplify the technique with least cost and effort. In this study, we used the easiest technique with least cost.

It is concluded that the transplantation of NCES is an efficacious and safe procedure. In this study, one patient (10%) showed excellent pigmentation (90%–100%), one patient (10%) showed good pigmentation (75%–89%), 40% of patients showed fair pigmentation (50%–74%), and 40% showed less than 50% pigmentation, which was graded as poor response. Many studies were conducted to assess the efficacy of NCES with widely variable response rates, with a range of 13%–86% of patients achieving 95%–100% repigmentation. This wide variability in responses could be attributed to many factors such as size of the study population, vitiligo subtype, anatomic region affected/treated, follow-up period, repigmentation grading system, and variations in the different steps of the procedure. Differences in these variables make comparing studies challenging. It is worth mentioning that in this study, we used ImageJ software that can objectively assess the extent of repigmentation, and to the best of our knowledge, this is the first study to introduce such an objective tool in calculating the extent of repigmentation. Our results are limited by the small sample size and short duration of follow-up.

NCORSHFS is a novel surgical method of cellular transplantation. The idea first came from the clinical observation of repigmentation pattern in vitiligo lesions, which often starts around the follicles. This phenomenon is called “perifollicular repigmentation,” and suggests the existence of a melanocyte “reservoir” population in the human hair follicle. This phenomenon was studied extensively by Staricco,<sup>[13]</sup> who identified an amelanotic outer root sheath (ORS) cell population. The bulge area or lower permanent portion of the hair follicle was later identified as the stem cell niche. Melanocyte stem cells were identified and localized to this site in *Dct-LacZ* transgenic mice by Nishimura *et al.*,<sup>[14]</sup> in 2002, who identified *LacZ*-positive cells in the bulge and

sub-bulge area of murine hair follicles, which produced mature melanocytes during subsequent hair cycles. These cells had all the hallmarks of melanocyte stem cells, that is, slow cycling, self-maintaining, and an ability to generate differentiated cells. This observation of the bulge region of the follicle as a stem cell niche has had a great impact on pigment cell biology. These findings suggested that inactive melanocytes in the ORS of the hair follicle divide, proliferate, and mature during the process of repigmentation, and may potentially be harvested and cultivated for therapeutic purposes in vitiligo. This was the rationale for the innovation of the technique of NCEF ORS cell suspension transplantation for the treatment of stable vitiligo.

Mohanty *et al.*<sup>[7]</sup> was the first to obtain the hair follicle tissue by the FUE method, which takes out the hair follicle completely along with its stem cell reservoir and a narrow rim of perifollicular dermal sheath. This resulted in successful repigmentation (>75%) noted in nine of 14 patients treated by this method, with a mean ( $\pm$ SD) repigmentation of 65.7%  $\pm$  36.7%.

In this study, we observed one patient (10%) with excellent pigmentation (>90%) in the NCORSHFS group, two patients (20%) showed good pigmentation, 50% showed fair pigmentation, and 20% showed poor pigmentation.

Comparing the two studied groups, no statistically significant difference in the extent of repigmentation was observed. A total of 50% of the patients in both groups showed excellent and good repigmentation. This denotes the effectiveness of the two techniques in producing repigmentation.

Similar conclusion was observed in a previous study by Singh *et al.*,<sup>[6]</sup> where excellent and good repigmentation were noted in NCES and NCORSHFS with no statistically significant difference ( $P > 0.05$ ).

Evaluating the possible complications in both the techniques, NCORSHFS group showed no complications at donor area, whereas in NCES group, mild scarring was observed in 20% of patients and hyperpigmentation in 40% of patients. The difference was statistically significant (MCP = 007\*). This highlights an added advantage of NCORSHFS, of it being a scarless procedure as only few punches (in millimeters) are obtained by FUE with rapid healing.

Patients in the NCORSHFS group were slightly more satisfied than those in the NCES group but the difference was not statistically different (MCP = 0.09). This can be explained by the comparable efficacy in producing repigmentation. Also, patients more likely accepted NCORSHFS as it was not associated with complications unlike NCES, which was associated with mild scarring and hyperpigmentation. These observations were different from a study conducted by Singh *et al.*,<sup>[6]</sup> they reported significantly higher patient satisfaction in the NCES group than that in the NCORSHFS group ( $P < 0.05$ ). This was due to highly significant repigmentation at 4 weeks in the NCES group compared with that in the NCORSHFS group.<sup>[6]</sup>

## CONCLUSION

In conclusion, this study shows the efficacy of both NCES and NCORSHFS in producing excellent and good repigmentation in patients with stable vitiligo with perfect color match and patients' satisfaction. Both procedures proved to be safe and simple with reasonable cost compared to the sophisticated cultured cellular grafts. However, NCORSHFS requires skilled surgeon in performing FUE. NCORSHFS proves to be superior as it is associated with no donor area complications because it is a scarless procedure. This technique offers an excellent addition to the armamentarium of vitiligo treatment.

## Declaration of patient consent

The authors certify that they have obtained all appropriate patient consent forms. In the form the patient(s) has/have given his/her/their consent for his/her/their images and other clinical information to be reported in the journal. The patients understand that their names and initials will not be published and due efforts will be made to conceal their identity, but anonymity cannot be guaranteed.

## Financial support and sponsorship

Nil.

## Conflicts of interest

There are no conflicts of interest.

## REFERENCES

- Krüger C, Schallreuter KU. A review of the worldwide prevalence of vitiligo in children/adolescents and adults. *Int J Dermatol* 2012;51:1206-12.
- Ezzedine K, Sheth V, Rodrigues M, Eleftheriadou V, Harris JE, Hamzavi IH, *et al.*; Vitiligo Working Group. Vitiligo is not a cosmetic disease. *J Am Acad Dermatol* 2015;73:883-5.
- Gupta S, Olsson MJ, Parsad D, Lim HW, Geel N, Pandya AG. *Vitiligo: medical and surgical management*. New Jersey, USA: Wiley-Blackwell; 2018.
- Geel N, Goh B, Wallaey E, Keyser S, Lambert J. A review of non-cultured epidermal cellular grafting in vitiligo. *J Cutan Aesthet Surg* 2011;4:17-22.
- Kumar P, Bhari N, Tembhre MK, Mohanty S, Arava S, Sharma VK, *et al.* Study of efficacy and safety of noncultured, extracted follicular outer root sheath cell suspension transplantation in the management of stable vitiligo. *Int J Dermatol* 2018;57:245-9.
- Singh C, Parsad D, Kanwar AJ, Dogra S, Kumar R. Comparison between autologous noncultured extracted hair follicle outer root sheath cell suspension and autologous noncultured epidermal cell suspension in the treatment of stable vitiligo: a randomized study. *Br J Dermatol* 2013;169:287-93.
- Mohanty S, Kumar A, Dhawan J, Sreenivas V, Gupta S. Noncultured extracted hair follicle outer root sheath cell suspension for transplantation in vitiligo. *Br J Dermatol* 2011;164:1241-6.
- Parsad D, Kanwar A, Holla A, Kumar R. Modified procedure of noncultured epidermal suspension transplantation: changes are the core of vitiligo surgery. *J Cutan Aesthet Surg* 2011;4:44.
- Silpa-Archa N, Griffith JL, Huggins RH, Henderson MD, Kerr HA, Jacobsen G, *et al.* Long-term follow-up of patients undergoing autologous noncultured melanocyte-keratinocyte transplantation for vitiligo and other leukodermas. *J Am Acad Dermatol* 2017;77:318-27.
- Felsten LM, Alikhan A, Petronic-Rosic V. Vitiligo: a comprehensive overview part II: treatment options and approach to treatment. *J Am Acad Dermatol* 2011;65:493-514.
- Mohammad TF, Hamzavi IH. Surgical therapies for vitiligo. *Dermatol Clin* 2017;35:193-203.
- Gauthier Y, Surleve-Bazeille JE. Autologous grafting with noncultured melanocytes: a simplified method for treatment of depigmented lesions. *J Am Acad Dermatol* 1992;26:191-4.
- Staricco RG. Amelanotic melanocytes in the outer sheath of the human hair follicle and their role in the repigmentation of regenerated epidermis. *Ann N Y Acad Sci* 1963;100:239-55.
- Nishimura EK, Jordan SA, Oshima H, Yoshida H, Osawa M, Moriyama M, *et al.* Dominant role of the niche in melanocyte stem-cell fate determination. *Nature* 2002;416:854-60.