

# Innovative Usage of Accessory Auricles as Full-thickness Skin Graft

Elankumar Subbarayan, Ravikumar Chittoria

Department of Plastic Surgery, Jawaharlal Institute of Postgraduate Medical Education and Research, Puducherry, India

## Abstract

Accessory auricles are relatively rare malformations arising from the first branchial arch which contains skin, fat and cartilage. The treatment is usually surgical removal for the cosmetic purpose. We are sharing our experience of utilising the accessory auricle skin as full thickness graft for post-burn reconstruction of the fingers contracture of a child. Even though this type of association is rare, it is an innovative idea following Sir Harold Gilles' principle 'Never throw anything away'.

**Keywords:** Accessory auricles, burn reconstruction, full-thickness skin graft

## INTRODUCTION

Plastic surgery is the field based on principles. Every plastic surgeon does remember Sir Harold Gilles' important principle 'Never throw anything away'. Plastic surgeons use to face lot of congenital anomalies, which may require resection. Most of the times, the tissues resected will not be used and will be sent for histopathological examination. There are reports using accessory/excess tissues for reconstruction.<sup>[1]</sup> To the best of our knowledge, there is no reported case of using accessory auricles as a source of full-thickness skin graft (FTSG) found in literature. We have used FTSG harvested from the accessory auricles of a child with post-burn contracture of fingers for reconstructing the defect following the release of contracture.

## CASE REPORT

A 4-year-aged right-handed male child born of non-consanguineous marriage presented to the plastic surgery outpatient department, with the complaints of deformity and difficulty in extending the right index, middle, ring and little fingers of 18-month duration and abnormal soft-tissue swellings in the left pre-auricular and cheek region since birth [Figure 1]. Patient's medical record revealed that he had undergone release for the post-burn contracture of the finger- and split-thickness grafting for the resultant raw area elsewhere 2 years before, following which he developed recontracture. On examination, he was having recurrent post-burn contracture involving

index, middle, ring and little fingers (Kurtzman and Stern Type 1) and the second and third web space contracture.<sup>[2]</sup> He had two accessory auricles along the line joining angle of mouth to tragus on the left side. Pre-auricular accessory auricle was measuring 3 cm × 2 cm × 1 cm, cheek lesion was pedunculated and was measuring 3 cm × 1 cm × 1 cm and was situated 2 cm posterior to the left side angle of mouth. There were no associated craniofacial, spinal and eye anomalies. Hearing assessment, ultrasound abdomen and echocardiogram examinations found to be normal. The plan was to release the contractures and FTSG reconstruction in stages and excision of accessory auricles for cosmetic purpose. Considering the resultant multiple raw areas and donor-site morbidity, harvesting the FTSG from the accessory auricles was planned. Under general anaesthesia, accessory auricles along with its cartilage remnants excised [Figure 2]. Defects closed primarily. Under tourniquet control contractures of middle and ring fingers released. FTSG harvested from the excised accessory auricles and sutured to the raw areas resulting from the contracture release [Figures 3 and 4]. Fingers were immobilised.

**Address for correspondence:** Dr. Ravikumar Chittoria,  
Department of Plastic Surgery, Jawaharlal Institute of Postgraduate Medical  
Education and Research, Puducherry - 605 006, India.  
E-mail: drchittoria@yahoo.com

This is an open access article distributed under the terms of the Creative Commons Attribution-NonCommercial-ShareAlike 3.0 License, which allows others to remix, tweak, and build upon the work non-commercially, as long as the author is credited and the new creations are licensed under the identical terms.

**For reprints contact:** reprints@medknow.com

**How to cite this article:** Subbarayan E, Chittoria R. Innovative usage of accessory auricles as full-thickness skin graft. *J Cutan Aesthet Surg* 2018;10:150-2.

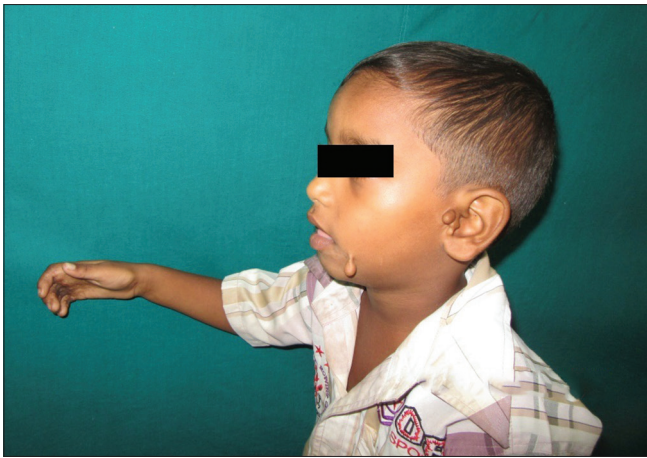### Access this article online

#### Quick Response Code:

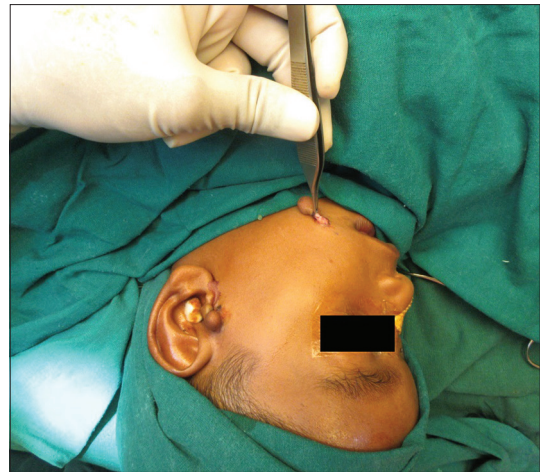

**Website:**  
www.jcasonline.com

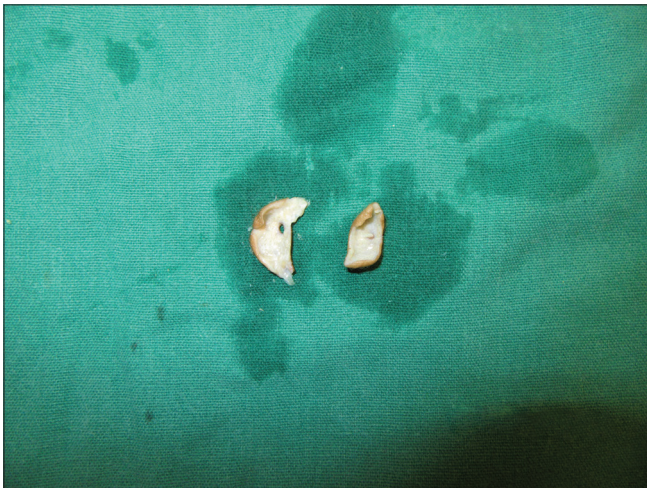
**DOI:**  
10.4103/JCAS.JCAS\_70\_17



**Figure 1:** Accessory auricles in cheek and pre-auricular region and recurrent post-burn contractures right hand



**Figure 2:** Excision of accessory auricle, cartilage remnant seen in the stalk of the lesion

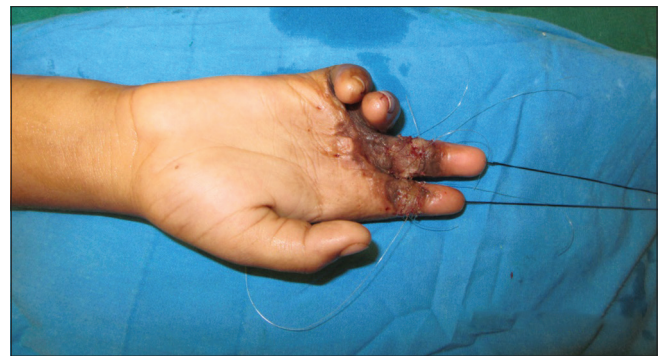


**Figure 3:** Full-thickness skin graft harvested from the accessory auricles

## DISCUSSION

Accessory auricles are the congenital soft-tissue protrusions that occur along the line of angle of mouth to tragus.<sup>[3]</sup> They usually made of skin, fat and cartilage derived from the first branchial arch anomaly.<sup>[3,4]</sup> They may occur as an isolated anomaly or may be associated with syndromes such as Treacher Collins and Goldenhar syndrome.<sup>[5]</sup> They may be associated with renal, cardiac and craniofacial anomalies, hence, routine cardiac examination and ultrasound abdomen examination are done to assess these systems.<sup>[6,7]</sup> Treatment for accessory auricles is surgical excision for cosmetic purposes.<sup>[8]</sup> Following excision, usually, the specimen will be sent to pathology department and will not be used for the same patient.

Reconstruction with FTSG following post-burn contracture release is an accepted modality of treatment.<sup>[9]</sup> FTSG can be harvested from many sites which will produce additional morbidity to the patient. Instead of using the other parts skin, the excised accessory auricles skin can be harvested as FTSG and used, which will reduce the additional morbidity to the patient. There are reports in literature of using lipoma for the



**Figure 4:** Full-thickness skin graft sutured to the raw area created by contracture release

breast reconstruction using prepuccial skin for grafts, etc.<sup>[11,10]</sup> To the best of our knowledge, there is no report seen using the accessory auricle as a source of FTSG seen in literature.

## CONCLUSION

Even though this case is a rare presentation, it re-emphasises the significance of using excess/accessory tissues for reconstruction of a defect if present. This case is presented here to share this idea.

## Declaration of patient consent

The authors certify that they have obtained all appropriate patient consent forms. In the form the patient(s) has/have given his/her/their consent for his/her/their images and other clinical information to be reported in the journal. The patients understand that their names and initials will not be published and due efforts will be made to conceal their identity, but anonymity cannot be guaranteed.

## Financial support and sponsorship

This study was financially supported by the Department of Plastic Surgery, Jawaharlal Institute of Postgraduate Medical Education and Research, Pondicherry, India.

## Conflicts of interest

There are no conflicts of interest.

## REFERENCES

1. Czerny V. Plastic replacement of the breast with a lipoma. *Chir Kongr Verh* 1895;2:216.
2. Kurtzman LC, Stern PJ. Upper extremity burn contractures. *Hand Clin* 1990;6:261-79.
3. Brownstein MH, Wanger N, Helwig EB. Accessory tragi. *Arch Dermatol* 1971;104:625-31.
4. Kono T, Ro H, Murakami N, Kochi M, Kuroki T, Tosa Y, *et al.* Accessory auricles affecting the tragus and cheek occurring with cervical chondrocutaneous branchial remnants: A case report. *JPRAS Open* 2015;6:20-4.
5. Al Aboud D. Syndromes which may feature accessory tragus: An overview. *J Pak Assoc Dermatologists* 2012;22:262-3.
6. Ulukaya Durakbasa Ç, Mutus M, Meric F, Sirlioglu E, Ayhan Y, Dedeoglu S, *et al.* Should children with isolated preauricular tags be routinely evaluated for associated renal and cardiac malformations. *Marmara Med J* 2004;17:109-12.
7. Kohelet D, Arbel E. A prospective search for urinary tract anomalies in infants with isolated preauricular tags. *Pediatrics* 2000;105:e61.
8. Moon IY, Oh KS. Surgical correction of an accessory auricle, polyotia. *Arch Plast Surg* 2014;41:427-9.
9. Saaq M, Zaib S, Ahmad S. The menace of post-burn contractures: A developing country's perspective. *Ann Burns Fire Disasters* 2012;25:152-8.
10. Subramaniam N, Udhay P, Mahesh L. Prepuccial skin graft for forniceal and socket reconstruction in complete cryptophthalmos with congenital cystic eye. *Ophthal Plast Reconstr Surg* 2008;24:227-9.