

Efficacy of 532-nm Q-switched Nd:YAG Laser in the Treatment of Lip Melanosis

Sulaksha Kerkar, Kanathur Shilpa, Thimmanahalli Narasimhan Revathi

Department of Dermatology, Bangalore Medical College and Research Institute (BMCRI) Bengaluru, Karnataka, India

Abstract

Introduction: Lip pigmentation is frequently encountered in the Dermatology outpatient department. No effective treatment is available so far. Topical treatment requires longer time and is often unsatisfactory. **Aim:** The aim of this work was to study the efficacy of 532-nm Q-switched Nd:YAG laser in the treatment of lip melanosis. **Settings and Design:** This was a prospective interventional study. **Materials and Methods:** Twenty patients in the age group 27–53 years were included in the study. Eight patients had diffuse pigmentation and twelve patients had focal pigmentation. Test spot was done. After topical anesthesia, Q-switched Nd:YAG laser was used. Treatment interval was 4 weeks. Follow-up was done at 1 week and then monthly. **Statistical Analysis Used:** Wilcoxon signed ranks test and *P* value. **Results:** Seven patients (35%) showed an excellent response with more than 75% of pigment clearance. Seven patients (35%) showed a good response, two patients (10%) moderate response, and two patients (10%) had a mild response. Two patients had recurrence after 3 months follow-up. The average number of sessions required for clearance of pigmentation was 2.5. No scarring was seen. **Conclusion:** 532-nm Q-switched Nd:YAG laser is safe and effective in the management of lip pigmentation and gives rapid results.

Keywords: Dark lips, laser, lip pigmentation, Nd:YAG, Q-switched

INTRODUCTION

Lip melanosis is a cosmetically disfiguring condition frequently encountered in the Dermatology outpatient department. Lip melanosis has multifactorial etiology. It may be congenital or acquired, physiological, or pathological.

Physiological pigmentation of the lips depends on ethnicity and is common in darker-skinned individuals. Causes of lip pigmentation include benign conditions (ephelides, lentigines, labial melanotic macule); malignant conditions (pigmented squamous cell carcinoma, malignant melanoma); drug-induced; post-inflammatory hyperpigmentation (PIH); endocrine disorders (Addison's disease, hemochromatosis, Cushing's disease); heavy metals; smoking; amalgam tattoo; Laugier–Hunziker syndrome and lentiginosis syndromes (Peutz–Jegher's syndrome, LEOPARD syndrome, Carney complex).^[1]

Many patients seek treatment due to cosmetic reasons, but no effective treatment is available so far. Topical treatment gives variable therapeutic results. This study was conducted to evaluate the efficacy of 532-nm Q-switched Nd:YAG laser in the treatment of lip melanosis.

MATERIALS AND METHODS

A prospective interventional study was conducted in the Department of Dermatology, at a tertiary care institute from September 2018 to July 2019.

Twenty patients (18 females and 2 males) with focal and diffuse lip pigmentation in the age group 27–53 years were enrolled in this study. Exclusion criteria were pregnancy,

Address for correspondence: Dr. Sulaksha Kerkar, Department of Dermatology, Victoria Hospital, OPD B Block, Bangalore Medical College and Research Institute (BMCRI), Bengaluru 560002, Karnataka, India.
E-mail: sulaksha292@gmail.com

Access this article online

Quick Response Code:



Website:
www.jcasonline.com

DOI:
10.4103/JCAS.JCAS_7_20

This is an open access journal, and articles are distributed under the terms of the Creative Commons Attribution-NonCommercial-ShareAlike 4.0 License, which allows others to remix, tweak, and build upon the work non-commercially, as long as appropriate credit is given and the new creations are licensed under the identical terms.

For reprints contact: reprints@medknow.com

How to cite this article: Kerkar S, Shilpa K, Revathi TN. Efficacy of 532-nm Q-switched Nd:YAG laser in the treatment of lip melanosis. *J Cutan Aesthet Surg* 2021;14:203-7.

keloidal tendency, immunosuppression, and patients with unrealistic expectations.

A detailed history and clinical examination was carried out. The procedure and possible adverse effects were explained. Written informed consent was obtained from all patients.

Treatment protocol

Photographs were taken at baseline and during each follow-up visit. In patients with history of herpes infection and PIH secondary to herpes simplex infection, oral acyclovir was started 2 days prior to the laser treatment and continued for 7 days post-procedure. Topical anesthetic cream (lidocaine 2.5% and prilocaine 2.5%) was applied on lips under occlusion for 1 h. Area to be treated was cooled with ice packs. Test spot was done. Q-switched Nd:YAG laser was used with the following parameters: wavelength: 532 nm, spot size: 3 mm, frequency: 1 Hz, and fluence: 2–3.4 J/cm² in a single pass.

Post-procedure, the treated area was cooled with ice packs and topical steroid-antibiotic ointment and lip balm with sunscreen was prescribed. Treatment interval was 4 weeks. Follow-up was done at 1 week and then monthly. No other topical treatment was used during the study.

Assessment

Evaluation was done by assessing the degree of clearance of pigmentation and the level of patient satisfaction as shown in Table 1. Clinical response was evaluated by using photographs taken before treatment and at each follow-up visit.

Statistical analysis

The Statistical Package for the Social Sciences (SPSS) software program was used. The grades of pigmentation

before and after treatment were subjected to Wilcoxon signed ranks test. A value of $P < 0.05$ was considered statistically significant.

RESULTS

This study included 20 patients (2 males and 18 females) with Fitzpatrick skin type III to V, aged between 27 and 53 years. Twelve patients had focal pigmentation and eight patients had diffuse pigmentation [Table 2].

Immediately after laser treatment whitening of the lesion was seen [Figures 1 and 2]. Mild swelling of the lips was noted which lasted for 30 min. Treated lesions turned darker subsequently and the crust flaked off in a week.

Seven patients (35%) showed an excellent response with more than 75% of pigment clearance. Seven patients (35%) showed a good response, two patients (10%) moderate response, and two patients (10%) had a mild response after laser treatment [Table 3 and Figures 3–6]. Two patients had recurrence after 3 months follow-up. There was a statistically significant improvement in pigmentation post-laser treatment ($P = 0.00$).

The average number of sessions required for clearance of pigmentation was 2.5. Table 4 depicts the average number of sessions for each subtype of lip pigmentation. No scarring was seen. One patient had hypopigmentation in the adjacent area following laser treatment for upper lip pigmentation [Figure 7]. The level of patient satisfaction following therapeutic intervention is shown in Table 5.

DISCUSSION

Lips being one of the key aesthetic units of the face play a significant role in phonation, swallowing, and beauty of the face. The reddish color of vermilion zone of the

Table 1: Objective and subjective assessment

Objective assessment		Subjective assessment
Grading of pigmentation	Grading of clinical response	Patient satisfaction score
0—no pigmentation	Grade 0: no response	0—not satisfied
1—solitary pigmented spot	Grade 1: mild response (1%–25%)	1—satisfied
2—multiple pigmented spots	Grade 2: moderate response (26%–50%)	2—extremely satisfied
3—diffuse pigmentation	Grade 3: good response (51%–75%)	
	Grade 4: excellent response (>75%)	

Table 2: Type of lip pigmentation

Type of lip pigmentation	Number of patients
Diffuse pigmentation	8
Focal pigmentation	
Ephelides	5
Labial melanotic macule	3
Post-inflammatory hyperpigmentation	
Secondary to herpes simplex infection	3
Fixed drug eruption	1

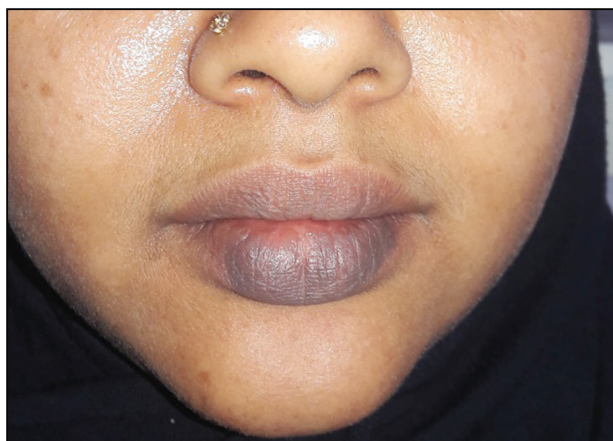

Figure 1: Diffuse pigmentation of lower lip

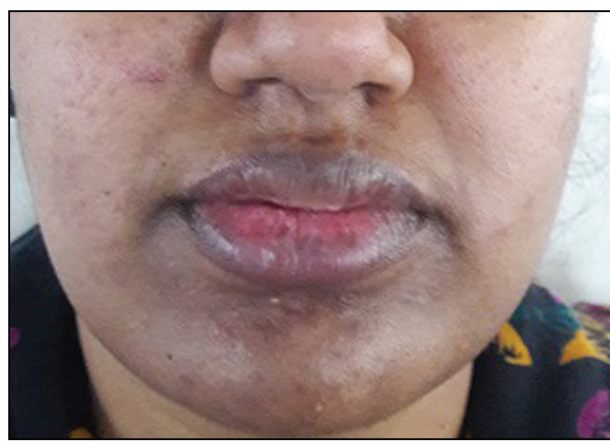

Figure 3: Diffuse pigmentation of lips (before treatment)

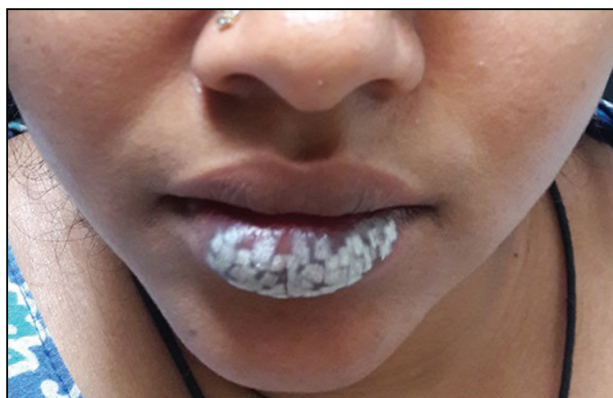


Figure 2: Immediate whitening of the lesion after laser

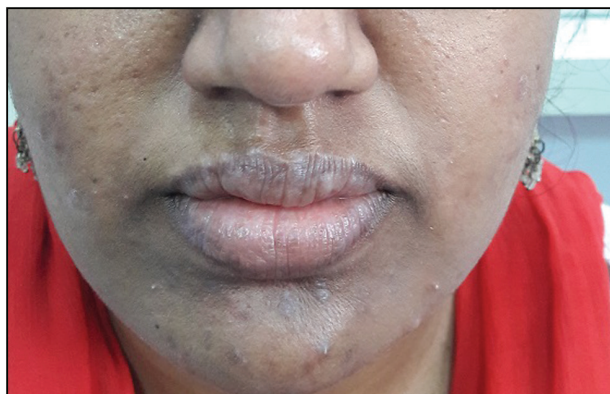

Figure 4: Reduction in pigmentation of lips after five sessions of laser

Table 3: Percentage of pigment reduction			
Pigment reduction	Number of patients	Percentage	P Value
Excellent	7	35	0.00
Good	7	35	
Moderate	2	10	
Mild	2	10	
Recurrence	2	10	

lips is due to high vascularity and paucity of melanocytes. Vermilion zone consists of nonkeratinized stratified squamous epithelium; three to five layers thick and lacks hair follicles, sweat glands, sebaceous glands, and salivary glands.^[2] Variation in physiological pigmentation of the lips is genetically determined unless associated with some underlying disease.

Dark lips are a very common condition among Asians, yet difficult to treat. There is dearth of data regarding management of lip pigmentation. Results with topical treatment are often unsatisfactory. Pigmentary lasers such as Q-switched Ruby laser, Q-switched Alexandrite laser, and Q-switched Nd:YAG laser have been used for treating pigmentary lesions of oral mucosa.

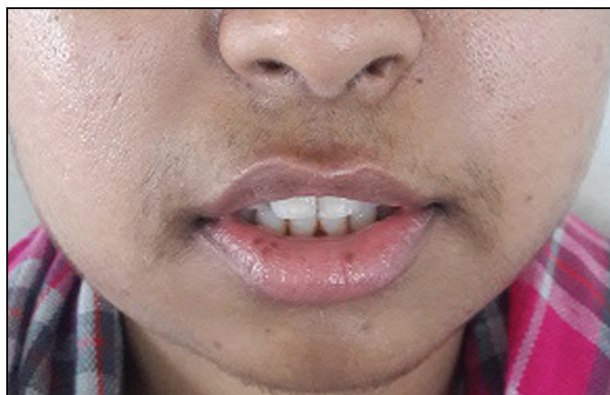

Figure 5: Focal pigmentation of lower lip (before treatment)

In this study, we used 532-nm Q-switched Nd:YAG laser for treating lip pigmentation. Light energy emitted by laser is absorbed by the chromophore melanin. This causes rapid heating of melanosomes, thereby creating a sharp temperature gradient between the melanosome and its surrounding structures. This gradient leads to thermal expansion, generation, and propagation of acoustic waves, which damage the melanocytes causing pigment reduction.^[3]

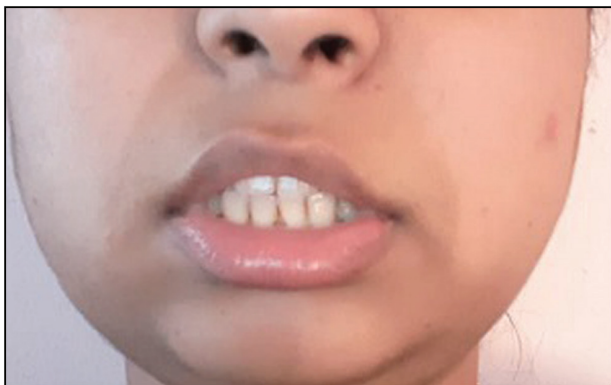


Figure 6: Complete clearance of pigmentation after one session of laser

Table 4: Average number of sessions for each subtype of lip pigmentation

Type of lip pigmentation	Average number of sessions
Ephelides	2
Labial melanotic macule	2.1
Post-inflammatory hyperpigmentation	3
Diffuse pigmentation	4.2

In a case series by Hanada *et al.*^[4] six patients with labial lentigo were treated with short-pulsed non-Q-switched ruby laser. Complete lesion clearance was seen with no recurrence after 3 months follow-up. Individual case report by Shetty *et al.*^[5] showed clinical improvement in smoker's lip with 1064-nm Q-switched Nd:YAG laser in a single session.

Ge *et al.*^[6] used 532-nm Q-switched Nd:YAG laser in 11 patients for labial lentiginos in Peutz–Jegher's syndrome. The study showed clearance of pigmentation in two to six sessions. In total, 72.7% patients showed an excellent response whereas (27.3%) had a good response with no recurrence.

In a case study by Ashinoff *et al.*^[7] three patients with labial lentigos were treated with Q-switched Ruby laser. Fluence of 10 J/cm² was used and clearing of pigmentation was seen after 2 sessions. Gupta *et al.*^[8] in their study showed improvement in labial melanotic macules with 1–2 sessions of Q-switched Ruby laser. No side effects were reported and there was no recurrence.

Xi *et al.*^[9] used Q-switched Alexandrite laser for treating labial lentiginos in 14 patients with Peutz–Jegher's syndrome. Clearance of pigmentation was seen in a single session. Side effects noted were grayish patches, erythema, edema, and bleeding. No recurrence was seen.

Li *et al.*^[10] in their study showed the efficacy of Q-switched alexandrite laser in 43 patients with facial and labial lentiginos associated with Peutz–Jegher's syndrome. Improvement in pigmentation was seen with 3 sessions, 55.8% of the patients had excellent results and 44.2% showed good results. No complications were seen.

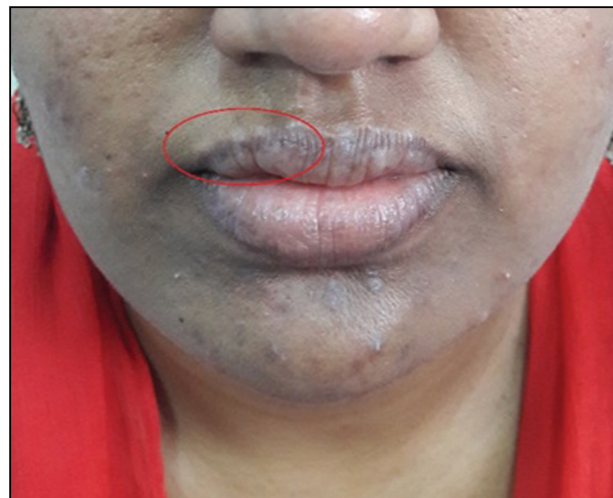

Figure 7: Hypopigmentation in the adjacent area following laser treatment of upper lip

Table 5: Patient satisfaction

Patient satisfaction	Number of patients	Percentage
Not satisfied	5	25
Satisfied	7	35
Extremely satisfied	8	40

In a study conducted by Kunachak *et al.*^[11] seventy patients with dark lips were treated with 532-nm Q-switched Nd:YAG laser. Complete pigment clearance was seen after an average of 2.5 sessions in congenital cases, 2.2 sessions in acquired cases, and 1.8 sessions in cases with uncertain cause. No adverse effects were seen in this study. The only complication was reactivation of herpes labialis following laser treatment in one of the patients. One patient had recurrence. Patients had used topical hydroquinone 4%–6% before laser treatment without any improvement.

In our study, 35% of the patients showed an excellent response with more than 75% of pigment clearance. Improvement in pigmentation was noted after an average of 2 sessions in ephelides, 2.1 sessions in labial melanotic macule, 3 sessions in post-inflammatory hyperpigmentation, and 4.2 sessions in diffuse pigmentation. Recurrence was seen in two patients. The only complication noted was hypopigmentation in the surrounding area of upper lip following laser treatment in one patient.

Laser treatment for lip pigmentation is safe, effective, and gives rapid clinical response. Drawback of this treatment is the cost factor. The limitation of our study is the small sample size and shorter duration of follow-up.

CONCLUSION

532-nm Q-switched Nd:YAG laser is safe and effective in the management of lip pigmentation and gives rapid results.

Declaration of patient consent

The authors certify that they have obtained all appropriate patient consent forms. In the form the patient(s) has/have given his/her/their consent for his/her/their images and other clinical information to be reported in the journal. The patients understand that their names and initials will not be published and due efforts will be made to conceal their identity, but anonymity cannot be guaranteed.

Financial support and sponsorship

Nil.

Conflicts of interest

There are no conflicts of interest.

REFERENCES

1. Vachiramon V, McMichael AJ. Approaches to the evaluation of lip hyperpigmentation. *Int J Dermatol* 2012;51:761-70.
2. Piccinin MA, Zito PM. Anatomy, head and neck, lips [Updated 2020 Aug 10]. In: StatPearls [Internet]. Treasure Island, FL: StatPearls Publishing; 2021. Available from: <https://www.ncbi.nlm.nih.gov/books/NBK507900/> [Last accessed on 2021 Jun 22].
3. Ara G, Anderson RR, Mandel KG, Ottesen M, Oseroff AR. Irradiation of pigmented melanoma cells with high intensity pulsed radiation generates acoustic waves and kills cells. *Lasers Surg Med* 1990;10:52-9.
4. Hanada K, Baba T, Sasaki C, Hashimoto I. Successful treatment of mucosal melanosis of the lip with normal pulsed ruby laser. *J Dermatol* 1996;23:263-6.
5. Shetty S, Pai S. Aesthetic correction of smoker's lip using 1064 nm Q-switched neodymium-doped yttrium aluminium garnet laser. *J Cutan Aesthet Surg* 2017;10:118-9.
6. Ge Y, Jia G, Lin T. Q-switched nd:YAG laser treatment for labial lentigines associated with Peutz-Jeghers syndrome. *J Dtsch Dermatol Ges* 2015;13:551-5.
7. Ashinoff R, Geronemus RG. Q-switched ruby laser treatment of labial lentigos. *J Am Acad Dermatol* 1992;27:809-11.
8. Gupta G, MacKay IR, MacKie RM. Q-switched ruby laser in the treatment of labial melanotic macules. *Lasers Surg Med* 1999;25:219-22.
9. Xi Z, Hui Q, Zhong L. Q-switched alexandrite laser treatment of oral labial lentigines in Chinese subjects with Peutz-Jeghers syndrome. *Dermatol Surg* 2009;35:1084-8.
10. Li Y, Tong X, Yang J, Yang L, Tao J, Tu Y. Q-switched alexandrite laser treatment of facial and labial lentigines associated with Peutz-Jeghers syndrome. *Photodermatol Photoimmunol Photomed* 2012;28:196-9.
11. Kunachak S, Kunachakr S, Kunachakr S, Leelaudomlipi P, Wongwaisayawan S. An effective treatment of dark lip by frequency-doubled Q-switched nd:YAG laser. *Dermatol Surg* 2001;27:37-40.