

A Histological and Clinical Evaluation of Plasma as a Graft-holding Solution and Its Efficacy in Terms of Hair Growth and Graft Survival

Anil K. Garg, Seema Garg¹

Rejuvenate Hair Transplant, Indore, Madhya Pradesh, India, ¹Diplomate of American Board of hair Restoration, Rejuvenate hair transplant centre, Indore, India

Abstract

Background: There is a time lag between hair follicle harvesting and implantation; during this time, hair follicles have ischemic injury. We need a holding media or a solution to minimize or neutralize ischemic injury. **Aim and Objectives:** The aim of this study was to evaluate plasma as a graft-holding solution in terms of its efficacy in hair growth and hair graft survival. **Materials and Methods:** A split-scalp study was carried out. The left side was designated as the control area (Group A), where graft implanted was kept in Ringer's lactate (RL), and the right side behaved as the test area (Group B), which received grafts preserved in autologous plasma. The *P* value was calculated. **Observations:** MTT [3-(4,5-Dimethylthiazol-2-Yl)-2,5-Diphenyltetrazolium Bromide] staining for graft stored in RL at 12–72h showed poor hair follicles cells survival, whereas graft kept in plasma showed viable cells even after 72h. The hair count and density in plasma group were significantly higher than the RL group. There was an improvement in hair thickness in both groups from 6 to 12 months. **Conclusion:** Autologous plasma is an easily available graft-holding solution. Platelets along with the plasma provide multiple growth factors promoting epithelialization, neovascularization, and action on hair follicle stem cells to improve growth. The fibrin coating around graft makes it sticky and prevents dehydration. The split-scalp controlled study certainly shows the advantages of using plasma over other extracellular graft-holding solutions.

Keywords: Anagen effluvium, autologous plasma, fibrin scaffold, graft-holding solutions, ischemic injury

INTRODUCTION

The surgical trauma of hair transplantation triggers inflammation, which is the first step in wound healing. The brunt of the biochemical changes has to be borne by the newly transferred grafts, which are devoid of any blood supply. Graft survival is affected by a cascade of multiple factors including graft harvesting, dissection, manipulation during implantation, and ischemia or reperfusion injury, following implantation in the body. The insults inflicted from these unfavorable factors add up leading to apoptosis, which affects graft survival and the quality of hair regrowth. To achieve the best results, we should focus on improving all the aforementioned factors.

Grafts harvested and maintained out of the scalp are preserved in a holding solution until they are implanted. Thus, the holding solution plays a crucial role in the hair

transplant procedure. An ideal holding solution should have the same osmolality as of the grafts cells, should prevent acidosis, provide energy to the cells, and prevent the release of free radicals. There are two types of holding solutions, extracellular and intracellular. Examples of extracellular solutions are normal saline, Ringer's lactate (RL), and plasma-like fluid. The intracellular solutions are represented by hypothermosal. Extracellular holding solutions do not require chilling, which causes sodium pump failure leading to swelling of the cells, whereas intracellular holding solutions require chilling.^[1]

Address for correspondence: Dr. Anil K. Garg,
Rejuvenate Hair Transplant, R. S. Bhandari Marg,
Janjeerwala Square, Indore 452001,
Madhya Pradesh, India.
E-mail: anilgarg.com

This is an open access journal, and articles are distributed under the terms of the Creative Commons Attribution-NonCommercial-ShareAlike 4.0 License, which allows others to remix, tweak, and build upon the work non-commercially, as long as appropriate credit is given and the new creations are licensed under the identical terms.

For reprints contact: reprints@medknow.com

How to cite this article: Garg AK, Garg S. A histological and clinical evaluation of plasma as a graft-holding solution and its efficacy in terms of hair growth and graft survival. *J Cutan Aesthet Surg* 2020;13:50-6.

Access this article online

Quick Response Code:



Website:
www.jcasonline.com

DOI:
10.4103/JCAS.JCAS_97_19

At our center, we use autologous plasma with platelets as a graft-holding solution during hair transplantation surgery. Clinical results have been evaluated with TrichoScan analysis and supported by histological evaluation for graft viability. There is literature advocating the use of platelet-rich plasma to promote hair growth, based on the logic that platelets have growth factors that stimulate the stem cells of hair follicles.^[2]

Aim and objectives

The aim of this study was to evaluate plasma as a graft-holding solution in terms of its efficacy in hair growth and hair graft survival.

MATERIALS AND METHODS

A split-scalp study was carried out by comparing hair grafts transplanted on the right and left frontotemporal areas selected as recipient sites in the same patient. The left side was designated as the control area (Group A) and the right side behaved as the test area (Group B), for comparison of the results. Right frontotemporal area received grafts preserved in autologous plasma, whereas the left frontotemporal area received grafts preserved in RL. Both sides were implanted with grafts harvested with the same technique, with equal number of grafts of the same quality, and with the same implantation time. Grafts on both sides were implanted by two surgeons sharing similar experience and expertise using optical loupes for magnification.

The autologous plasma as well as the RL-holding solutions with the grafts was maintained at a temperature of around $12^{\circ}\text{C} \pm 2^{\circ}\text{C}$, whereas the room temperature was maintained around 18°C .

The following parameters were taken into consideration for the study:

1. A histological study with MTT, 3-(4,5-dimethylthiazol-2-yl)-2,5-diphenyltetrazolium bromide, stain (a colorimetric assay for assessing cell metabolic activity) in order to confirm the viability of cells in the grafts at 12–72 h.
2. Periodical postoperative patient follow-up with regular photographs and TrichoScan evaluations to identify any event of anagen effluvium due to postsurgical shock loss.
3. TrichoScan study for hair density was carried out at three months for hair growth.
4. Hair thickness was assessed at 6 and 12 months for the quality of hair growth.

Preparation of autologous plasma

Preparation of autologous plasma was the first step before commencing the hair transplant [Figure 1]. We collected 23 cc of blood from the patient in a syringe with 2 cc acid citrate dextrose solution as an anticoagulant. The

blood was transferred to a high-quality glass container designed by the author. The blood was centrifuged in a temperature-controlled (19°C) centrifuge machine at 5000 rpm (rotations per minute) for 16 min. The process resulted in the separation of red blood cells at the bottom of the tube and plasma with platelets forming the upper fluid compartment. The 23 cc of blood yielded approximately 12 cc of plasma. Hence, we can deduce that the platelet concentration was twice the normal levels. The lab further confirmed the platelet count ranging between 4 and 500,000 /mm³. The plasma thus created was stored in a sterile stainless steel bowl (a Petri dish can also be used), maintaining a temperature of $12^{\circ}\text{C} \pm 2^{\circ}\text{C}$ on a cool gel pack ready to receive the grafts.

The harvested grafts were divided randomly into two groups, with an equal number of grafts per side. Control Group A grafts were stored in RL and test Group B grafts were stored in plasma. The temperature of both graft-holding solutions was maintained as the same.

Grafts dipped in plasma form a very loose clump. A trained assistant separates the individual graft from a small clump and places it on surgeon's hand to implant.

Six volunteer patients having similar grades of male pattern baldness were included in the study, with ages between 25 and 40 years. Grafts were implanted over the bilateral frontotemporal areas as planned. Grafts stored in plasma were implanted on right frontotemporal side, whereas the grafts stored in RL were implanted on the left frontotemporal side. The same number of grafts was implanted with a standard density of 40 grafts/cm². Routine postoperative care of the donor and the recipient area was followed as per general guidelines for all hair transplant patients. The study was conducted as follows:

1. The graft samples A and B were sent for MTT staining at 12 and 72 h of graft-holding time in order to determine viability of the cells.
2. Patient follow-ups were conducted at 1, 2, 3, 4, 6, and 12 months after hair transplant.
3. Photographs were taken for comparison of left and right frontotemporal areas with and without flash.
4. Hair count and density were obtained on both sides using TrichoScan.
5. At the 6- and 12-month follow-up, photographs and TrichoScan for hair thickness were repeated for evaluation of terminal hair.

Observations

Observation of MTT staining

1. MTT-staining at 12 h: Grafts stored in RL showed poor staining, whereas the grafts stored in plasma-holding solution were well stained, indicating good cell viability in the plasma group when compared to RL group.

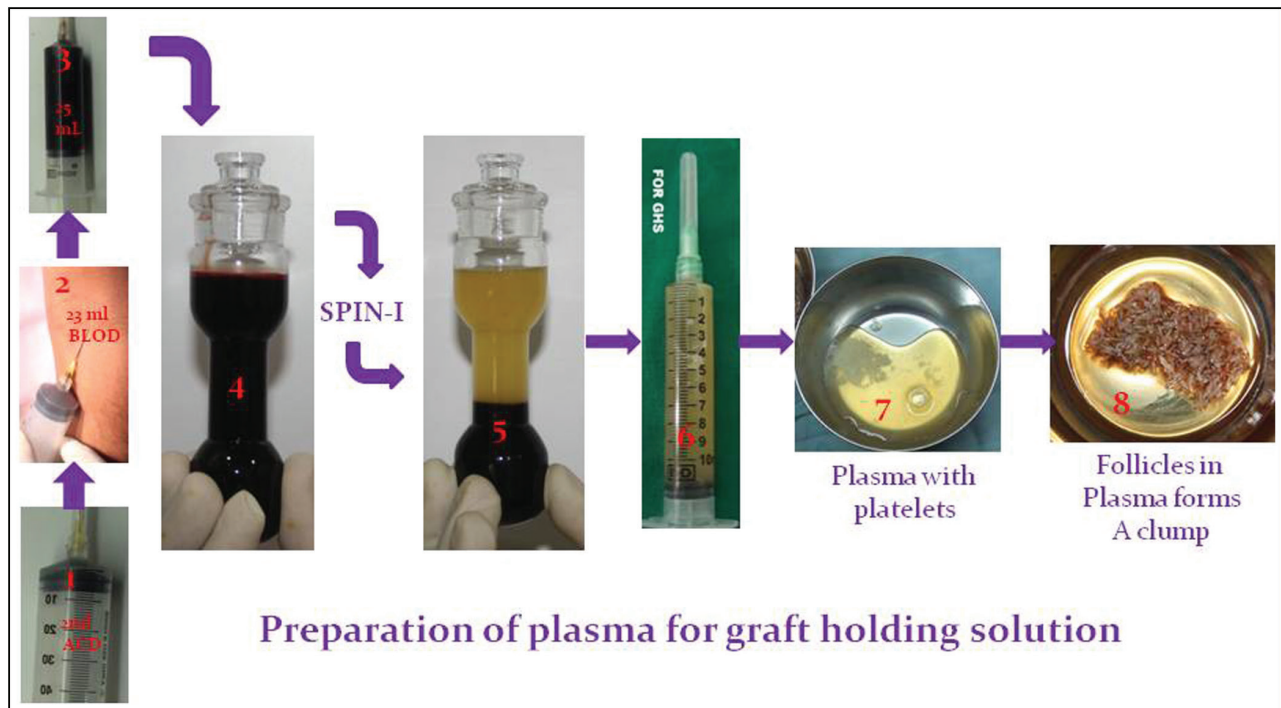


Figure 1: Method of preparation of plasma for graft-holding solution

2. MTT-staining at 72 h [Figures 2-5]: Grafts stored in plasma showed good staining, whereas very poor staining of grafts of RL group was observed.

TrichoScan study

1. For thickness at three months:
TrichoScan study carried out at three months for the hair count on RL side was average 1.3 (density 4.4 g/cm²), whereas on plasma side, the average hair count was 8.3 (density 27.5 g/cm²). Thus the plasma side had 68.75% hair growth, whereas on RL side, only 11% hair growth. The hair count and density in plasma group were significantly higher than the RL group.
2. TrichoScan study for hair thickness
The hair thickness measured at six months by TrichoScan showed average of 53.5 μmm on RL side, whereas on plasma side, it was 65.66 μmm, which was significantly higher. At the 12-month follow-up, the hair thickness measured 60.6 μmm on the RL side, whereas on the plasma side, it was 66.125 μmm. Details are mentioned in Figure

Clinical evaluation

Photographs of the right and left frontotemporal areas were taken at 50 and 120 days after hair transplant for the evaluation of hair growth and anagen effluvium.

At 50 days [Figure 8], on test side (plasma side), implanted hair was present, whereas on the control side (RL), most of the implanted hairs were lost as they underwent anagen effluvium. Photograph [Figure 9] taken at 120 days showed the difference in hair quality and density on left and right frontotemporal region.

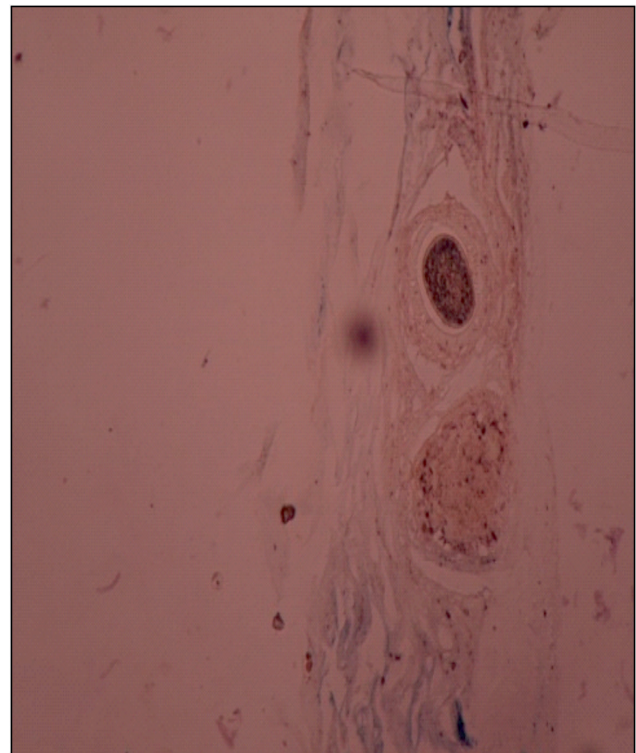


Figure 2: MTT staining 12h medium A Ringer

DISCUSSION

The most important benefit of an optimum graft-holding solution would be an increase in hair yield from the transplanted grafts. The optimum holding solution would reduce the damage from reperfusion injury and free radical

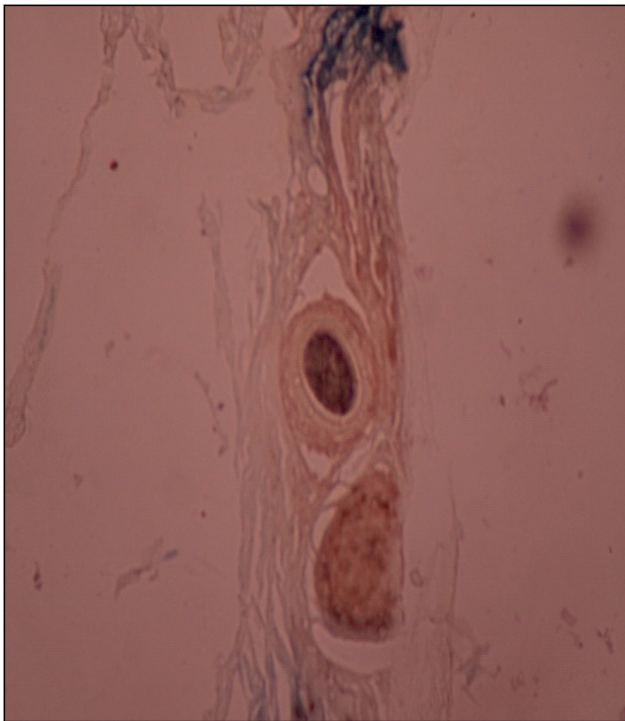


Figure 3: MTT staining 12h medium B plasma

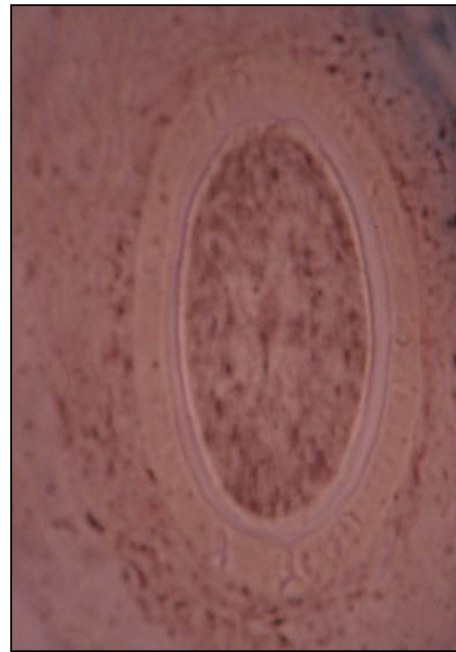


Figure 5: MTT staining 72h medium B plasma

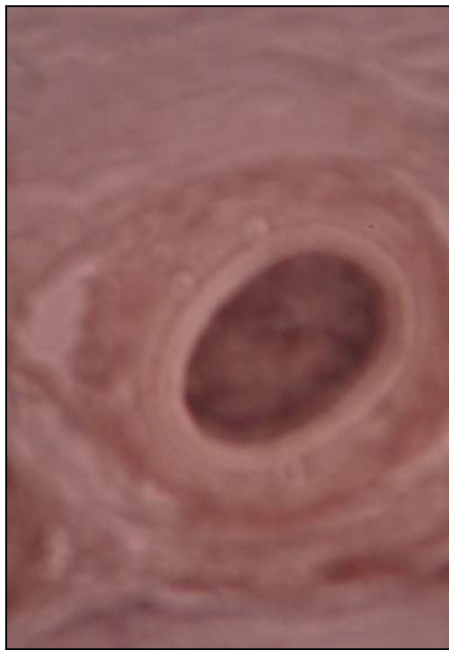


Figure 4: MTT staining 72h medium A Ringer

formation as well as from ionic imbalance and variation in osmolality created by the ischemic phase.

Holding solutions are formulated according to the composition of intracellular and extracellular body fluid environment, and they behave differently. An intracellular graft-holding solution needs chilling, which is not user-friendly. They also do not assure protection from reperfusion injury^[3] and are expensive. Extracellular

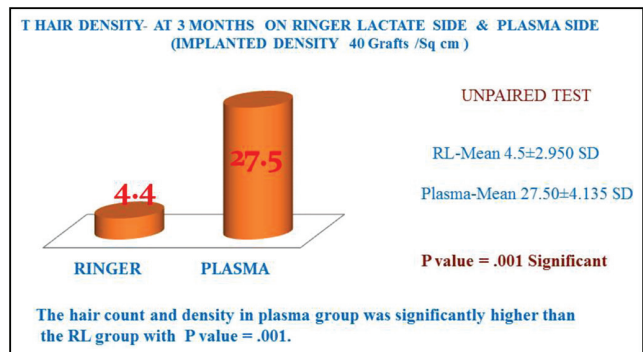


Figure 6: Hair density comparison in control and test group

solutions are widely used, economical, and do not need chilling. Intracellular fluids such as hypothermosal with adenocine tri phosphatase added have significant benefits when graft-holding time is more than 10h; however, this is a very rare situation as most hair transplant procedures are completed within 4–6h.

Autologous plasma is an extracellular fluid, which is isotonic with nutrients and platelet-derived growth factors. It is cost-effective and can be prepared by a surgeon or a pathologist. Drying and desiccation of grafts immersed in plasma is delayed, grafts look shiny and more hydrated even at the end of 4h holding time. Uebel^[2] and Uebel *et al.*^[4] in their studies had implanted grafts after dipping in plasma and reported 5%–53% increase in hair count after seven months of hair transplant.

MTT (3-(4,5-dimethylthiazol-2-yl)-2,5-diphenyltetrazolium bromide) assay:

The MTT assay is a colorimetric assay for assessing cell metabolic activity. Nicotinamide adenine dinucleotide

phosphate oxidase-dependent cellular oxidoreductase enzymes reflect the number of viable cells present under defined conditions. These enzymes are capable of reducing the tetrazolium dye MTT to its insoluble formazan.^[9] Therefore, the dye can detect metabolically active live cells. In our study, samples of hair follicle grafts were sent for MTT histological assay in order to detect live cells. Results of staining showed that at 12 h, the plasma grafts were better stained than the RL grafts. Results at 72-h staining were surprising. Plasma grafts showed good staining, whereas RL grafts showed very poor staining, indicating that the cells were viable in plasma grafts even at the end of 72 h.

TrichoScan study carried out at three months for the hair count on RL side was average 1.3 (density 4.4g/cm²), whereas on plasma side, the average hair count was 8.3 (density 27.5g/cm²). Thus, the plasma side had 68.75% hair growth, whereas the RL side had only 11% hair growth. The unpaired test showed RL mean, 4.5 ± 2.950 (standard deviation [SD]) and plasma mean, 27.50 ± 4.135 SD with a *P* < 0.001, which is significant. This indicates that anagen effluvium on plasma side was 31.25%, whereas on RL side, the effluvium was 89.00%. This shows that anagen effluvium was controlled by 58.75%, which is significant (*P* < 0.001).

In the first seven days after hair transplantation, there is a period of inflammatory response (involving neutrophils, eosinophils, macrophages, platelets, fibroblasts, and growth factors^[2]) in which both erythema and edema occur followed by apoptosis, and the grafted as well the existing hair follicles may enter into an involution phase resulting in hair shedding. This process is triggered and propagated due to ischemia. The follicles become refractory and those that survive will regrow at the stimulus of next growth cycle, which begins after the third month and continues up to seven months. Prevention of anagen effluvium can be achieved with the prevention of apoptosis of the more metabolically active progeny of the stem cells. This observation may help us in the development of an ideal holding solution by further bioenhancement of platelet and plasma solution.

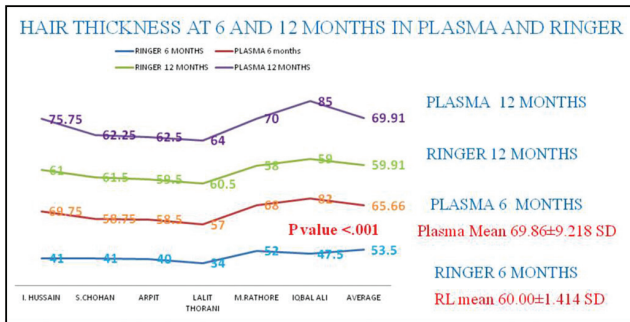


Figure 7: Hair thickness in both groups at 6 and 12 months were compared. There was an improvement in hair thickness in both groups from 6 to 12 months with *P* value of 0.002

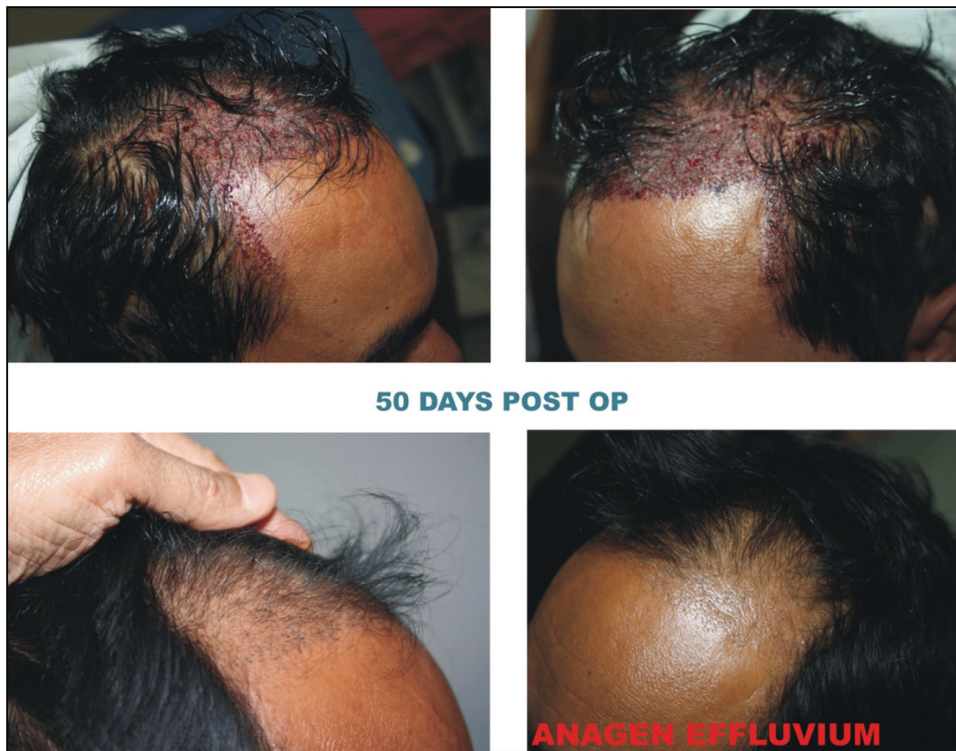

Figure 8: After 50 days of hair transplant. After 50 days of hair transplant, significant anagen effluvium present on Ringer's lactate side, whereas on plasma side, implanted hair was still present

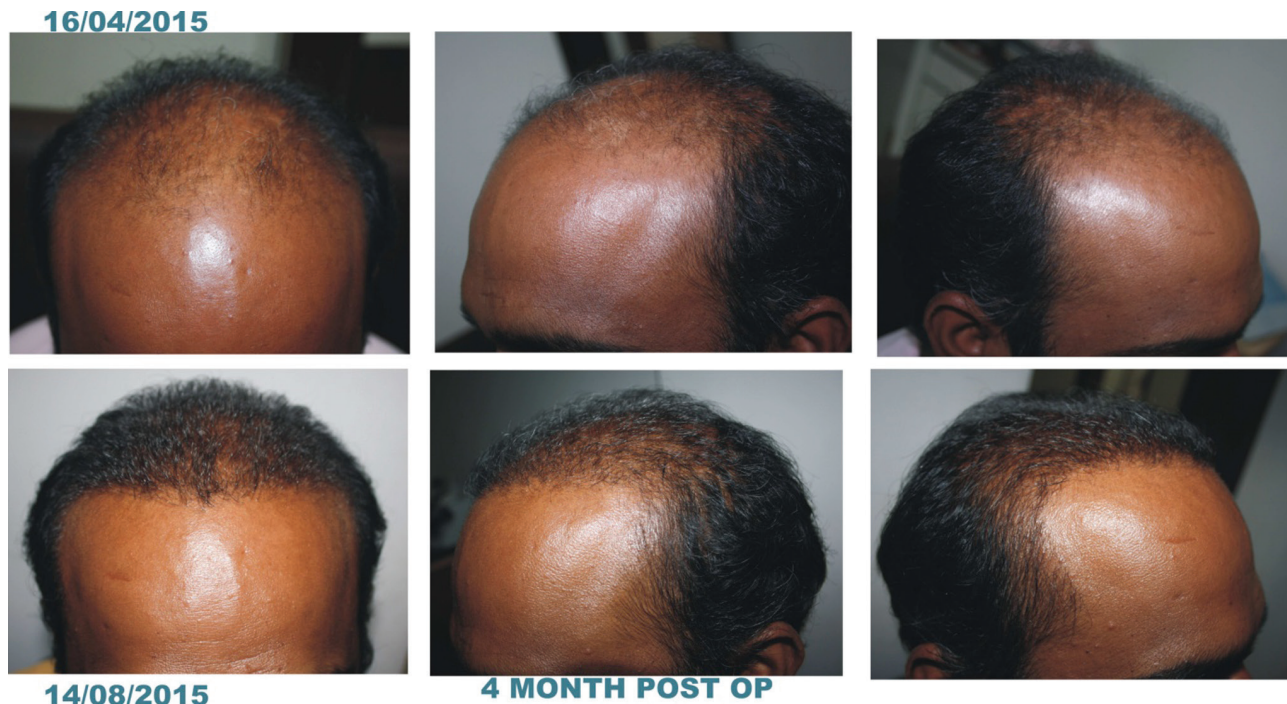

Figure 9: Patient photographs after four months showing hair growth difference on left and right frontotemporal region

The hair thickness measured at six months by TrichoScan showed average of 53.5 μm on RL side, whereas on plasma side, it was 65.66 μm , which was significantly higher. The unpaired test showed group RL mean 53.5 \pm 6.377 SD and group plasma mean 65.67 \pm 9.688 SD. $P < 0.001$ was very significant [Figure 6].

At the 12-month follow-up, the hair thickness measured 60.6 μm on the RL side, whereas on the plasma side, it was 66.125 μm . The thickness of hair on the RL side increased by 12 months but was still less than that on the plasma side. The unpaired test showed group RL mean 60.00 \pm 1.414 SD and group plasma mean 69.86 \pm 9.218 SD, $P < 0.001$ was very significant.

Hair diameter depends on a number of viable cells in the matrix. These are the mesodermal stem cells known to be very sensitive to ischemia. Ischemia leads to accumulation of free radicals and anaerobic metabolic pathways, resulting in the apoptosis of cells, thereby affecting hair thickness. The hair thickness on plasma graft side was better than RL side. This may be because of the effect of multiple beneficial factors in the plasma-holding solution.^[6]

Platelets are activated on contact with collagen around hair follicles, resulting in the release of various platelet-derived growth factors.^[7,8] Fibrinogen in plasma gets converted to fibrin, which forms a mesh^[9,10] in which platelets are trapped. This fibrin mesh with activated platelets forms a three-dimensional fibrin scaffold. Platelet-rich fibrin was first described by Choukroun *et al.* in France.^[11,12] Fibrin glue along with skeletal myoblasts in the fibrin scaffold preserve cardiac function after myocardial infarction.^[13]

In vitro prefabrication of human cartilage is created in shapes using fibrin glue and human chondrocytes.^[13] Long-term regeneration of human epidermis is achieved on third-degree burns transplanted with autologous cultured epithelium grown on a fibrin matrix.^[14] There is a definite role of the fibrin matrix in angiogenesis.^[15]

CONCLUSION

Autologous plasma is an easily available graft-holding solution. It is isotonic in nature having nutrient growth factors as well as the advantage of fibrin. Platelets along with the plasma provide multiple growth factors promoting epithelialization, neovascularization, and action on hair follicle stem cells to improve growth. The fibrin coating around graft makes it sticky and prevents dehydration. The growth factors and nutrients successfully prevent the anagen effluvium and shock loss post hair transplant. The thickness of hair and yield of the graft are also better in plasma. The split-scalp controlled study certainly shows the advantages of using plasma over other extracellular graft-holding solutions. At the same time, it is not an ideal graft-holding solution where chilling cannot be carried out and the availability of energy source is not clear. But this can be developed as an ideal graft-holding solution by some innovative bioenhancement.

Declaration of patient consent

The authors certify that they have obtained all appropriate patient consent forms. In the form the patient(s) has/have given his/her/their consent for his/her/their images and other clinical information to be reported in the journal. The patients understand that

their names and initials will not be published and due efforts will be made to conceal their identity, but anonymity cannot be guaranteed.

Financial support and sponsorship

Nil.

Conflicts of interest

There are no conflicts of interest.

REFERENCES

1. Cole JP. Internet website posting. Available from: <https://www.forhair.com/optimal-holding-solution-and-temperature-for-hair-follicle/>. [Last accessed on 2017 March 01].
2. Uebel CO. A new advance in baldness surgery using platelet-derived growth factor. *Hair Transplant Forum Int* 2005;15:77-84.
3. Cooley J. Ischemia reperfusion injury and graft storage solutions. *Hair Transplant Forum Intl* 2004;13:121.
4. Uebel CO, da Silva JB, Cantarelli D, Martins P. The role of platelet plasma growth factors in male pattern baldness surgery. *Plast Reconstr Surg* 2006;118:1458-66.
5. Wikipedia. MTT assay. Available from: https://en.wikipedia.org/wiki/MTT_assay. [Last accessed on 2019 August 02].
6. Garg A, Garg S. A histological and clinical evaluation of plasma as a graft holding solution and its efficacy in terms of hair growth and graft survival. Paper presented at the annual scientific meeting of the ISHRS. Las Vegas, California, 2016.
7. Yun SH, Sim EH, Goh RY, Park JI, Han JY. Platelet activation: the mechanisms and potential biomarkers. *Biomed Res Int* 2016;2016:9060143. Epub 2016 Jun 15.
8. Platelet Activation. Available from: https://www.google.com/url?sa=t&rct=j&q=&esrc=s&source=web&cd=1&ved=2ahUKewjsmvOM7PfkAhU-7XMBHbP6D_4QFjAAegQIABAB&url=https%3A%2F%2Fwww.washington.edu%2Fnews%2F2019%2F03%2F13%2Fnew-method-to-assess-platelet-health%2F&usg=AOvVaw0HWV KJQth0D4S9joVvPQYz. [Last assessed 2019 March 19].
9. Miao Y, Sun YB, Sun XJ, Du BJ, Jian JD, Hu ZQ. Promotional effect of platelet rich plasma on hair follicle reconstitution *in vivo*. *Dermatol Surg* 2013;39:1868-76.
10. Joseph G. Preliminary experience and extended applications for the use of autologous platelet rich plasma in hair transplantation surgery. *Hair Transplant Forum Int* 2007;17:131-2.
11. Choukroun J, Diss A, Simonpieri A, Girard MO, Schoeffler C, Dohan SL, *et al*. Platelet-rich fibrin (PRF): a second generation platelet concentrate. Part I: technological concepts and evolution. *Oral Surg Oral Med Oral Pathol Oral Radiol Endod* 2006;101:E37-44.
12. Sunitha Raja V, Munirathnam Naidu E. Platelet-rich fibrin: evolution of a second-generation platelet concentrate. *Indian J Dent Res* 2008;19:42-6.
13. Christman KL, Fok HH, Sievers RE, Fang Q, Lee RJ. Fibrin glue alone and skeletal myoblasts in a fibrin scaffold preserve cardiac function after myocardial infarction. *Tissue Eng* 2004;1:403-9.
14. Ting V, Sims CD, Brecht LE, McCarthy JG, Kasabian AK, Connelly PR, *et al*. In vitro prefabrication of human cartilage shapes using fibrin glue and human chondrocytes. *Ann Plast Surg* 1998;40:420-1.
15. Van Hinsbergh VW, Collen A, Koolwijk P. Role of fibrin matrix in angiogenesis. *Ann N Y Acad Sci* 2001;936:426-37.