



Case Series

Eyebrow reconstruction by simple elliptical excision with beveled incision – A case series of twelve patients

Yogesh M. Bhingradia¹ , Akshay Arun Vetal² , Heena Singdia³ , Aarushi Kinjalk⁴

¹Department of Dermatology, Venereology and Leprosy, Shivani Skin Care and Cosmetic Clinic, Surat, Gujarat, ²Department of Skin and VD, Lokmanya Tilak Municipal Medical College, Mumbai, Maharashtra, ³Department of Skin and VD, Sawai Man Singh Medical College, Jaipur, Rajasthan, ⁴Shivani Skin Clinic, Surat, Gujarat, India.

***Corresponding author:**

Yogesh M. Bhingradia,
Department of Dermatology,
Venereology and Leprosy,
Shivani Skin Care and Cosmetic
Clinic, Surat, Gujarat, India.

yogeshbhingradia@gmail.com

Received: 08 October 2022
Accepted: 14 January 2023
Epub Ahead of Print: 11 October 2024
Published: 21 October 2024

DOI
10.25259/jcas_189_22

Quick Response Code:



ABSTRACT

Patients seeking reconstructive facial surgery desire aesthetically pleasing outcomes with minimal visible scarring. For scalp incisions, beveled angle of 45° is typically preferred to preserve hair follicles. However, no consensus exists regarding the ideal incision angle for the brow area. This observational study analyzed the surgical outcomes of 12 patients with eyebrow defects treated using a simple elliptical excision with a beveled incision, addressing various indications such as posttraumatic scars, post-burn scars, and tumors. Outcomes were evaluated using the Physician Global Esthetic Improvement Scale at 7 days and 3 months post-surgery. At 7 days, 50% of patients showed very good improvement, and the other 50% showed moderate improvement. By 3 months, 33% of patients exhibited exceptional improvement, 50% showed very good improvement, and 17% demonstrated moderate improvement. This study concludes that direct excision and approximation with an angled incision along the hair follicle direction provide favorable aesthetic results for eyebrow reconstruction.

Keywords: Beveled incision, Eyebrow reconstruction, Post traumatic scar revision

INTRODUCTION

Eyebrows play an important role in human face recognition, eyebrows may serve as high-contrast lines that give the appearance of the brow greater clarity and emphasis, and their associated musculature allows for sophisticated, often involuntary gestures that may be discerned from a relatively large distance.¹ Eyebrows have important functions concerning facial recognition, sexual dimorphism, facial expression, and facial esthetics. Eyebrow defects are caused by trauma, burns, and excision of tumors. Esthetically unappealing eyebrow scars, for which treatment can sometimes be challenging, although it is with several options. There are various scar revision methods such as direct approximation, advancement flaps (Z-plasty, A-T, O-T, O-H, O-U, and O-L flaps), rotation flaps, skin grafts, tissue expansion, and microvascular transfer.^{2,3} These choices vary from patient to patient and must be carefully considered on a case-to-case basis by a dermatosurgeon. Hence, a proper way of scar reconstruction along with experience, and meticulous planning helps in achieving the best surgical outcome. Hence, this article will pose an overview of eyebrow reconstruction techniques with esthetically best outcomes and retaining the normal eyebrow hairline.

This is an open-access article distributed under the terms of the Creative Commons Attribution-Non Commercial-Share Alike 4.0 License, which allows others to remix, transform, and build upon the work non-commercially, as long as the author is credited and the new creations are licensed under the identical terms.

©2024 Published by Scientific Scholar on behalf of Journal of Cutaneous and Aesthetic Surgery

Aim of study

The study aims to study the surgical outcome of eyebrow reconstruction by simple elliptical excision with beveled incision.

CASE SERIES

Material and methods

Our study is an observational study conducted in a private skin and hair clinic in Western India for 2 years from 2019 to 2021. A total of 12 patients with eyebrow defects were treated with simple elliptical excision and direct approximation. The objectives and purpose of the study were explained to all patients, in their preferred language. After obtaining consent, a detailed history, clinical examination pertaining to the aim of the study, and clinical photographs as per international standards were recorded in a specially performed format designed for this study. Patients were also subjected to evaluation of defects such as scar and tumor properties which are essential before reconstruction. It includes visual, tactile, and sensory assessments. Visual assessments consist of scar color, height, and surface appearance, whereas sensory assessments include itching and pain, which represent scar instability.⁴ Tactile assessments include elasticity and pliability, with good pliability regarded as smooth movements of scars in various directions and good elasticity as the scar being more than 50% of the height of surrounding healthy tissue.⁵ Patients underwent baseline investigations and were then opted for surgery.

Procedure

After prepping the surgical field with betadine and spirit, the site was marked according to the size and shape of the defect using a skin marker. With the help of surgical blade no. 11, beveled skin incisions along the direction of hair follicles were made to prevent the transection of hair follicles, and the skin was excised in a single stroke to avoid overlapping and cross-hatching [Figure 1]. The wound closure was done by subcutaneous buried 6-0 polyamide black non-absorbable suture followed by a cutaneous vertical mattress using 6-0 polyamide black. The sutured site was cleaned using betadine and normal saline. The post-procedure photographs were taken and were packed taking all aseptic precautions. Suture removal was done on the 7th day.

Evaluation

Photographs were captured at the following visits: First visit, 7th day of the procedure after suture removal, at the end of 1 month, and 3 months for the assessment of the scar. The overall outcomes of scars are assessed by the Physician and Subject Global Esthetic Improvement Scale in 3rd month [Table 1].

Results

A total of 12 patients were enrolled in our study, among which 8 (66%) were males and 4 (33%) were females. Age at

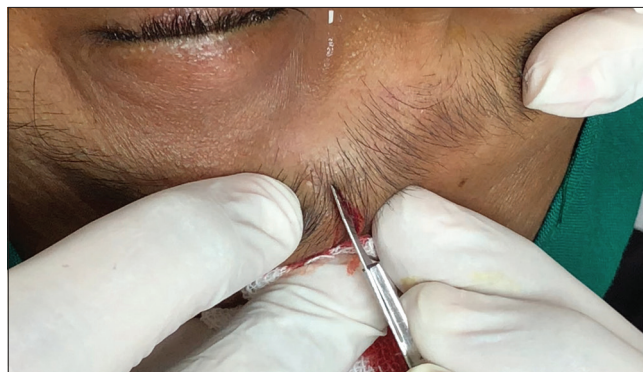

Figure 1: Illustration of surgical technique.

Table 1: Physician global esthetic improvement scale.

| Grade | Degree | Description |
|-------|-------------------------|--|
| 1 | Exceptional improvement | Excellent corrective result |
| 2 | Very improved patient | Marked improvement of the appearance, but not completely optimal |
| 3 | Improved patient | Improvement of the appearance is better compared with the initial condition, but a touch-up is advised |
| 4 | Unaltered patient | The appearance substantially remains the same compared with the original condition |
| 5 | Worsened patient | The appearance has worsened compared with the original condition |

Table 2: Demographic parameters.

| Sex/Age | <20 years | 21-40 years | 41-60 years | >60 years |
|---------|-----------|-------------|-------------|-----------|
| M (8) | 1 | 5 | 2 | 0 |
| F (4) | 0 | 3 | 1 | 0 |

M: Male, F: Female

Table 3: Clinical characteristics.

| Characteristics | Value (n=12) |
|----------------------|--------------|
| Eyebrow involvement | |
| Unilateral | 12 |
| Bilateral | 0 |
| Cause of defect/scar | |
| Trauma | 10 |
| Burn | 1 |
| Tumor | 1 |
| Others | 0 |

Table 4: Physician global esthetic improvement scale after day 7 and after 3 months.

| Case no. | Global Esthetic Improvement Scale | | | |
|----------|-----------------------------------|-----------------------|-------------------------------|-------------------------|
| | 7 days after reconstruction | | 3 months after reconstruction | |
| | Grade | Degree | Grade | Degree |
| 1 | 2 | Very improved patient | 1 | Exceptional improvement |
| 2 | 3 | Improved patient | 2 | Very improved patient |
| 3 | 2 | Very improved patient | 1 | Exceptional improvement |
| 4 | 2 | Very improved patient | 2 | Very improved patient |
| 5 | 3 | Improved patient | 3 | Improved patient |
| 6 | 3 | Improved patient | 2 | Very improved patient |
| 7 | 2 | Very improved patient | 2 | Very improved patient |
| 8 | 2 | Very improved patient | 1 | Exceptional improvement |
| 9 | 3 | Very improved patient | 2 | Very improved patient |
| 10 | 3 | Improved patient | 3 | Improved patient |
| 11 | 2 | Very improved patient | 1 | Exceptional improvement |
| 12 | 3 | Improved patient | 2 | Very improved patient |

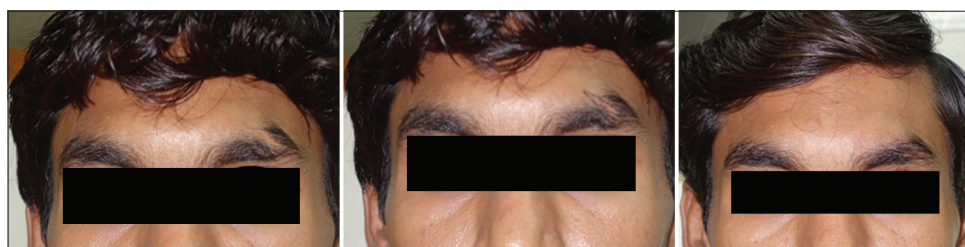

Figure 2: Case 1.

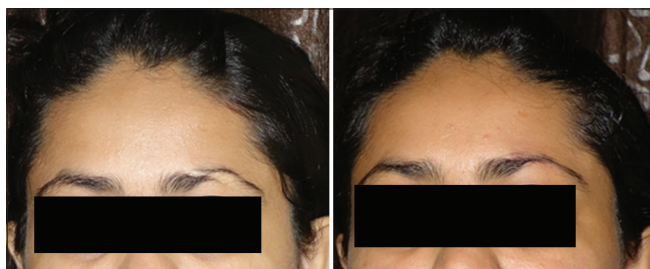

Figure 3: Case 2.

presentation ranged from 19 to 44 years with a mean age of 29.5 years [Table 2].

All patients had unilateral eyebrow involvement. Out of 12 patients, 10 patients were treated for post-traumatic scar, one for burn scar, and one for tumor [Table 3].

For assessment of improvement, the Global Esthetic Improvement Scale was used 7 days after and 3 months after treatment [Figures 2-6]. After day 7, 6 (50%) patients showed very improvement (Grade 2) and 6 (50%) patients showed improvement (Grade 3). On assessing further after 3 months, 4 (33%) patients showed exceptional improvement (Grade 1), 6 (50%) patients showed very improvement (Grade 2), and 12 (17%) patients showed improvement (Grade 3) [Table 4].

No complications such as pigmentary changes, secondary infections, or dehiscence were noted in any of the patients.

DISCUSSION

The forehead is a challenging regional esthetic unit. The skin is almost fixed to the frontal muscle, and the skin expansibility concerning the relaxed skin tension lines is limited.^{6,7} Ideally, the skin incision is considered to be placed at 90° about the skin to get perfect wound edge adaptation. The incision on hair-bearing tissues, such as the scalp, is considered to be beveled at 45° to prevent transection of hair follicles. There is no consensus about the preferred incision angle on the brow.⁸

The beveled incision on the eyebrow is mainly used in facelift and brow lift surgeries. In our study, we used the same concept for simple elliptical excision of post-traumatic or post-burn scar tissue and tumor, and we placed a beveled incision which is parallel to the hair follicle at an angle of range of 20–45° to the skin. We found that beveled incisions helped to prevent transection of hair follicles and also promoted eyebrow esthetics.

In our study, a favorable angle for incision was found to be 20–45° in reference to skin. Feinendegen *et al.*, in their study, identified that beveled 20° incision for brow repositioning

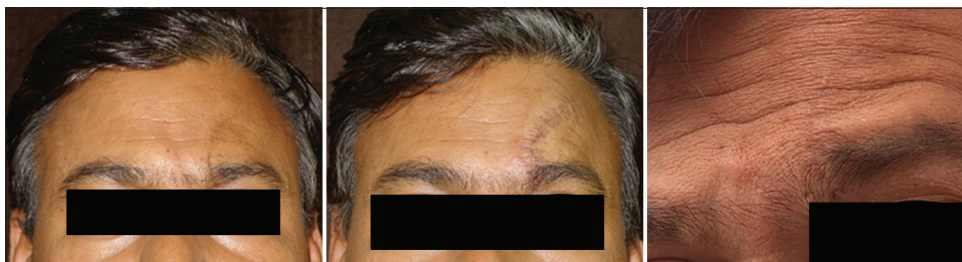

Figure 4: Case 3.

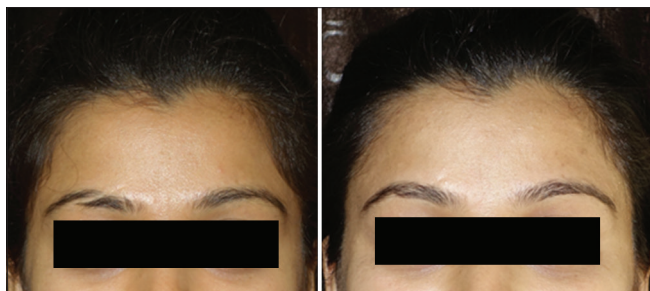

Figure 5: Case 4.

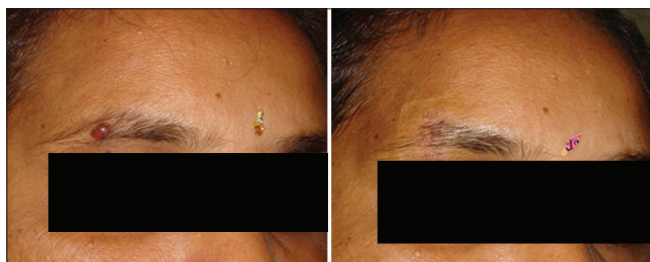


Figure 6: Case 5.

and reshaping showed viable results while produced scars are imperceptible.⁸

Camirand and Doucet carried out a study of a comparison between parallel hairline incisions and perpendicular incisions when performing a facelift affirmed that perpendicular skin incisions are esthetically better than incisions parallel to the hair follicle, which is discordant with our study.⁹

For better cosmetic outcomes, we used non-absorbable (polyamide black) subcutaneous suture as it lasts for a lifetime, avoids widening of tissue, and ultimately avoids the appearance of railroad track scar or visible fibrotic scar.¹⁰

Despite being a difficult site to treat, a more excellent outcome was observed after simple elliptical excision and direct approximation of eyebrow defects in our study.

CONCLUSION

For reconstruction of eyebrow defects, simple excision and direct approximation with an angled incision along the

direction of the hair follicle are the keys to good esthetic outcome. It avoids the transection of hair follicles as well as decreases the burden of complex advancement or rotational flat surgeries.

Authors' contributions

Yogesh Bhingradia: Concept, clinical study, manuscript editing and review. Akshay Arun Vetal: Literature search, data analysis, manuscript preparation, statistical analysis. Heena Singdia: Data analysis, data acquisition. Aarushi Kinjalk: Data acquisition.

Ethical approval

Institutional Review Board approval is not required.

Declaration of patient consent

The authors certify that they have obtained all appropriate patient consent.

Financial support and sponsorship

Nil.

Conflicts of interest

There are no conflicts of interest.

Use of artificial intelligence (AI)-assisted technology for manuscript preparation

The authors confirm that there was no use of artificial intelligence (AI)-assisted technology for assisting in the writing or editing of the manuscript and no images were manipulated using AI.

REFERENCES

1. Sadr J, Jarudi I, Sinha P. The role of eyebrows in face recognition. *Perception* 2003;32:285-93.
2. Figueira E, Wasserbauer S, Wu A, Huilgol SC, Marzola M, Selva D. Eyebrow reconstruction. *Orbit* 2017;36:273-84.
3. Cedars MG. Reconstruction of the localized eyebrow defect.

- Plast Reconstr Surg 1997;100:685-9.
4. Poetschke J, Gauglitz GG. Current options for the treatment of pathological scarring. *J Dtsch Dermatol Ges* 2016;14:467-77.
 5. Jeong SH, Koo SH, Han SK, Kim WK. An algorithmic approach for reconstruction of burn alopecia. *Ann Plast Surg* 2010;65:330-7.
 6. Gonzalez-Ulloa M, Stevens E. Reconstruction of the nose and forehead by means of regional aesthetic units. *Br J Plast Surg* 1961;13:305-9.
 7. Borges AF, Alexander JE. Relaxed skin tension lines, Z-plasties on scars, and fusiform excision of lesions. *Br J Plast Surg* 1962;15:242-54.
 8. Feinendegen DL, Tremp M, Roldán JC. Flat incision technique for reconstructive brow surgery: A wound healing model and clinical evaluation. *Plast Reconstr Surg Glob Open* 2018;6:e1684.
 9. Camirand A, Doucet J. A comparison between parallel hairline incisions and perpendicular incisions when performing a face lift. *Plast Reconstr Surg* 1997;99:10-5.
 10. Bhingradia YM, Gondaliya SJ. Utilization of nonabsorbable (polyamide black) buried subcutaneous suture material in closure of elliptical excision in various indications for better aesthetic outcome. *J Cutan Aesthet Surg* 2021;14:215-9.

How to cite this article: Bhingradia YM, Vetel AA, Singdia H, Kinjalk A. Eyebrow reconstruction by simple elliptical excision with beveled incision – A case series of twelve patients. *J Cutan Aesthet Surg.* 2024;17:325-9. doi: 10.25259/jcas_189_22