

Fractional CO₂ Laser-induced Delivery of Topical Corticosteroids Hastens Resolution of Localized Plaque Sarcoidosis

Dear Editor,

Sarcoidosis, an inflammatory disorder, is characterized histopathologically by non-caseating granulomas in one or more organ systems,^[1] most commonly lungs, lymph nodes, and skin. Skin lesions are the initial manifestation in almost one-third of patients with sarcoidosis.^[2] Various types of cutaneous sarcoidosis exist; the most common, acute maculopapular type, has a favorable prognosis. On the contrary, plaque sarcoidosis—which develops mostly on the back, buttocks, face, and extensor extremities—is associated with chronic disease, presenting a variable response to the standard therapies.^[1] Furthermore,

powerful immunosuppressive treatments such as methotrexate and biologics have inherent side effects, including long-term risks of infection, hepatotoxicity, and potential malignancy.^[3] Light and laser therapies are promising alternatives for therapy-resistant cases. Herein we present a case of localized plaque-type sarcoidosis treated successfully with fractional carbon dioxide laser (CO₂) and topical steroids.

A 38-year-old Indian man presented with a single localized asymptomatic indurated plaque over the left knee [Figure 1A] since 3 years. It was gradually progressive, despite multiple treatments taken intermittently including

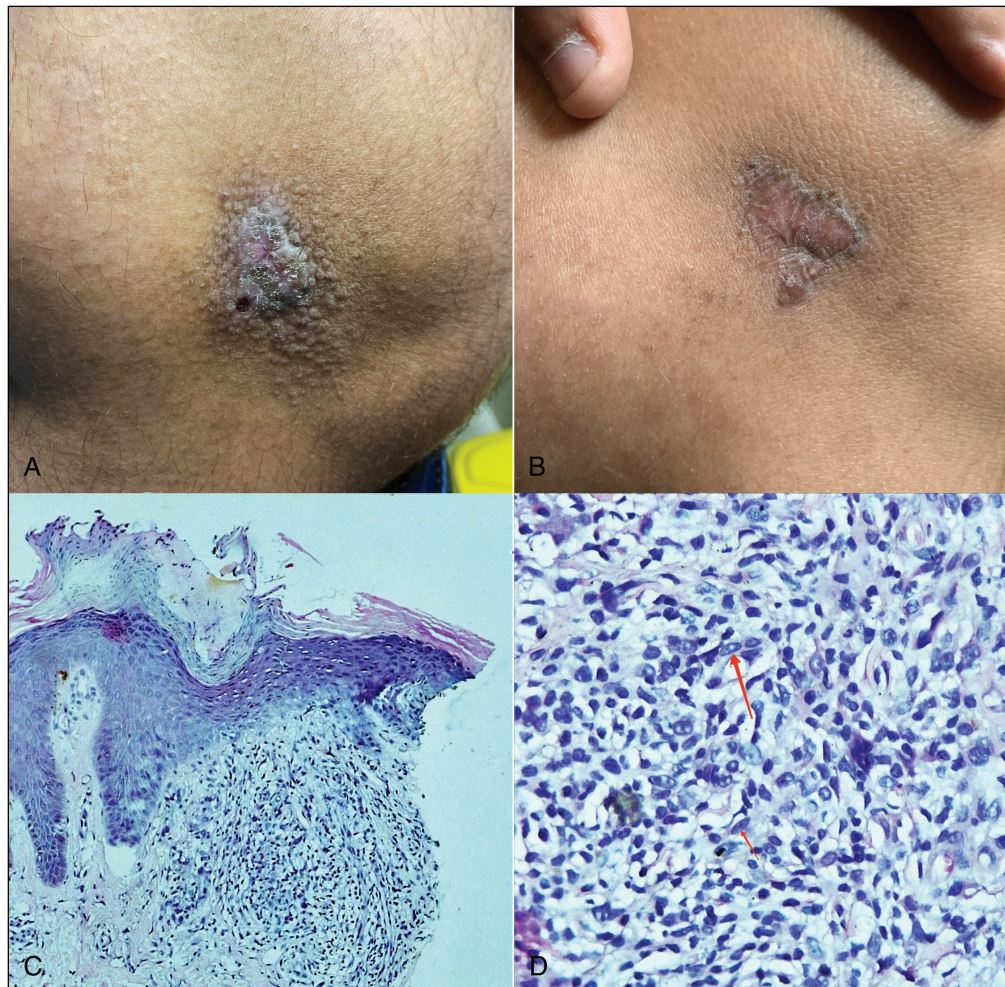


Figure 1: (A) Solitary, 2 cm x 1 cm, reddish-brown plaque with minimal scaling over medial aspect of left knee surrounded by skin colored micropapules. (B) Erythematous, atrophic plaque with hyperpigmented margins after 4 weeks of treatment. (C) Mild acanthosis and elongation of rete ridges, superficial dermis shows multiple well-formed epithelioid granulomas with surrounding lymphocytes (hematoxylin and eosin, 100x). (D) Well-formed epithelioid granulomas with surrounding lymphocytes (hematoxylin and eosin, 400x)

topical and oral steroids. There were no systemic complaints or any history of trauma. Histopathological examination revealed mild acanthosis, elongated rete ridges, and superficial dermal epithelioid granulomas surrounded by scanty lymphocytes [Figure 1C and D]. Fite faraco- and PAS stain were negative; chest CT was normal. Except for raised serum ACE levels (67.32 U/L, normal: 8–52 U/L), other biochemical tests, including serum calcium, were normal. Diagnosed as a case of localized plaque sarcoidosis, the patient was given fractional CO₂ laser therapy (18 mJ, 0.6mm distance, overlap 4) under topical anesthesia to make microchannels, as a means of drug delivery for topical corticosteroids. Immediately after lasing, clobetasol acetate cream was applied under occlusion and the patient was advised to apply the same twice daily till the next session. A total of four sessions were done fortnightly. Follow-up after 6 months revealed mild atrophy, subtle hypopigmentation, and minimal induration over the borders of the lesion which had now stopped progressing [Figure 1B]. The satisfied patient declined to continue further therapy or a repeat biopsy.

Though many therapies have been extensively used for cutaneous sarcoidosis, few have been evaluated in randomized trials. Although topical corticosteroids are generally considered to be beneficial for skin lesions, evidence thereof is scant. Intralesional injections of triamcinolone acetonide (3–20mg/mL) repeated every 3–4 weeks, may increase efficacy by better delivery of the drug to the reticular dermis. Use of fractional CO₂ laser as a treatment modality of plaque sarcoidosis has not been previously reported. Three previous case series^[3-5] using ablative CO₂ laser resurfacing for treating grossly disfiguring lupus pernio refractory to medical therapy reported excellent post-operative responses which were maintained for many subsequent years. It is noteworthy that ablative CO₂ laser procedures described in the aforementioned case series, like ours, served only to recontour rather than excise all of the abnormal tissue. Fractional CO₂ serves to ablate the diseased tissue along with hastening the dermal delivery of steroids by creating microchannels and thus should be looked at as an effective treatment modality for localized cutaneous disease.

Declaration of patient consent

The authors certify that they have obtained all appropriate patient consent forms. In the form the patient(s) has/have given his/her/their consent for his/her/their images and other clinical information to be reported in the journal.

The patients understand that their names and initials will not be published and due efforts will be made to conceal their identity, but anonymity cannot be guaranteed.

Financial support and sponsorship

Not applicable.

Conflicts of interest

There are no conflicts of interest.

Rohit Kothari, Nandita Rajan, Aashna Sutaria, Yugal K. Sharma, Aayush Gupta

Department of Dermatology, Dr. D.Y. Patil Medical College and Hospital, Pune, Maharashtra, India

Address for correspondence: Dr. Aayush Gupta,
Department of Dermatology, Dr. D.Y. Patil Medical College, Hospital and
Research Centre, Pune, Maharashtra, India.
E-mail: aayushgupta@gmail.com

REFERENCES

1. Haimovic A, Sanchez M, Judson MA, Prystowsky S. Sarcoidosis: A comprehensive review and update for the dermatologist: Part I. Cutaneous disease. *J Am Acad Dermatol* 2012;66:699.e1-18; quiz 717-8.
2. Lodha S, Sanchez M, Prystowsky S. Sarcoidosis of the skin: A review for the pulmonologist. *Chest* 2009;136:583-96.
3. Stack BC Jr, Hall PJ, Goodman AL, Perez IR. CO₂ laser excision of lupus pernio of the face. *Am J Otolaryngol* 1996;17:260-3.
4. Young HS, Chalmers RJ, Griffiths CE, August PJ. CO₂ laser vaporization for disfiguring lupus pernio. *J Cosmet Laser Ther* 2002;4:87-90.
5. O'Donoghue NB, Barlow RJ. Laser remodelling of nodular nasal lupus pernio. *Clin Exp Dermatol* 2006;31:27-9.

This is an open access journal, and articles are distributed under the terms of the Creative Commons Attribution-NonCommercial-ShareAlike 4.0 License, which allows others to remix, tweak, and build upon the work non-commercially, as long as appropriate credit is given and the new creations are licensed under the identical terms.

For reprints contact: reprints@medknow.com

Access this article online	
Quick Response Code:	Website: www.jcasonline.com
	DOI: 10.4103/JCAS.JCAS_68_22

How to cite this article: Kothari R, Rajan N, Sutaria A, Sharma YK, Gupta A. Fractional CO₂ laser-induced delivery of topical corticosteroids hastens resolution of localized plaque sarcoidosis. *J Cutan Aesthet Surg* 2023;16:252-3.