

Horn on the Nail: Acquired Ungual Fibrokeratoma

Noor Jahan, Padubidri Kombettu Ashwini, Santhebachall Gurumurthy Chethana, Jayadev Betkerur, Veeranna Shastry

Department of Dermatology, Venereology, and Leprology, JSS Medical College, JSS Academy of Higher Education and Research, Mysuru, Karnataka, India

Abstract

Acquired unguinal fibrokeratomas are uncommon fibrous tissue tumors that are located in the unguinal area. They usually presents as asymptomatic, solitary, smooth, dome-shaped, or fingerlike, flesh-colored papules accompanying nail deformities, including a longitudinal groove and trachyonychia. Acquired periungual fibrokeratoma is considered a topographical variant of acquired digital fibrokeratoma; it has a unique “garlic clove” shape. A traumatic origin has been suggested, as acquired unguinal fibrokeratomas occur most frequently on the fingers and toes. Herein, we report a case of a 29-year-old man with growth over left little finger, who was treated with surgical excision of the tissue. Histopathological examination confirmed unguinal fibrokeratoma. It is a rare variant of digital fibrokeratoma, and so far the first unguinal fibrokeratoma to appear *de novo* on little finger to the best of our knowledge.

Keywords: Garlic clove, horn like, unguinal fibrokeratoma

INTRODUCTION

Acquired unguinal fibrokeratoma is an uncommon benign fibrous tissue tumor located in the nail area. The term was first coined by Cahn in 1977.^[1] He postulated that this was the same as the garlic clove fibroma, which was first identified by Steel in 1965.^[1,2] Digital unguinal fibrokeratoma is seen in all races, between 12 and 70 years of age, with peak in the middle age.^[3] Higher incidence was seen in males than that in females. Acquired unguinal fibrokeratomas usually present as asymptomatic, solitary, smooth, dome-shaped, or fingerlike, flesh-colored papules, accompanying nail deformities that include a longitudinal groove and trachyonychia.^[4] It is a rare variant of digital fibrokeratoma.

CASE REPORT

A 29 year old man presented with an asymptomatic growth over the left little finger since 18 months. There was no history of preceding trauma. It started as a small raised lesion projecting out from the center of the proximal nail fold. Over a period of 18 months, it developed into a hornlike structure. There was no history of manipulation of lesion. No past history of similar skin lesions was reported.

On physical examination, solitary longitudinal firm fingerlike growth, emerging from the center of proximal nail fold toward distal part of nail, was observed. The distal tapering end of the growth appeared necrosed. The nail plate of the involved finger showed linear depression beneath the growth. The lesion was not adherent to underlying nail plate. Minimal tenderness was present. No bony deformity was apparent [Figures 1–4].

Following clinical differentials were considered—acquired unguinal fibrokeratoma, onychomatricoma, Koenen tumor, and glomus tumor. An excision biopsy was planned.

Under aseptic conditions, a proximal digital block was performed using 2% lignocaine without adrenaline. Incision was put at proximal nail fold, roofing the growth. The proximal nail fold was retracted to expose the nail matrix by skin hooks. The whole tumor was excised with its basal attachment. Tissue was sent for histopathological examination. Wound healed with secondary intention [Figure 4]. No recurrence was observed in 5 months

Address for correspondence: Dr. Ashwini P. K.,

Department of Dermatology, Venereology, and Leprology,
JSS Medical College, JSS Academy of Higher Education and Research,
S.S. Nagar, Mysuru 570015, Karnataka, India.
E-mail: drashwinipk@gmail.com

Access this article online

Quick Response Code:



Website:
www.jcasonline.com

DOI:
10.4103/JCAS.JCAS_71_19

This is an open access journal, and articles are distributed under the terms of the Creative Commons Attribution-NonCommercial-ShareAlike 4.0 License, which allows others to remix, tweak, and build upon the work non-commercially, as long as appropriate credit is given and the new creations are licensed under the identical terms.

For reprints contact: reprints@medknow.com

How to cite this article: Noor J, Ashwini PK, Chethana SG, Betkerur J, Shastry V. Horn on the nail: Acquired unguinal fibrokeratoma. *J Cutan Aesthet Surg* 2021;14:121-4.

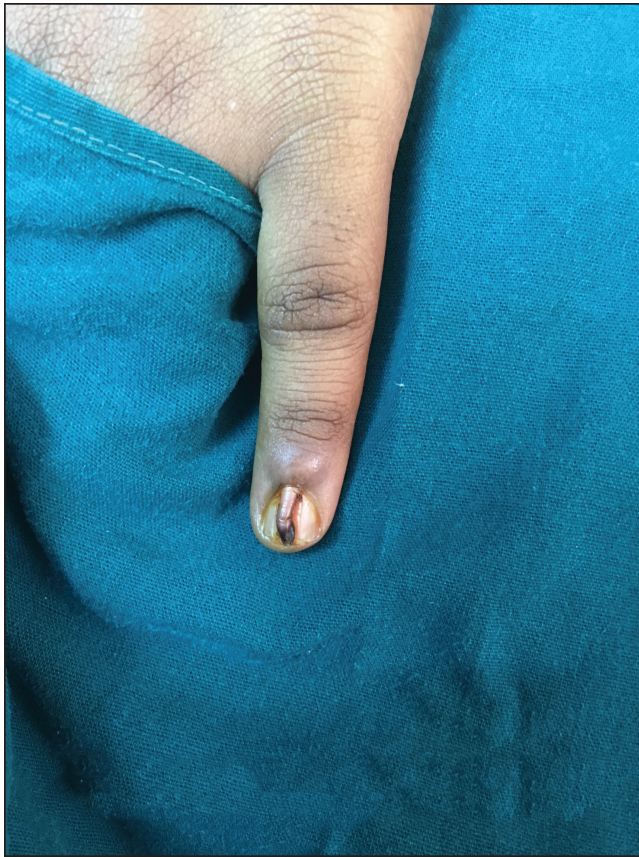

Figure 1: Fingerlike projection emerging from center of proximal nail fold

following excision. Histopathology revealed keratinized stratified squamous epithelium with a prominent granular layer of thick orthokeratosis with superficial region showing fibrocollagenous matrix with increased blood vessels. Features were suggestive of fibrokeratoma.

DISCUSSION

Acquired periungual fibrokeratomas are rare, benign, fibrous, and hyperkeratotic tumors,^[1,5] presenting as lesions that emerge from the proximal nail fold or sometimes from the nail bed.^[6,7] Although acquired periungual fibrokeratoma is considered a topographical variant of acquired digital fibrokeratoma, it has a unique “garlic clove” shape.^[2,8]

Including the word “acquired” in the terminology of this unusual tumor leads one to believe that there is a precipitating factor. However, the etiology is still unknown. Hare and Smith^[9] proposed that trauma is involved, whereas Nemeth and Penneys^[10] reported that factor XIIIa-positive dermal dendritic cells play an important role in the regulation of collagen synthesis.^[9-12] A traumatic origin has been suggested because acquired unguial fibrokeratomas occur most frequently on the fingers and toes.^[13] Acquired unguial fibrokeratomas usually present as asymptomatic, firm, smooth, flesh-colored papules, protruding laterally on the nail plate from beneath the cuticle of the proximal

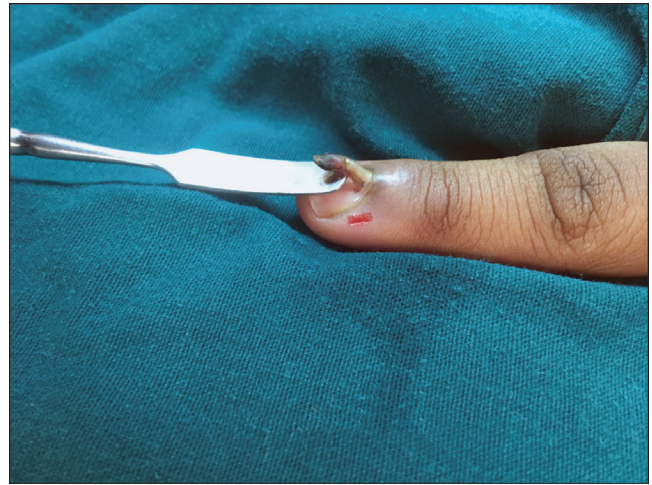

Figure 2: Nonadherence to nail

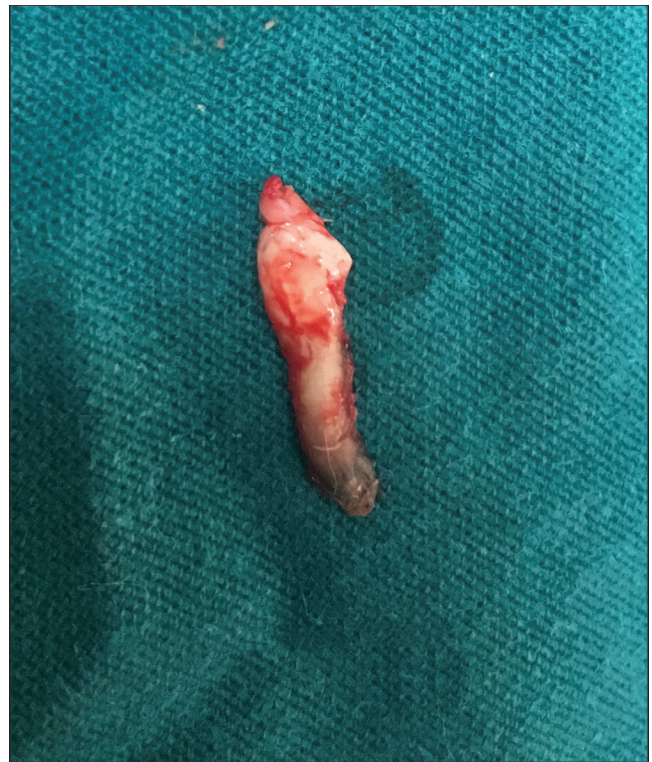

Figure 3: Excised tissue

nail fold. Verruca vulgaris, a supernumerary digit, Koenen tumor of tuberous sclerosis, pyogenic granuloma, eccrine poroma, cutaneous horn, epidermoid cyst, acrochordons, and neurofibromas must be included in the differential diagnosis of acquired unguial fibrokeratoma.^[9,13-15]

Histopathological findings include hyperkeratosis, acanthosis, focal hypergranulosis, and irregular rete ridge elongation in the epidermis. The core of the tumor consists of thickened collagen in the dermis, oriented parallel to the long axis of the lesion [Figures 5 and 6]. In 1985, Kint *et al.*^[16] classified acquired digital fibrokeratomas into three histological subtypes. In all three, the epidermis is

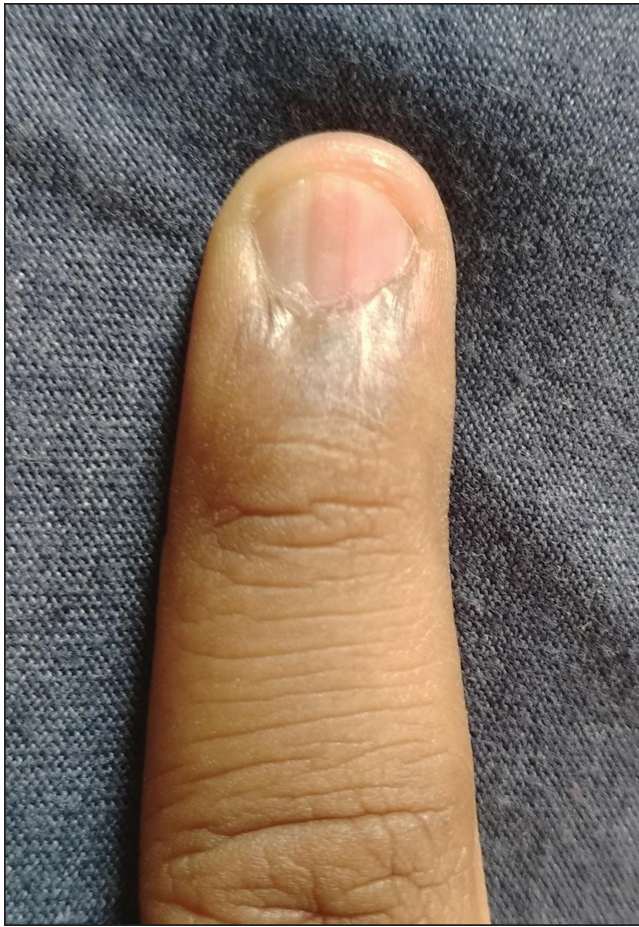


Figure 4: Postoperative wound healing

acanthotic and hyperkeratotic. In the first variant, tumor cores are composed of thick, dense, closely packed, and irregularly arranged collagen bundles. The second variant shows an increase in grouped fibroblasts and reduced elastic fibers. The third variant is composed of a poorly cellular and edematous structure with completely absent elastic tissue. Our case showed a mixed variety of first and second variants.

Kint *et al.*^[16] divided acquired unguial fibrokeratomas into two types based on appearance, that is, dome shaped and fingerlike. However, more diverse morphologies such as rod shaped, dome shaped, flat, and branching are also seen. Kim *et al.*^[17] classified acquired unguial fibrokeratoma into four clinical types, namely pine pitlike, dome shaped, fingerlike, and chicken's footlike.

Kim *et al.*^[17] found that dome-shaped acquired unguial fibrokeratomas were the most common clinical type, our case was of fingerlike morphology. Acquired unguial fibrokeratomas should be considered in the differential diagnosis of periungual tumors with a longitudinal nail groove. The groove is thought to be due to the fibrokeratoma originating from the underside of the proximal nail fold, compressing the nail matrix.^[16]

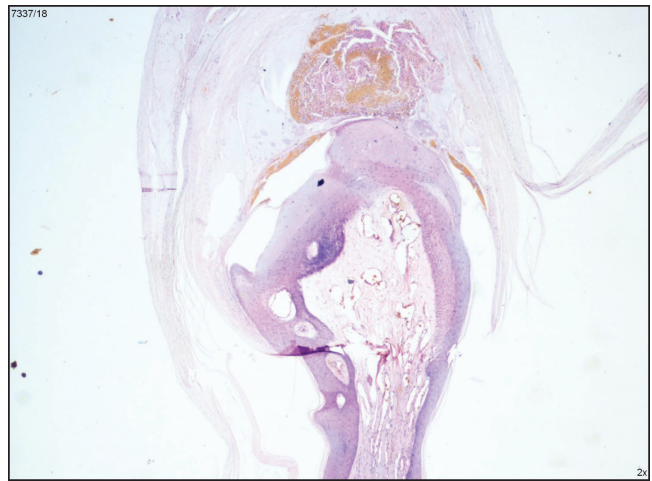


Figure 5: Histopathological features in ×2 magnification

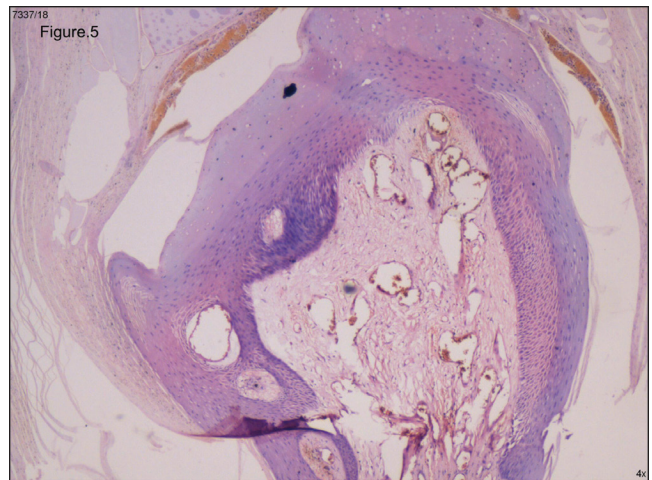


Figure 6: Histopathological features in ×4 magnification

Acquired unguial fibrokeratomas do not spontaneously regress.^[14] They should be excised when symptomatic or when it causes significant cosmetic problems. The preferred treatment is total excision because superficial removal usually results in recurrence.^[18] Various surgical techniques can be used to resect these tumors, depending on their size and location. Usually, the tumor is incised around its base and dissected from the bone. If a lesion is beneath the nail plate, partial or total removal of the nail is required first. Lesions above the nail plate, however, can be removed by shaving followed by phenolization, CO₂ laser vaporization, or surgical resection after lifting the proximal nail fold as a banner flap.^[19-21] During the procedure, the germinal matrix should be preserved by careful dissection along the under surface of the tumor.^[22,23] To minimize the risk of recurrence, it is recommended that careful elevation of lesion and retraction of the proximal nail fold to expose the whole tumor and surrounding nail matrix is performed, avoiding additional injury to the nail matrix.

CONCLUSION

Acquired unguis fibrokeratoma is a rare variant of digital fibrokeratoma. In this case, we found the lesion to be *de novo* (without any history of trauma), it appeared on little finger, which has not been reported so far to the best of our knowledge. We conclude that complete excision of tumor from base is the treatment of choice for the condition. This case has been reported for its rarity.

Financial support and sponsorship

Nil.

Conflicts of interest

There are no conflicts of interest.

REFERENCES

- Cahn RL. Acquired periungual fibrokeratoma. A rare benign tumor previously described as the garlic-clove fibroma. *Arch Dermatol* 1977;113:1564-8.
- Steel HH. Garlic-clove fibroma. *JAMA* 1965;191:1082-3.
- Ali M, Mbah CA, Alwadiya A, Nur MM, Sunderamoorthy D. Giant fibrokeratoma, a rare soft tissue tumor presenting like an accessory digit, a case report and review of literature. *Int J Surg Case Rep* 2015;10:187-90.
- Hwang S, Kim M, Cho BK, Park HJ. Clinical characteristics of acquired unguis fibrokeratoma. *Indian J Dermatol Venereol Leprol* 2017;83:337-43.
- Verallo VV. Acquired digital fibrokeratomas. *Br J Dermatol* 1968;80:730-6.
- Saito S, Ishikawa K. Acquired periungual fibrokeratoma with accessory germinal matrix. *J Hand Surg Br* 2002;27:549-55.
- Hashiro M, Fujio Y, Tanaka M, Yamatodani Y. Giant acquired fibrokeratoma of the nail bed. *Dermatology* 1995;190:169-71.
- Yasuki Y. Acquired periungual fibrokeratoma—a proposal for classification of periungual fibrous lesions. *J Dermatol* 1985;12:349-56.
- Hare PJ, Smith PA. Acquired (digital) fibrokeratoma. *Br J Dermatol* 1969;81:667-70.
- Nemeth AJ, Penneys NS. Factor XIIIa is expressed by fibroblasts in fibrovascular tumors. *J Cutan Pathol* 1989;16:266-71.
- Cerio R, Griffiths CE, Cooper KD, Nickoloff BJ, Headington JT. Characterization of factor XIIIa positive dermal dendritic cells in normal and inflamed skin. *Br J Dermatol* 1989;121:421-31.
- Cerio R, Spaul J, Oliver GF, Jones WE. A study of factor XIIIa and MAC 387 immunolabeling in normal and pathological skin. *Am J Dermatopathol* 1990;12:221-33.
- Altman DA, Griner JM, Faria DT. Acquired digital fibrokeratoma. *Cutis* 1994;54:93-4.
- Berger RS, Spielvogel RL. Dermal papule on a distal digit. Acquired digital fibrokeratoma. *Arch Dermatol* 1988;124:1559-60, 1562-3.
- Vinson RP, Angeloni VL. Acquired digital fibrokeratoma. *Am Fam Physician* 1995;52:1365-7.
- Kint A, Baran R, De Keyser H. Acquired (digital) fibrokeratoma. *J Am Acad Dermatol* 1985;12:816-21.
- Kim JM, Cho HH, Kin WJ, Mun JH, Song M, Kim HS, *et al.* Clinical characteristics of acral fibrokeratoma. *Korean J Dermatol* 2014;52:535-9.
- Shelley WB, Phillips E. Recurring accessory “fingernail”: periungual fibrokeratoma. *Cutis* 1985;35:451-4.
- Mazaira M, del Pozo Losada J, Fernández-Jorge B, Fernández-Torres R, Martínez W, Fonseca E. Shave and phenolization of periungual fibromas, Koenen’s tumors, in a patient with tuberous sclerosis. *Dermatol Surg* 2008;34:111-3.
- Berlin AL, Billick RC. Use of CO₂ laser in the treatment of periungual fibromas associated with tuberous sclerosis. *Dermatol Surg* 2002;28:434-6.
- Vazquez-Doval FJ. Surgery of the nail region. In: *Atlas of nail diseases*. Barcelona, Spain: ESMON Pharma; 2008. pp. 112-3.
- Lee CY, Lee KY, Kim KH, Kim YH. Total excision of acquired periungual fibrokeratoma using bilateral proximal nail fold oblique incision for preserving nail matrix. *Dermatol Surg* 2010;36:139-41.
- Yélamos O, Alegre M, Garcés JR, Puig L. Periungual acral fibrokeratoma: Surgical excision using a banner flap. *Actas Dermosifiliogr* 2013;104:830-2.