

Current Standards and Recent Progress in Minimally Invasive Phlebo Surgery

Venous disorders are among the most frequent disease patterns in the Western world. Still at the turn to the 21st century there was no alternative available to the surgical treatment of varicosis. Meanwhile the endoluminal treatment methods have established and have demonstrated their efficiency while having lower side effects in comparison to the traditional treatment, even though conservatively oriented surgeons are still skeptically eyeing these methods. In the US, according to the latest MRG report of 2011, about 95% of all venous surgeries are already done endoluminally. This paper offers an overview of prevailing treatment standards of the most important endoluminal therapy techniques and shows current trends.

KEYWORDS: Endoluminal, laser, radiofrequency, sclerotherapy, varicose veins

Only he, who is able to change, stays true to himself.
- Habermas

INTRODUCTION

Venous disorders are among the most frequent disease patterns in the Western world. In Germany up to 40% of females and 20% of males suffer from symptoms that range from tiredness, a sensation of heaviness, pains and swellings in the legs to open, non-healing sores. Occasionally, varicose veins may result in vein inflammations and vein thromboses [Figures 1-5].^[1,2]

Yet even at the start of the 21st century there was no alternative therapy available to treat varicosis. It was generally accepted that surgery was the only option [Figure 6].

Within less than five years endoluminal therapy techniques had been authorized in Germany, dividing the community of vein surgeons into enthusiastic advocates and bitter opponents. Radiofrequency

obliteration was approved in 1998, and endovenous laser therapy in 1999. Even the medicamentous sclerotherapy techniques experienced a renaissance. These treatments triggered a new debate about treatment strategies (in general) and their successes, which still rages today. Highly conservative surgeons and phlebomists still view these methods with scepticism because there is no crossotomy or ligation of the sapheno-popliteal junction. This flies in the face of traditional wisdom, which calls for the complete crossotomy and ligation at the level of the deep vein of the GSV and the resection of the SSV segment near the sapheno-femoral junction. This has been proven to be vital by many studies, including the 2007 German Groin Recurrence Study conducted by Mumme.^[3] Nevertheless, the new treatment methods spread quickly, even in Germany. At least it is incontestable that the new methods spawned an enhanced scientific investigation of varicosis. Traditional venous surgery has to compete with the new methods and redefine its status.

Every year more than 300,000 operations on veins are performed in Germany. Unlike in the US where more than 80% of all operations were conducted endoluminally even in 2008, about 90% of all operations in Germany are still performed using traditional techniques. The main reason for this is that new methods have not yet been approved by the Federal Joint Committee for Outpatient Care for Statutorily Insured Patients. The latest MRG report published in 2011 actually puts the percentage

Access this article online	
Quick Response Code: 	Website: www.jcasonline.com
	DOI: 10.4103/0974-2077.99443

Oliver Göckeritz

Chirurgische Praxisklinik and Venenzentrum Leipzig Nonnenstrasse 44, Leipzig-Germany

Address for correspondence:

Mr. Oliver Gockert, Chirurgische Praxisklinik und Venenzentrum Leipzig Nonnenstrasse 44, Leipzig-Germany. E-mail: sportmed@gmx.de

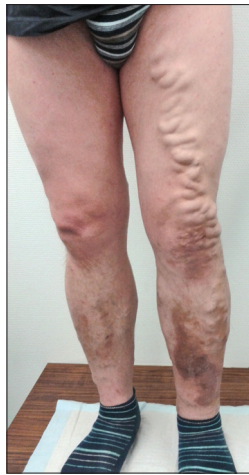

Figure 1: Varicose veins

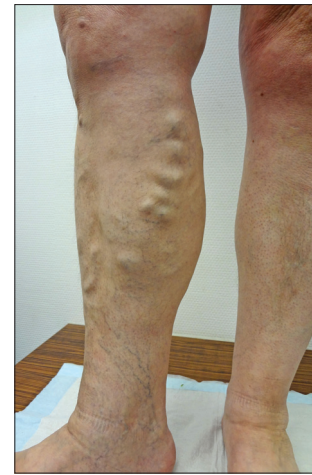

Figure 2: Varicose veins

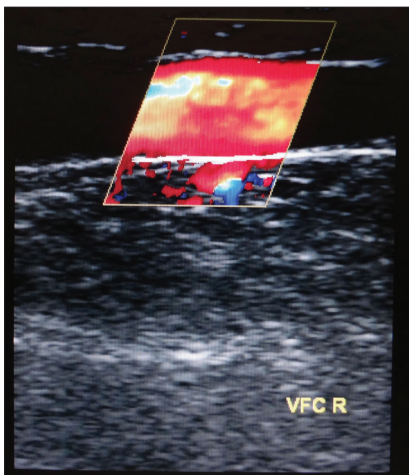


Figure 3: Incompetent GVS (duplex ultrasound)

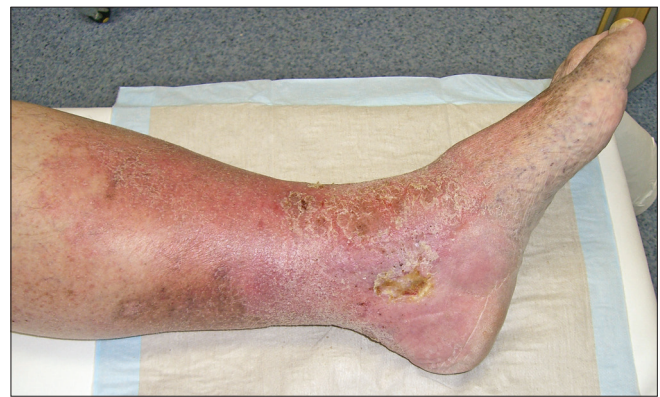

Figure 4: Ulcer

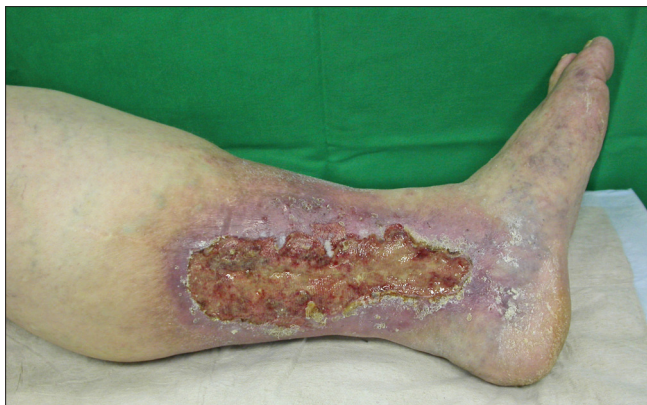

Figure 5: Ulcer

of endoluminal treatments at about 95% of all venous operations in the USA.

Initial problems and side effects of the endoluminal techniques included the long duration of treatment in the case of the ClosurePlus™ technique and the excessive energy emission sometimes encountered in the case of the endoluminal laser treatment that led to painful phlebitides

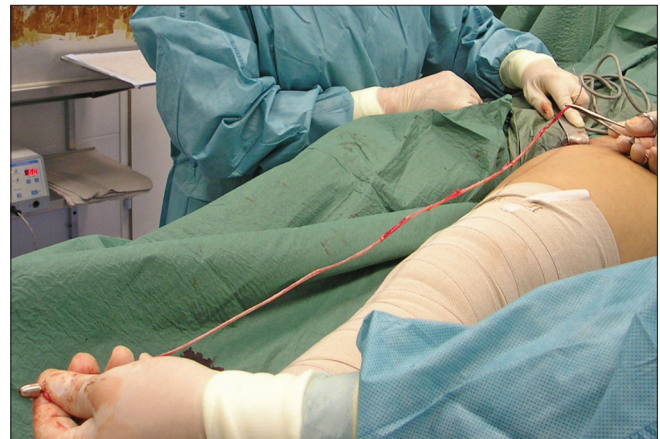

Figure 6: GSV stripping

and extensive ecchymoses. Yet even initial studies and meta-analyses showed the results of these treatments to be at least equivalent to traditional stripping operations with crosssectomy, while the new treatments proved to have fewer side effects and less risk of complication.^[4-12] All studies report fewer side effects and a high level of patient acceptance. The primary closure rates and the early and mid-term results could compete with the results of the traditional surgical stripping operation

with crossectomy [Figures 7]. Interestingly enough, crossectomy performed in conjunction with endoluminal treatment had no significant influence on the result of the treatment.^[13] Whereas the radio wave treatment was performed according to a standard treatment protocol from the beginning, the endoluminal laser treatment has been subject to considerable changes since the first publications by Bone^[14] in 1999 and Navarro^[15] in 2001. The objective was to achieve a further reduction in side effects while ensuring a secure primary closure of the treated veins and permanent success of the treatment. A period of low energy output to the vessel was followed by a phase of high energy application. After the introduction of new laser wavelengths with higher absorption by water and new laser fibers with radial or spherical emission, the side effects were substantially reduced in recent years. This has been verified by studies. In 2010 Sroka^[16] demonstrated the reduction of isolated heat buildups and perforations in the vein wall by means of the new radial emitting laser fiber on the cow foot model. The Recovery Study demonstrated that treatment with a ClosureFast catheter was significantly superior to the 980-nm laser.^[17]

Over the course of time further endovenous techniques have come onto the market, but they have not yet found such a wide application as the ClosureFast™ treatment and the laser treatment. They include a second radiofrequency technique (RFITT™), a hot steam technique (SVO™) and, since summer 2010, a novel sclerosing catheter technique (ClariVein™).

The efficiency of endovenous techniques has been demonstrated in many studies and meta-analyses.^[4,8,18,10,11] The special advantages offered by endoluminal techniques include dispensing with the need for general anaesthetic, the quick return to everyday activities, an improved quality of life and shorter periods of disability [Figures 8 and 9].

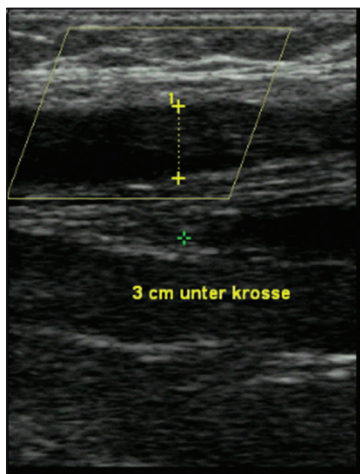


Figure 7: 3 cm below the junction 3 days after ClosureFast treatment

The indications and contraindications for the endoluminal techniques correspond to those for classical vein surgery. In fact, the therapeutical spectrum has actually been widened, as it is possible for instance to operate several truncal veins in a single OP session, and to operate patients who are undergoing anticoagulant treatment and patients with an increased anaesthetic risk.

The endoluminal treatment techniques described below are designed for treating the trunk varicosity. The insufficient lateral branches are treated in the same session by means of mini-phlebectomy or foam sclerotherapy, since they do not degenerate completely after a treatment of the truncal varicosity alone^[19] and may cause pour-in effects and rechannelizations [Figures 10 and 11].

In case of insufficient accessory veins the proximal, subfascially running part of the vein can also be treated by endoluminal techniques. Here the laser is advantageous due to the immediate energy emission on the laser tip, since it can also treat short vein segments. The hot steam therapy is the only technique that can be used on the lateral branches completely, but it still has to prove its purported advantages here.

The follow-up treatment is handled in various ways. Most users recommend the use of a compression stocking for one week post-operatively. A compression wrap was not proved to offer any advantages over the compression stocking. A thrombosis prophylaxis is offered for a period stretching from 5-7 days to not at all in the US. In Germany the prophylaxis is usually carried out, for forensic reasons, in compliance with guidelines with low-molecular heparin. Most users perform a five-day prophylaxis.

At an early stage it was known that complications occur less often than with traditional vein surgery procedures, and this was backed up by pertinent studies.^[4] No major complications were described in the studies.

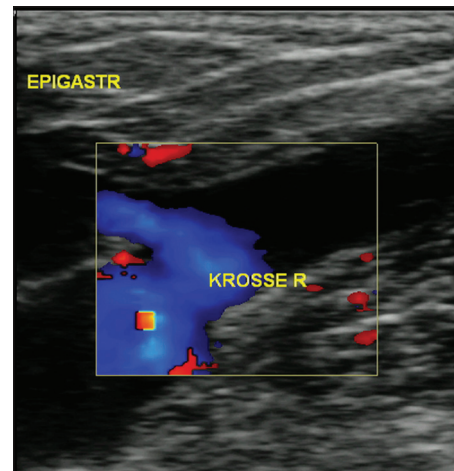


Figure 8: 1 week after ELVeS radial laser-treatment

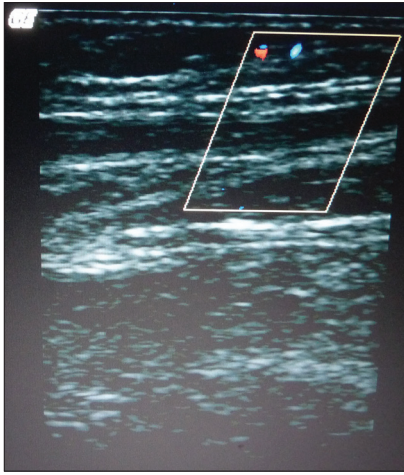


Figure 9: 1 week after ELVeS radial laser-treatment

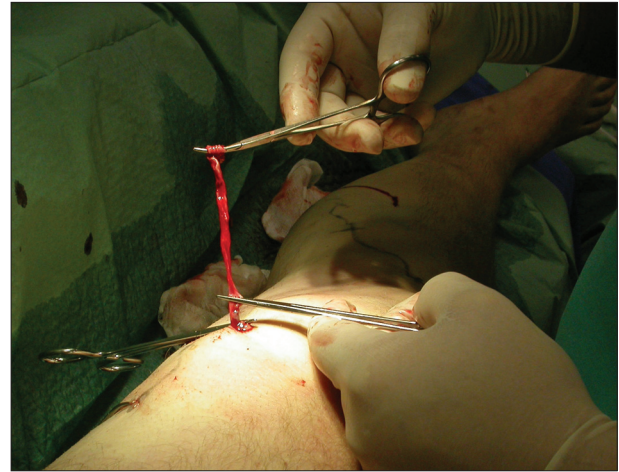


Figure 10: Miniphlebectomy

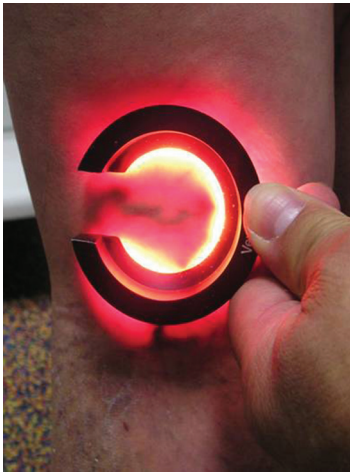

Figure 11: Foam sclerotherapy with veinlite

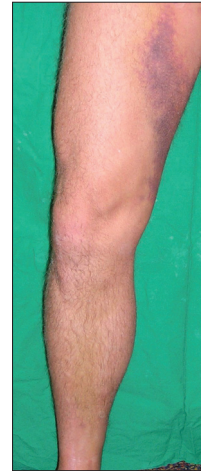

Figure 12: Ecchymosis after laser-treatment

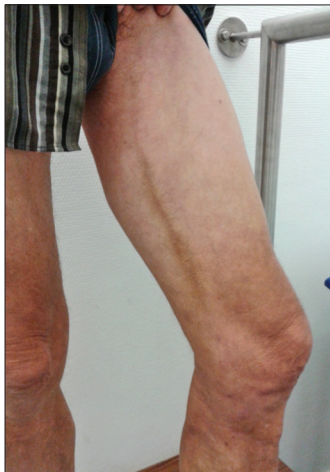

Figure 13: Hyperpigmentation after ClosureFast

Deep leg vein thromboses occur extremely rarely.^[20-23] Nevertheless, the danger of an appositional thrombus growth into the deep vein system at the sapheno-femoral junctions was pointed out.^[24] However, these thrombi

degenerated without negative consequences. Frequent side effects of endoluminal treatments are ecchymoses and periphlebitic problems which occurred mainly in case of treatments by means of a laser with a low wavelength and a high energy emission to the vein [Figures 12 and 13].

But these side effects could be reduced considerably by new laser wavelengths, novel radial or spherical emitting laser fibers and by optimizing the energy density. Furthermore, paraesthesias are described, which generally turned out to be completely reversible.^[25] The danger of nerve lesion increases on the lower leg.^[8] So in the US, for forensic reasons, endoluminal treatment is rarely performed below the knee joint. Hyperpigmentation is an unaesthetic side effect and was observed with very superficial vein routes. It can degenerate within a year,^[25] but cases of permanent hyperpigmentations are also described.^[17] Post-operative bleeding and wound infection are extremely rare complications.

Endoluminal radio frequency obliteration

In the radiofrequency obliteration, energy is delivered to the vein wall by means of a bipolar current in the RF range. The occlusion results from creating a fibrosis of the vein wall. Over the course of time the vein degenerates completely. At first, two catheters were available for this technique, which differed in the number of electrodes on the catheter tip and in the catheter diameter:

- VNUS ClosurePlus™ 6-French catheter
- VNUS ClosurePlus™ 8-French catheter [Figure 14]

The access to the vein is achieved by ultrasound-guided puncturing at the lower insufficiency point of the vein and insertion of an introducer sheath. The catheter tip should be placed by maintaining a distance of 2 cm to the deep vein and be located distal to the orifice of the epigastric vein. After the placement of the catheter the cooled tumescent anaesthetic is circuminjected around the vein to be treated under ultrasound guidance by means of a pump. Then the catheter is withdrawn manually in anti-Trendelenburg-position. Here the withdrawal rate is 1 cm/min for the first 4 cm, then 3 cm/min. So the treatment duration varies between 15 and 35 min. The operating temperature is 85-90°C.

In 2007 the ClosureFast™ catheter replaced the previous treatment. One of the main reasons was the considerably shorter treatment time. Here the energy is supplied via a 7 cm long heating element. The treatment temperature of 120° is reached after 6 seconds and is applied for 14 seconds per term to the vein wall, with the respective segment near the sapheno-femoral junction being treated twice. The treatment is carried through again in anti-Trendelenburg-position of the surgical table and with cooled tumescent anaesthetic that is injected under ultrasound guidance. Tumescent anaesthesia protects the surrounding tissue from heat damages and produces a vasospasm of the vein to be treated, which facilitates a close contact to the heating element of the catheter. A big advantage of this treatment is the standardized treatment technique with reproducible parameters that are monitored acoustically and optically by the generator.

In the treatment the vein is punctured under ultrasound guidance at the distal insufficiency point by means of a 16G needle, either with the patient standing or lying down. Subsequently, an introducer sheath is inserted via a guide-wire. With its help the radiofrequency catheter can then be advanced, under ultrasound guidance, up to the region of the sapheno-femoral junction. The catheter tip is placed directly distal to the orifice of V.epigastrica. Then the vein can be circuminjected by a cooled tumescent solution under ultrasound guidance. The region of the sapheno-femoral junction is treated in two cycles, at least. Likewise it is possible to carry through up to three cycles at outgoing lateral branches

or incoming high-volume perforator veins. The catheter is withdrawn in 6.5 cm steps, with the vein being heated to 120° per cycle [Figures 15-24].

In general, all truncal veins can be treated by the catheter without any problems. Likewise, truncal vein recurrences can be treated; where necessary with an additional foam sclerotherapy via the guide-wire channel of the catheter. With a combination of this sort it is recommended that the Polidocanol™ foam be applied first and the catheter then purged with NaCl solution, since otherwise an explosive mixture might develop because of the heat of the catheter.^[26] The advantage of the ClosureFast™ catheter has also been its biggest disadvantage so far. The length of the heating element made it possible to treat the truncal veins quickly, but with this configuration the catheter could be used on the truncal vein only. Here the catheter worked significantly faster than the laser.^[17] Due to the 7.5 cm long heating element a vein segment with a length of at least 10-15 cm is required so that the catheter can be securely introduced into the vein. Normally this is too long, in particular when the accessory veins are to be treated in the same session. For this reason Covidien introduced a catheter with a short heating element of 3 cm this spring. Now the radiofrequency catheter ClosureFast™ can also be used to treat short vein segments.

The second radiofrequency technique by means of RFITT™ is far from being as widely spread as the ClosureFast technique. The number of publications dealing with this technique is also still limited. The RFITT™ catheter too is introduced using the Seldinger technique into the vein to be treated. In compliance with a consensus conference of August 2011^[27] the generator is preset to 18 watts. A withdrawal rate of between 2.5 and 6 s/cm is recommended, depending on the vein diameter, with the first 10 cm being treated twice. The surgery can be carried through in tumescent anaesthesia as well. The BRITTIV study^[28] describes a closure rate of 89% after 130 days. Therefore a lower withdrawal rate is recommended in case of larger vein diameters.^[29] This, however, has the disadvantage that the catheter has to be carbonized more frequently and, in some cases, has to be pulled out several times for cleaning and then re-introduced.

Endoluminal laser therapy

The endoluminal laser therapy has gone through many changes since its introduction. Initially laser generators with wavelengths of between 810 and 980 nm were used. The current lasers use wavelengths from 1320 to 1470 nm. They differ in their absorption behavior [Figure 25].

Whereas the lasers with low wavelengths mainly have a good absorption in hemoglobin, the higher laser




Figure 14: ClosurePlus catheter




Figure 15: ClosureFast generator (VNUS Medical)




Figure 16: ClosureFast catheter

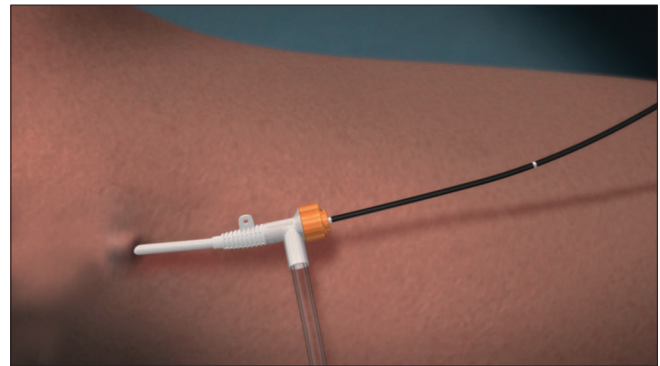


Figure 17: ClosureFast treatment (animation)

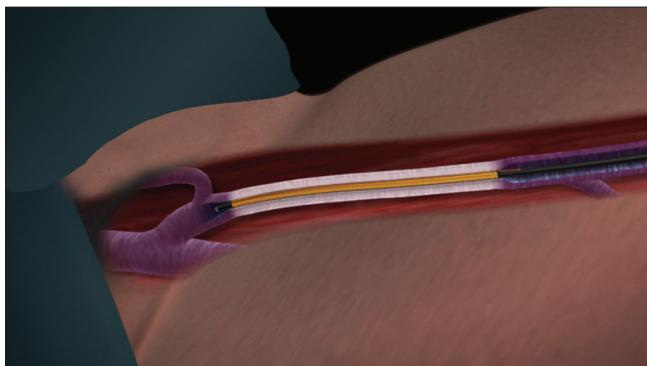


Figure 18: ClosureFast treatment (animation)

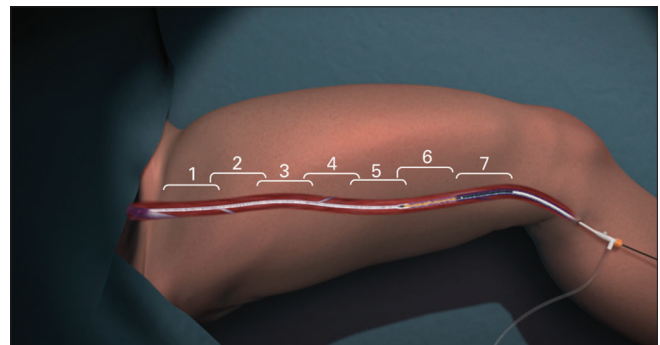


Figure 19: ClosureFast treatment (animation)

wavelengths are particularly well absorbed in water. The laser fibers used have also developed significantly. Initially a smoothly cut laser fiber (bare fiber) with a diameter of 600 μm was used. It was introduced into the vein via a long guiding catheter. The guiding catheter was placed by means of a J-type guide-wire under ultrasound assistance near the sapheno-femoral junction using the Seldinger technique. The treatment was also

performed in tumescent anaesthesia. When tumescent anaesthesia is used, the temperature around the treated veins does not exceed 32° Celsius.^[30] The linear endovenous energy density (LEED in J/cm) is decisive for the efficiency of endoluminal laser therapy.^[12] At first, energy densities as low as 25 J/cm were used. In order to optimize the results, the energy doses were temporarily increased to 120 to 150 J/cm, which resulted primarily in an increase in side effects. This led to an energy density of 60-80 J/cm being recommended.^[31] Most patients were treated with this recommended energy dose. In doing so, it was possible to improve the closure rates while also

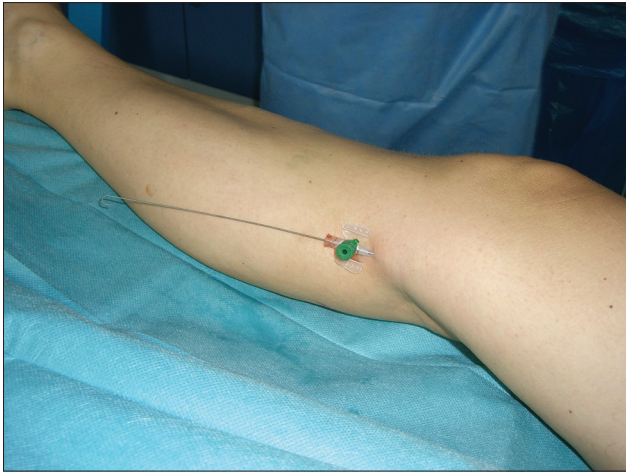


Figure 20: ClosureFast treatment (impressions)

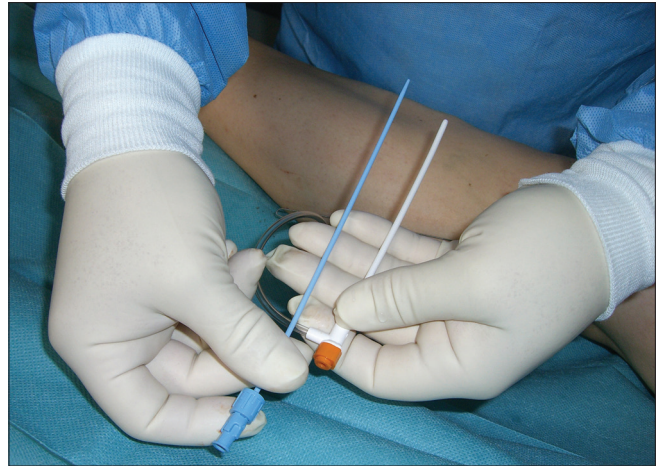

Figure 21: ClosureFast treatment (impressions)

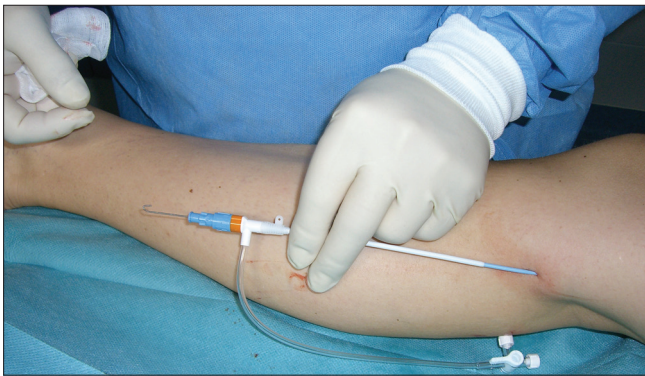


Figure 22: ClosureFast treatment (impressions)

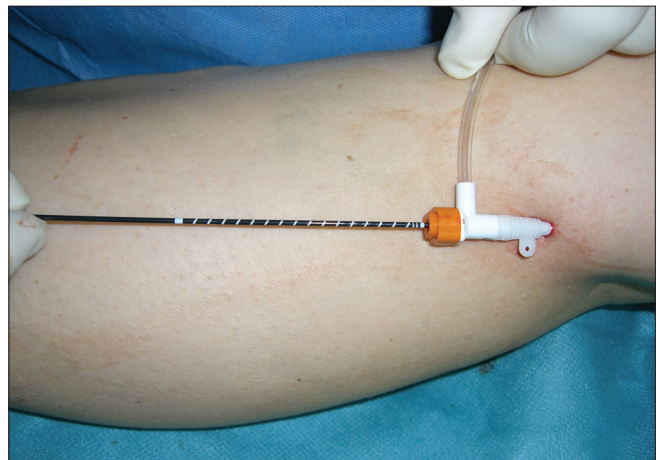


Figure 23: ClosureFast treatment (impressions)

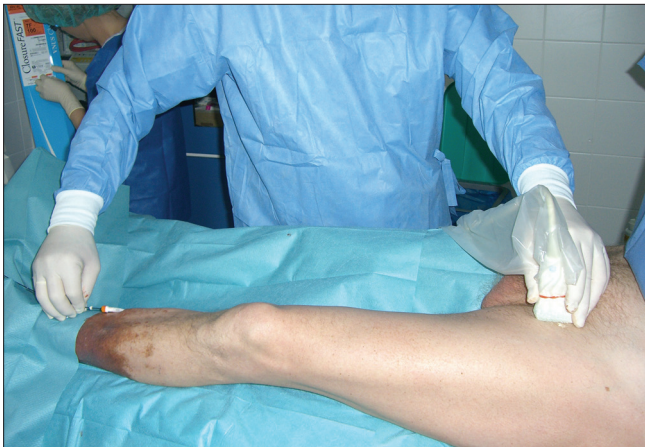

Figure 24: ClosureFast treatment (impressions)

reducing the level of side effects. The main side effects reported were pain, paraesthesias and ecchymoses.^[32-34] Furthermore, a continuous withdrawal of the catheter replaced the initially pulsed withdrawal of the fiber. The pulsed mode caused perforations of the veins and, as a consequence, larger ecchymoses. The majority of clinical studies focus on treatments with low laser wavelengths. Here a power range of between 10 and 15 watts was used. It is pointed out that high power along with a

short application time tends to have an evaporating effect, and low power along with a longer application time has a coagulating and shrinking effect.^[35] In case of lasers with a lower wavelength and use of a bare fiber steam bubbles develop in the vein during the continuous withdrawal, which release the generated heat into the vein wall, thereby destroying the same.^[34]

In a multicenter study the 980-nm laser (treatment with bare fiber) was found to be inferior to the radio wave ClosureFast™ catheter in the treatment of identical patient populations with respect to quality of life and side effect rate. The closure rate of the treated veins was 100% in both treatment arms after a month.^[17]

In recent years there has been a trend towards the use of lasers with higher wavelengths of 1320 and 1470 nm. Due to the higher absorption in water these lasers exhibit a stronger effect on the vein wall.^[36] As a result, it has proved possible to substantially reduce the number of side effects. Three years ago the radial emitting catheter with a laser ring (ELVeS radial™) was introduced in the treatment of truncal veins. Combined with the 1470-nm

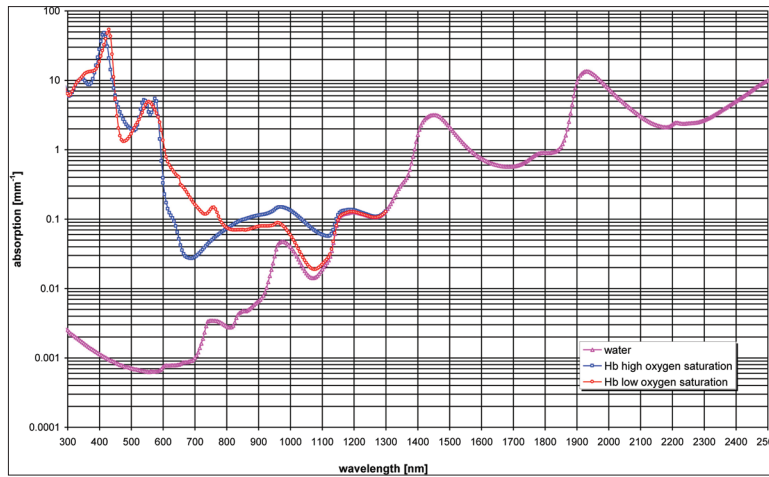


Figure 25: Absorption of pure water and a hemoglobin solution

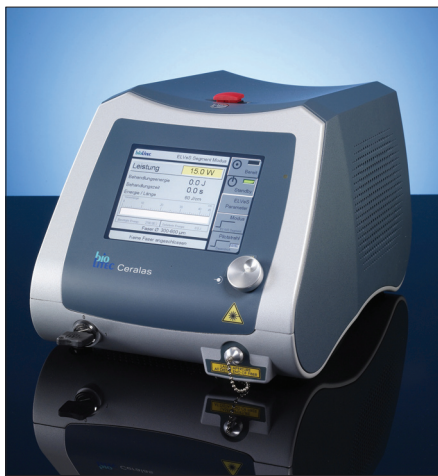

Figure 26: ELVeS generator (biolitec)

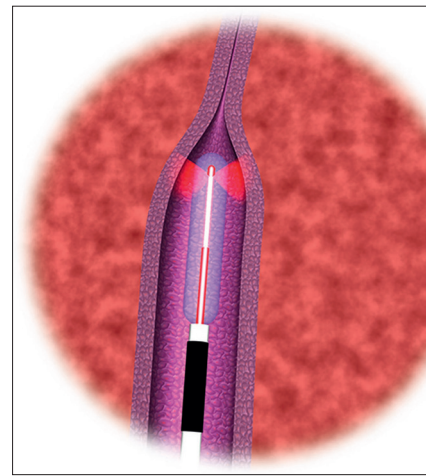


Figure 27: ELVeS radial laser (animation)



Figure 28: ELVeS laser fiber with one radial emitting laser rings




Figure 29: ELVeS laser fiber with two radial emitting laser rings

laser the side effects of the laser treatment were further reduced. Especially the number of ecchymoses, the frequency of periphlebitis and post-operative pain and paraesthesias (tenderness) were reduced considerably in comparison with the bare fiber and the lasers with a lower wavelength.^[33] At the same time the primary closure rates remained optimal. Compared to the bare fiber, which was applied with a laser power of 15 watts,

the power could be reduced to 10 watts. Here the recommended energy density is between 60 and 80 J/cm. On the laser tip a temperature of 120° is developed.^[16] This spring the biolitec company introduced a novel laser fiber with two radial emitting laser rings. In this fiber the power is divided between the two laser rings and is 50% each. The power of the laser is increased again to 15

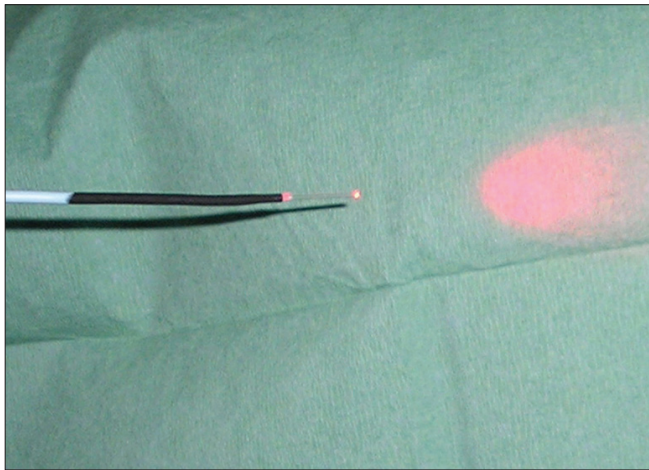


Figure 30: Laser bare fiber

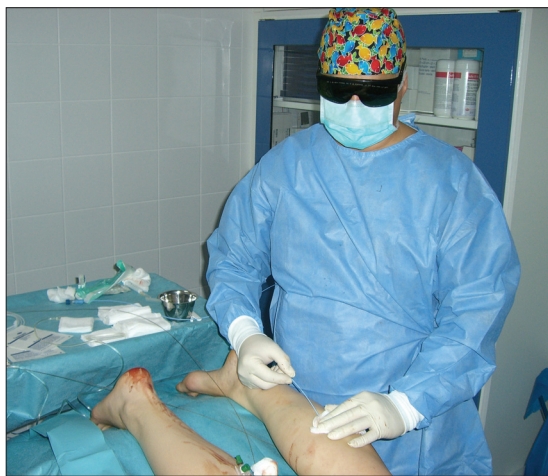

Figure 31: Laser treatment (impression)

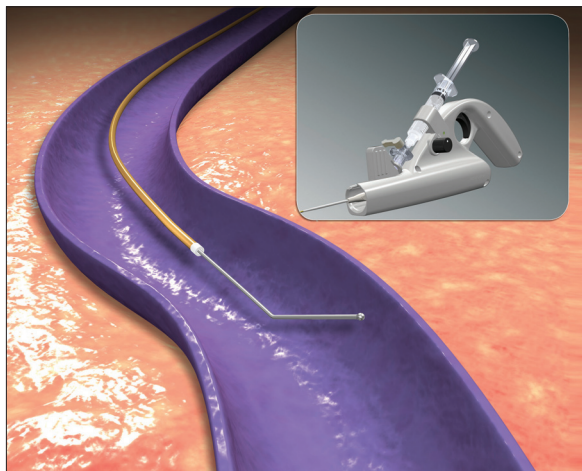


Figure 32: ClariVein

watts and is divided by two to achieve 7.5 watts per laser ring. Thus the temperature on the fiber tip is reduced to 100 degrees. The area of energy emission is twice of that of the one-ring fiber. As a result it is possible to work still more carefully and faster. The tissue is irradiated

for a longer period with less power. With a longer irradiation time the tissue (vein) can coagulate even more thoroughly. The advantages of the laser remain unaffected even in the treatment of short vein segments. A further novel laser fiber is the Tulipa fiber™. It offers the advantage that the fiber is intraluminally centered because the expanded members on the fiber tip keep the fiber away from the vein wall. Initial results indicate that, in comparison with the bare fiber, the number of ecchymoses and post-operative pains can also be reduced [Figures 26-31].^[37]

Further endoluminal techniques

In 2009 a technique with hot steam (Steam Vein Occlusion: SVO™) was introduced in the treatment of varicosis. The SVO™ catheter has to be connected to compressed air. The generator produces 120° hot steam which is released into the vein via a handpiece and a screwed-on catheter. Prior to this the catheter is placed 3 cm in front of the sapheno-femoral junction using the Seldinger technique. While the catheter is pushed back centimeter by centimeter, corresponding impulses are released. In intubation narcosis an additional tumescent anaesthesia can be dispensed with, in contrast to the techniques described above. Very little data is available on this method. Most papers published are proof-of-principle studies. Treatment results have not yet shown satisfying closure rates. In 6 out of 20 treated veins short-segment rechannelizations were identified after 6 months.^[38] The postulated advantage of this technique is the possibility of treating the truncal veins and all, even meandering, lateral branches. The truncal veins are treated by means of the SVO™ catheter, whereas in the treatment of the lateral branches the SVO™ handpiece is placed directly onto the permanent intravenous catheter. The lateral branches are punctured at intervals of 10 cm by the permanent intravenous catheter. Due to the exclusive puncture there is no scarring. The low pain records of the patients after the treatment are also described. All in all, this technique still has to prove itself.

Another technique published only last year is the endoluminal treatment using the ClariVein™ catheter. In contrast to the techniques described above it is a non-thermal catheter sclerotherapy. The ClariVein™ catheter is inserted into the vein directly via an 18G peripheral venous catheter without the help of an introducer sheath. When the catheter engages in the handle an angled tip on the catheter comes out. The catheter tip is placed 0.5 cm below the sapheno-femoral junction. By means of a motor in the handpiece the angled tip of the catheter rotates at 3500 rpm in the vessel, thus causing a vein spasm and damage on the endothelium. The catheter is withdrawn at a rate of 5 s/cm. The sclerosing agent (Aethoxysclerol™) which is supplied at the same time continuously below the rotating tip is homogeneously distributed by the

rotation and introduced into the vein wall. This is assisted by the damage of the endothelium. This finally leads to the closure of the vein. Thermal damages and nerve lesions are excluded with this process [Figure 32].^[39,40]

SUMMARY

Taken as a whole, endoluminal treatment techniques today play an essential role in the treatment of varicosis. The early and mid-term treatment results achieved by endoluminal laser therapy and radio wave therapy with ClosureFast™ are at least as good as those of the traditional stripping operations, not to mention the considerably lower complication rates and a greater patient comfort. Although these two treatment techniques are used in a standardized manner, they, too, are subject to further developments. The objective is to further enhance patient comfort and to achieve permanently optimal closure rates of the treated veins. The RFITT™ treatment has not yet been studied sufficiently; in particular there is still a lack of randomized studies looking at longer-term treatment results. The hot-steam and ClariVein™ treatments are still too new on the market to allow us to pass any judgement at this stage.

REFERENCES

1. Kluess HG, Noppeney T, Breu FX. Guidelines for the diagnosis and treatment of varicose vein disease. *Phlebologie* 2010;39:271-89.
2. Rabe E, Pannier-Fischer F. NER venous study of the German Society of Phlebology. *Phlebologie* 2003;32:1-14
3. Mumme A, Burger B, Hummel T. Der lang belassene Saphenastumpf (The long untreated Saphenastumpf). *Phlebologie* 2007;36:256-9.
4. Lurie F, Creton D, Eklof B, Kabnick LS, Kistner RL, Pichot O, *et al.* Prospective randomized study of endovenous radiofrequency obliteration (closure procedure) versus ligation and stripping in a selected patient population (EVOVeS-Study). *J Vasc Surg* 2003;38:207-14.
5. Fassiadis N, Kianifard B, Holdstock JM, Whiteley MS. Ultrasound changes at the saphenofemoral junction and in the long saphenous vein during the first year after VNUS closure. *Int Angiol* 2002;21:272-4.
6. Gloviczki P. Credentialing, quality control and education. *Endovascular Today* 2004;(Suppl.):28-9.
7. Luebcke T, Brunkwall J. Systematic review and metaanalysis of endovenous radiofrequency obliteration, endovenous laser therapy and foam sclerotherapy for primary varicosis. *J Cardiovasc Surg* 2008;49:213-33.
8. Noppeney T, Noppeney J, Winkler M. Update der Ergebnisse nach Radiofrequenzobliteration zur Ausschaltung der Varikose (Update the results after the elimination of varicose veins Radiofrequenzobliteration). *Gefäßchirurgie* 2008;13:258-64.
9. Perrin M. Endoluminal treatment of varicose veins of lower members Endovenous laser and radiofrequency. Review of the literature on 1 March 2004. *Phlebologie* 2004; 57: 125-33
10. Rautio T, Ohimmaa A, Perälä J, Ohtonen P, Heikkinen T, Wiik H, *et al.* Endovenous obliteration versus conventional stripping operation in the treatment of primary varicose veins: A randomized Controlled trial with comparison of Costs. *J Vasc Surg* 2002;35:958-65.
11. van den Bos RR, Arends L, Kockaert M, Neumann M, Nijsten N. Endovenous Therapies of lower extremity varicosities: A meta-analysis. *J Vasc Surg* 2009;49:230-9.
12. van den Bos RR, Kockaert MA, Neumann HA, Nijsten T. Technical review of endovenous laser therapy of varicose veins. *Eur J Vasc Endovasc Surg* 2008;35:88-95.
13. Disselhoff BC, der Kinderen DJ, Kelder JC, Moll FL. Randomized clinical trial comparing endovenous laser ablation of the great saphenous vein with and without ligation of the sapheno-femoral junction: 2-year results. *Eur J Vasc Endovasc Surg* 2008;36:713-8.
14. Bone C. Varicosis endoluminal treatment of the laser diode, preliminary study. *Rev Patol Vasc* 1999; 5:35-46
15. Navarro L, Min RJ, Bone C. Endovenous laser: a new minimally invasive method of treatment for varicose vein-preliminary observations using an 810-nm diode laser. *Dermatol Surg* 2001;27:117-22.
16. Sroka R, Weick K, Sadeghi-Azandaryani M, Steckmeier B, Schmedt CG. Endovenous laser therapy- application studies and latest investigations. *J Biophotonics* 2010;3:269-76.
17. Almeda JI, Kaufman J, Göckeritz O, Chopra P, Evans MT, Hoheim DF, *et al.* Radiofrequency Endovenous ClosureFAST versus Laser Ablation for the Treatment of Great Saphenous Reflux: A Multicenter, Single-blinded, Randomized Study (RECOVERY Study). *J Vasc Interv Radiol* 2009;20:752-9.
18. Proebstel TM, Alm J, Göckeritz O, Wenzel C, Noppeney T, Lebard C, *et al.* Three-year European follow-up of endovenous radiofrequency-powered segmental thermal ablation of the great saphenous vein with or without treatment of calf varicosities. *J Vasc Surg* 2011;54:146-52.
19. Welch HJ. Endovenous ablation of the great saphenous vein may avert phlebectomy for branch varicose veins. *J Vasc Surg* 2006;44:601-5.
20. Agus G, Mancini S, Magi G for the IEWG. The first 1000 cases of Italian Endovenous-laser Working Group (IEWG). Rationale and long-term outcomes for the 1999-2003 period. *Int Angiol* 2006;25:209-15.
21. Goldman MP. Regarding "Deep vein thrombosis after radiofrequency ablation of greater saphenous vein". *J Vasc Surg* 2005;41:737-8.
22. Kabnick L. Endolaser venous system (980-nm) for the treatment of saphenous venous insufficiency: 7611 limbs. *Endo Laser Vein system, Rio UIP*, 2005. p. 63-9.
23. Spreafico G, Kabnick L, Berland TL, Cayne NS, Maldonado TS, Jacobowitz GS, *et al.* Laser saphenous ablations in more than 1000 limbs with long-term duplex examination follow-up. *Ann Vasc Surg* 2011;25:71-8.
24. Mozes G, Kalra M, Carmo M, Swenson L, Gloviczki P. Extension of saphenous thrombus into the femoral vein: A potential complication of new endovenous ablation techniques. *J Vasc Surg* 2005;41:130-5.
25. Creton D, Pichot O, Sessa C, Proebstel TM; ClosureFast Europe Group. Radiofrequency-powered segmental thermal obliteration carried out with the ClosureFast procedure: Results at 1 year. *Ann Vasc Surg* 2010;24:360-6.
26. Hartmann K. Tips and Tricks for VNUS ClosureFast therapy of varicose veins. *Phlebologie* 2011;40:221.
27. Tesmann JP, Greiner A, Hartmann K, Hausmann F, Lahl W, *et al.* Hamburger consensus meeting on the radio-frequency-induced thermotherapy (RFITT) Vol 1. [In Press].
28. Camci M, Harnoss B, Akkersdijk G. Effectiveness and tolerability of bipolar radiofrequency-induced thermotherapy for the treatment of incompetent saphenous veins. *Phlebologie* 2009;38:5-11.
29. Boon R, Akkersdijk GJ, Nio D. Percutaneous treatment of varicose veins with bipolar radiofrequency ablation. *Eur J Radiol* 2010;75:43-7.
30. Lahl W. Thermometric investigations of the perivenous temperature during endovenous laser therapy of varicose veins, Paper presented at the 15th World Congress of the Union Internationale de Phlébologie; October 2-7, 2005; Rio de Janeiro, Brazil, veröffentlicht Zentralbl Chir. Vol 131. 2006. p. 45-50.
31. Timperman PE, Sichlau M, Ryu RK. Greater energy delivery improves treatment success of endovenous laser treatment of incompetent saphenous veins. *J Vasc Interv Radiol* 2004;15:1061-3.
32. Kabnick LS. Outcome of different endovenous laser wavelengths for great saphenous vein ablation. *J Vasc Surg* 2006;43:88-93.

33. Pannier F, Rabe E, Rits J, Kadiss A, Maurins U. Endovenous laser ablation of great saphenous veins using a 1470 nm diode laser and the radial fibre – follow-up after six months. *Phlebology* 2011;26:35-9.
34. Pröbstle TM, Moehler T, Gul D, Herdemann S. Endovenous treatment of the great saphenous vein using a 1320-nm Nd:YAG laser causes fewer side effects than using a 940-nm diode laser. *Dermatol Surg* 2005;31:1678-84.
35. Corcos L, Dini S, De Anna D, Marangoni O, Ferlaino E, Procacci T. The immediate effects of endovenous diode 808-nm laser in greater saphenous vein: Morphologic study and clinical implications. *J Vasc Surg* 2005;41:1018-24.
36. Almeda J, Mackay E, Javier J, Maurillo J, Raines J. Saphenous laser ablation at 1470 nm targets the vein wall, not blood. *Vasc Endovascular Surg* 2009;43:467-72.
37. Vuylsteke ME, Thomis S, Matieu P, Mordon S, Fourneau I. Endovenous laser treatment of saphenous vein using bare fiber versus fiber Tulipa, short-term results of Tulip Trials. *Vasomed* 2011;Ausgabe 5:233-4.
38. van den Bos RR, Milleret R, Neumann M, Nijsten T. Proof-of-principle study of steam ablation as novel thermal therapy for saphenous varicose veins. *J Vasc Surg* 2011;53:181-6.
39. Elias S, Raines JK. Mechanochemical tumescentless endovenous ablation: final results of the initial clinical trial. *Phlebology* 2011;40:1-6.
40. van Eekeren RR, Boersma D, Elias S. Endovenous mechanochemical ablation of great saphenous vein incompetence using the ClariVein device: A soft study. *J Endovasc Ther* 2011;18:328-34.

How to cite this article: Göckeritz O. Current standards and recent progress in minimally invasive phlebo surgery. *J Cutan Aesthet Surg* 2012;5:104-14.

Source of Support: Nil. **Conflict of Interest:** None declared.