

## Subungual Glomus Tumour Excision with Transungual Approach with Partial Proximal Nail Avulsion

Dear Editor

Glomus tumour is a benign vascular hamartoma containing neuromyoarterial cells of normal glomus apparatus first described by Barre and Masson in 1924.<sup>[1]</sup> The knowledge of this entity and surgical skill is necessary to prevent delay in diagnoses and the treatment. We report a case of subungual glomus tumour successfully excised with transungual approach with partial nail avulsion.

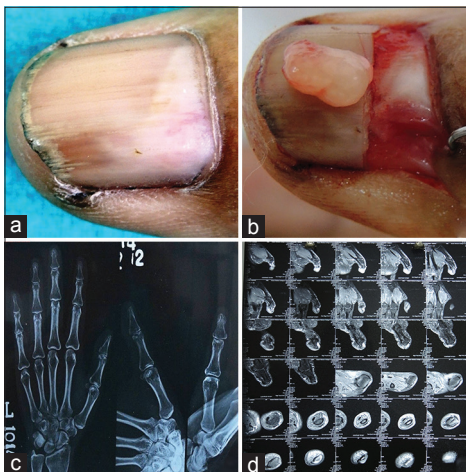
A 58-year-old female presented with pain on the left thumb for 12 years which was gradually increasing in the last 3 years. The pain was worse with exposure to cold water or when she bumped the thumb. There was no other significant medical history.

The general and systemic physical examination was within normal limit. On local examination, there was a violaceous spot on the lunula and longitudinal ridging on the nail plate [Figure 1a]. The love test (applying pressure to the suspected area with a pinhead, which elicits exquisite localised pain) was positive. The posterior-anterior and lateral view of X-ray left hand was normal [Figure 1c]. Magnetic resonance imaging of the left thumb revealed T1 hypointense, T2/T2-FS hyperintense spherical mass showing intense enhancement on the post-contrast

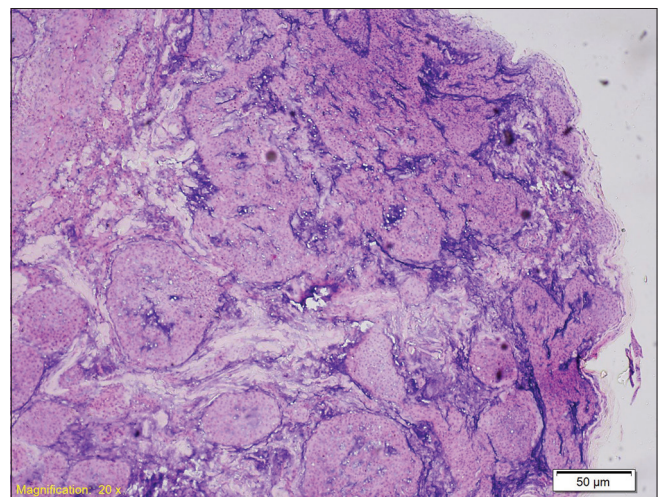
study of distal phalanx suggestive of glomus tumour [Figure 1d].

The glomus tumour was excised with distal digital block as anaesthesia. The nail plate was marked with a surgical marker at the location of the tumour. Proximal nail avulsion was done to expose the nail bed tumour. The nail bed was sectioned longitudinally over the tumour. The tumour was very meticulously dissected from the surrounding tissue with blunt curved scissors [Figure 1b]. The incision was closed with 4-0 vicryl suture. The nail plate was put back in place as a physiological covering and secured to lateral and proximal nail folds. The tumour was sent for histopathology which showed glomus tumour [Figure 2]. There is no pain or recurrence at 2 years follow-up.

The classic triad of symptoms of subungual glomus tumour are severe pain, pinpoint tenderness and temperature sensitivity. With the classical triad of symptoms, glomus tumour can be diagnosed clinically. However, the mean duration of symptoms until diagnosis was 4.6 years (range 1 month to 20 years)<sup>[2]</sup> and 4.5 years (range, 6 months to 10 years).<sup>[3]</sup> In our patient, it took 12 years for proper diagnosis after visiting many different speciality clinics. Bhaskaranand and Navadgi in their study of 18 patients revealed that the cold sensitivity test was 100% sensitive, specific and accurate;



**Figure 1:** (a) Violaceous spot suggesting location of glomus tumour with longitudinal ridging, (b) excised glomus tumour kept on the nail plate, (c) X-ray of the left hand, (d) magnetic resonance imaging of the left thumb



**Figure 2:** Histopathology showing features of glomus tumour (H and E, ×100)

Table 1: Comparison of different surgical approach for excision of glomus tumour of nail unit

Modification (author)	Transungual approach		Lateral approach		
	Advantage	Disadvantage	Modification (author)	Advantage	Disadvantage
Transungual approach without nail extraction (Roan <i>et al.</i> <sup>[5]</sup> )	Simple, low recurrence rate. With no nail extraction, the patient feels less post-operative pain	No post-operative nail deformity reported with this technique. However, the author reported post-operative nail deformity in 24.1% in traditional transungual approach	Lateral subperiosteal approach (Vasisht <i>et al.</i> <sup>[6]</sup> )	This approach affords a direct access to the subungual area without the need to dissect out and retract any ligamentous structures and the nail plate and nail bed There was no post-operative nail deformity	The tumours located close to the germinal matrix are difficult and require more meticulous technique The recurrence was in 15.7%
Eponychial flap (Ekin <i>et al.</i> <sup>[7]</sup> )	Simple to reach the glomus tumour under the proximal unguis bed and it causes a minimal defect	It is not useful for glomus tumour in distal nail bed	Periungual approach (Fong <i>et al.</i> <sup>[8]</sup> )  Nail bed margin approach (Wang <i>et al.</i> <sup>[9]</sup> )	The nail plate, nail bed and tumour are elevated together. This minimises handling of the nail bed  It allows direct access to the subungual area without splitting the nail bed The germinal matrix tumour can also be adequately excised	The major concerns are the injury to the germinal matrix while elevating the nail and nail bed The nail plate has to be completely removed

Hildreth's test was 71.4% sensitive, 100% specific and 78% accurate; and the love pin test was 100% sensitive and 78% accurate.<sup>[4]</sup>

The only effective treatment of subungual glomus tumour is complete surgical excision. Many surgical approaches have been reported to excise the tumour.<sup>[2,3]</sup> The standard approach is a direct transungual excision. The different surgical approach for excision of glomus tumour is illustrated in Table 1. Van Geertruyden *et al.*<sup>[10]</sup> performed transungual resection in 30 subungual tumours. They reported 6.6% recurrence and a post-operative incidence of nail deformity of 3.3%. Traditionally, a complete nail avulsion is done to expose the tumour. However, in our patient, we did partial nail avulsion to excise the tumour. The transungual approach with partial nail plate removal helps in less post-operative pain and faster healing as the area of surgery is less. It also helps in proper growth of nail as there are no chances of distal nail embedding in the case of proximal nail avulsion as in our case.

**Financial support and sponsorship**  
Nil.

#### Conflicts of interest

There are no conflicts of interest.

**Binod Kumar Thakur, Shikha Verma, Ankit Jitani<sup>1</sup>**

Departments of Dermatology and STD and <sup>1</sup>Pathology, North Eastern Indira Gandhi Regional Institute of Health and Medical Sciences, Shillong, Meghalaya, India

**Address for correspondence:** Dr. Binod Kumar Thakur, Department of Dermatology and STD, North Eastern Indira Gandhi Regional Institute of Health and Medical Sciences, Shillong - 793 018, Meghalaya, India.  
E-mail: binod.k.thakur@gmail.com

#### REFERENCES

- Barre JA, Masson PV. Anatomy-clinical study of certain painful sub-ungual tumors (tumors of neuromyo-arterial glomus of the extremities). *Bull Soc Dermatol Syphiligr* 1924;31:148-59.
- Song M, Ko HC, Kwon KS, Kim MB. Surgical treatment of subungual glomus tumor: A unique and simple method. *Dermatol Surg* 2009;35:786-91.
- Muramatsu K, Ihara K, Hashimoto T, Tominaga Y, Taguchi T. Subungual glomus tumours: Diagnosis and microsurgical excision through a lateral subperiosteal approach. *J Plast Reconstr Aesthet Surg* 2014;67:373-6.
- Bhaskaranand K, Navadgi BC. Glomus tumour of the hand. *J Hand Surg Br* 2002;27:229-31.
- Roan TL, Chen CK, Horng SY, Hsieh JH, Tai HC, Hsieh MH, *et al.* Surgical technique innovation for the excision of subungual glomus tumors. *Dermatol Surg* 2011;37:259-62.
- Vasisht B, Watson HK, Joseph E, Lionelli GT. Digital glomus tumors: A 29-year experience with a lateral subperiosteal approach. *Plast Reconstr Surg* 2004;114:1486-9.
- Ekin A, Ozkan M, Kabaklioglu T. Subungual glomus tumours: a different approach to diagnosis and treatment. *J Hand Surg Br* 1997;22:228-9.

8. Fong ST, Lam YL, So YC. A modified periungual approach for treatment of subungual glomus tumour. *Hand Surg* 2007;12:217-21.
9. Wang PJ, Zhang Y, Zhao JJ. Treatment of subungual glomus tumors using the nail bed margin approach. *Dermatol Surg* 2013;39:1689-94.
10. Van Geertruyden J, Lorea P, Goldschmidt D, de Fontaine S, Schuind F, Kinnen L, *et al.* Glomus tumours of the hand. A retrospective study of 51 cases. *J Hand Surg Br* 1996;21:257-60.

This is an open access article distributed under the terms of the Creative Commons Attribution-NonCommercial-ShareAlike 3.0 License, which allows others to remix, tweak, and build upon the work non-commercially, as long as the author is credited and the new creations are licensed under the identical terms.

**Access this article online****Quick Response Code:****Website:**

[www.jcasonline.com](http://www.jcasonline.com)

**DOI:**

10.4103/0974-2077.191654

**How to cite this article:** Thakur BK, Verma S, Jitani A. Subungual glomus tumour excision with transungual approach with partial proximal nail avulsion. *J Cutan Aesthet Surg* 2016;9:207-9.