

Favre-Racouchot Syndrome with Bilateral Mechanical Ptosis: An Unusual Presentation

Dear Editor,

A 60-year-old woman presented to ophthalmology outpatient department with difficulty in opening both eyelids since 6 months. Multiple nodules on both the eyelids were present since many years, but were ignored in the absence of symptoms. However, she noticed an inability to keep the eyes completely open and a mild drooping of the upper eyelids since 6 months. She spent 5-6 hours of the day in sunlight. She gave no history of intake of tobacco/smoking (active or passive) or radiation therapy or application of any medicine to the face or eyes.

Ocular examination revealed presence of multiple giant comedones on the upper eyelids in both eyes. The lesions were pedunculated and their size varied from 0.5 mm to 10 mm. There were about 5-6 lesions on the upper eyelid in each eye [Figures 1 and 2]. There were no signs of infection or inflammation. The margin reflex distance (MRD1) measured 3 mm in right eye and 2 mm in left eye. Palpebral aperture measured 8 mm vertically and 27 mm horizontally in right eye, while left eye measurements were 6 mm vertically and 27 mm horizontally. Anterior segment and fundus examination were found to be normal in both eyes. The best corrected visual acuity in both eyes was 20/20 for distance and N6 for near.

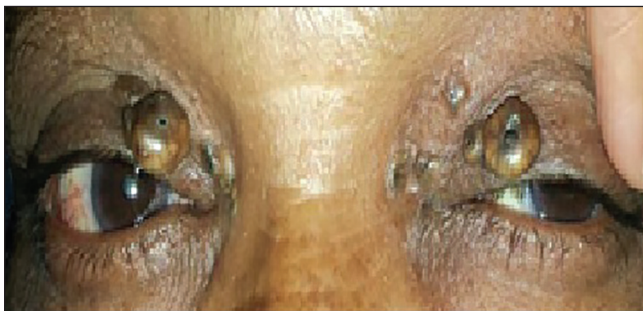


Figure 1: Preoperative photograph showing giant comedones in both eyelids with mild ptosis

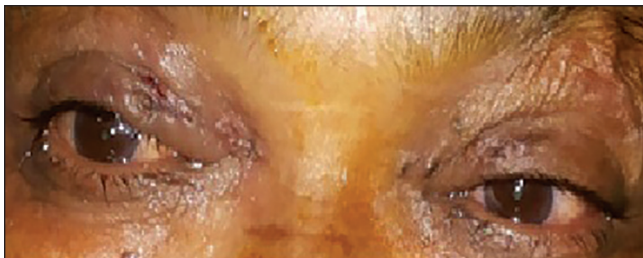

Figure 3: Immediate post-op photograph showing cosmetic improvement

Other causes of ptosis were ruled out. Routine blood tests were within normal limits, and the patient tested negative for Hepatitis B and HIV. The patient was taken up for surgical excision of the comedones under local anaesthesia using 2% lignocaine. Redundant skin was excised and sutures using 6-0 Vicryl® were placed [Figures 3 and 4]. Histopathology report showed cysts lined by stratified squamous epithelium filled with lamellated keratin, suggestive of epithelial inclusion cyst. Two weeks after surgery, the patient showed improvement in lid position. The patient was advised to wear sun protective goggles when outdoors.

Favre Racouchot syndrome is named after the French dermatologist Maurice Favre and his pupil Jean Racouchot. It was described in 1932 by Favre and then reviewed in detail by Favre and Racouchot in 1951.^[1] It is a skin condition consisting of multiple open comedones that are seen in skin damaged by sunlight, especially under and lateral of the eyes. It is said to affect 6% of population in the age group of 50-70 years though there have been instances of it being reported in younger individuals.^[1]

The characteristic solar elastosis refers to damage to dermal elastic tissue from chronic exposure to UVA and UVB radiation. It is most often seen in the periorbital area^[2] though it can be seen in other parts of the face and neck

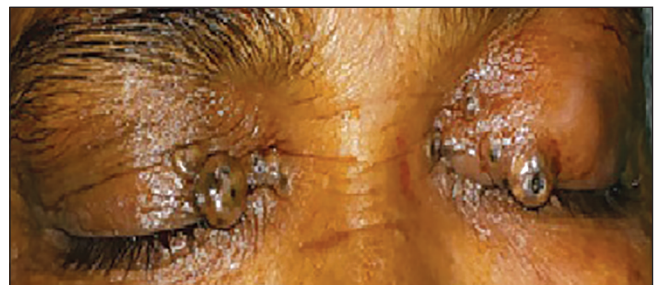

Figure 2: Before surgery

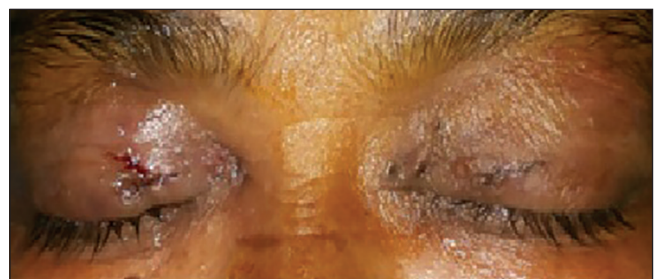

Figure 4: After surgery

which are exposed to sunlight. The lesions are usually bilaterally symmetrical with few exceptions of unilateral elastosis.^[3] It is also strongly associated with heavy cigarette smoking and rarely with radiation therapy.^[4]

The comedones differ from those seen in acne by the absence of inflammation. Differential diagnosis includes acne vulgaris, epidermoid cysts, sebaceous hyperplasia and colloid milium. Protection from sunlight by using sunscreens with SPF 30 and avoiding outdoors between 10 am to 2 pm is advised. Cessation of smoking is strongly advised.^[5] Treatment options available for this condition include medication such as topical retinoids and surgery such as excision, curettage, dermabrasion,^[4] comedone extraction and carbon dioxide laser ablation. Simple extraction of the lesions is followed by recurrences. Hence, all patients must be followed up at regular intervals to look out for recurrences.

Our case is unusual because it describes Favre Racouchot syndrome to be associated with giant comedones causing mechanical ptosis.

**Anupama A Kakhandaki, Leena Raveendra¹,
Pradeep A Venkataramana, Jyoti S Khandre**

Department of Ophthalmology, Sri Dharmasthala Manjunatheshwara College of Medical Sciences and Hospital, Dharwad,
¹Department of Dermatology, Rajarajeswari Medical College and Hospital sciences, Bangalore, Karnataka, India
E-mail: anupamadesaibr@gmail.com

REFERENCES

1. Jansen T, Plewig G. Favre-Racouchot disease. In: Demis DJ, editor. Clinical Dermatology. Philadelphia: Lippincott Williams and Wilkins; 1998. p. 4-44.
2. Patterson WM, Fox MD, Schwartz RA. Favre-Racouchot disease. Int J Dermatol 2004;43:167-9.
3. Moulin G, Thomas L, Vigneau M, Fiere A. A case of unilateral elastosis with cysts and comedones. Favre Racouchot syndrome. Ann Dermatol Venereol 1994;121:721-3.
4. Zhang R, Zhu W. Favre-Racouchot syndrome associated with eyelid papilloma: A case report. J Biomed Res 2012;26:474-7.
5. Keough GC, Laws RA, Elston DM. Favre-Racouchot syndrome: A case for smokers' Comedones. Arch Dermatol 1997;133:796-7.

Access this article online	
Quick Response Code: 	Website: www.jcasonline.com
	DOI: 10.4103/0974-2077.138366