



Innovations

Surgical pearl: Use of micropore tape for easy harvestation and transfer of suction blister epidermal graft

Muhammed Mukhtar¹

¹Department of Dermatology, Mukhtar Skin Centre, Katihar Medical College Road, Katihar, Bihar, India.

***Corresponding author:**

Muhammed Mukhtar,
Department of Dermatology,
Mukhtar Skin Centre, Katihar
Medical College Road, Katihar,
Bihar, India.

drmmukhtar20@gmail.com

Received: 18 March 2021
Accepted: 18 May 2021
Epub Ahead of Print: 20 September 2024
Published:

DOI

10.25259/jcas_53_21

Quick Response Code:



ABSTRACT

Epidermal graft produced by suction is useful in treating vitiligo. However, it is very difficult to handle thin, flimsy, and translucent epidermis due to its in-curling and wrinkling properties. This is due to the hemispherical blister roof surface area which is twice its circular base. The correction of the epidermal surface and its resizing is a cumbersome and time-consuming task during epidermal grafting. To combat these problems, the blister roof is patched with micropore adhesive tape as a novel technique for harvestation and transfer of the suction blister graft.

Keywords: Epidermis, Hemisphere, Incurling, Micropore, Mosquito artery forceps, Perifollicular pigmentation, Diffuse pigmentation

PROBLEM STATEMENT

Epidermal graft produced by suction is useful in treating vitiligo. However, it is very difficult to handle a thin, flimsy, and translucent epidermis due to its in-curling and wrinkling properties like a deflated balloon. This is due to the hemispherical fibrinous blister roof, whose surface area is twice its circular base. The correction, identification of the epidermal surface, and its resizing are cumbersome and time-consuming tasks during epidermal grafting.^{1,2} To combat these problems, the blister roof is patched with micropore adhesive tape as a novel technique for harvestation and transfer of the suction blister graft.

RECOMMENDED SOLUTION

The blister roof is halved into two parts with the help of small scissors or a blade. The blister fluid is drained out. Subsequently, half of the graft is spread out well on its base to make it anti-curved and anti-wrinkled with the help of small mosquito forceps. Then, a piece of micropore tape is patched 1 on half of the graft. Following this, the mosquito forceps are inserted in the blister cavity to stretch out gently its margin, and then, the incised margin of the graft is held with the forceps to detach

This is an open-access article distributed under the terms of the Creative Commons Attribution-Non Commercial-Share Alike 4.0 License, which allows others to remix, transform, and build upon the work non-commercially, as long as the author is credited and the new creations are licensed under the identical terms.

©2024 Published by Scientific Scholar on behalf of Journal of Cutaneous and Aesthetic Surgery

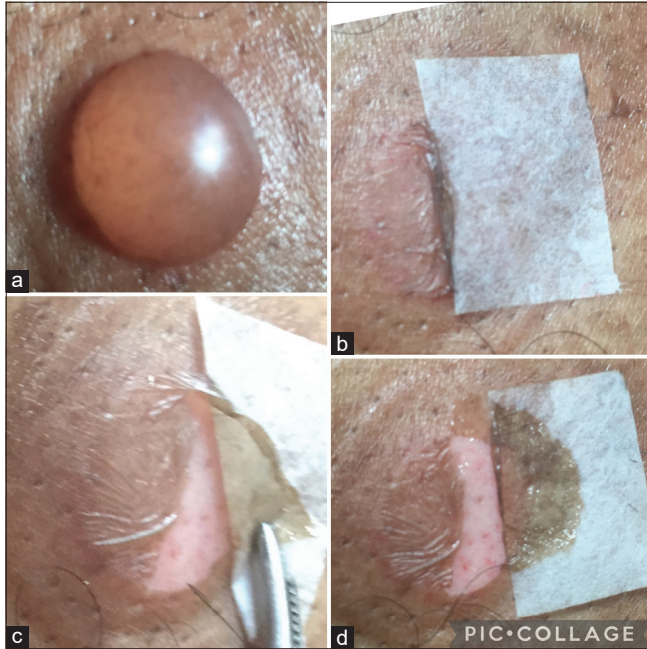


Figure 1: (a-d) The different stages of harvestation of the first half of the graft.

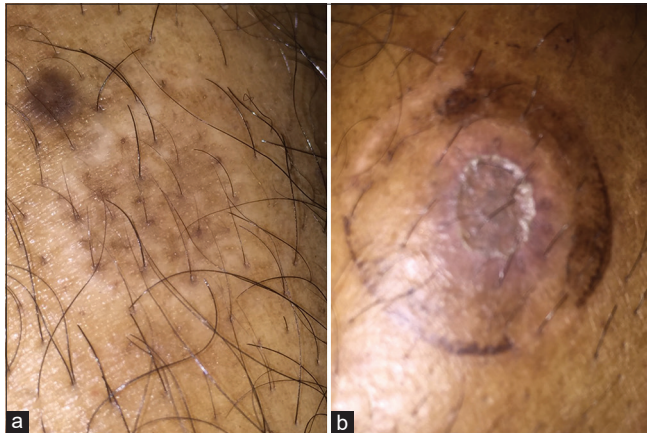

Figure 2: (a) The pigmentation of donor sites without epidermal grafting showing patchy and perifollicular pigmentation and (b) diffuse pigmentation after epidermal grafting.

from its base completely [Figure 1a-d]. The same procedure was repeated to detach the second half of the graft. During the procedure, the tape was kept dry for better adhesiveness of the tape on the graft. The tape gives strength to the delicate graft and prevents the graft from getting torn. After harvestation, the epidermis remained uncurled and unwrinkled. This graft can be resized into any size and shape. There is no problem with surface identification, in-curling, and anti-wrinkling of the graft. The graft could be handled, transferred, or

transported easily from the donor with the help of a forceps. Here, it is easily harvested, lifted, and re-grafted over the donor site. The taking of the graft does not interfere with the patching of tape which could be seen as the difference in the pattern of pigmentation (perifollicular vs. diffuse) without and with epidermal re-grafting over the donor site [Figure 2a and b]. Extra tape can be trimmed before grafting. There is no significant loss of graft on the margin and no incidence of secondary bacterial infection on a clean grafted wound.³

Authors' contributions

All works related to this article are done by the author.

Ethical approval

Institutional Review Board Approval is not required.

Declaration of patient consent

The authors certify that they have obtained all appropriate patient consent.

Financial support and sponsorship

Nil.

Conflicts of interest

There are no conflicts of interest.

Use of artificial intelligence (AI)-assisted technology for manuscript preparation

The author confirms that there was no use of artificial intelligence (AI)-assisted technology for assisting in the writing or editing of the manuscript and no images were manipulated using AI.

REFERENCES

1. Ashique KT, Srinivas CR. Resizing blister roof grafts for vitiligo surgery. *J Am Acad Dermatol* 2014; 71: e39-40.
2. Laxmisha C, Thappa DM. Surgical pearl: Gloved finger as a transport platform for epidermal graft of suction blister. *J Am Acad Dermatol* 2007; 57: S118-9.
3. Hever P, Cavale N, Pasha T. A retrospective comparison of 3M™ Micropore™ with other common dressings in cosmetic breast surgery. *J Plast Reconstr Aesthet Surg* 2019; 72:424-6.

How to cite this article: Mukhtar M. Surgical pearl: Use of micropore tape for easy harvestation and transfer of suction blister epidermal graft. *J Cutan Aesthet Surg*. doi: 10.25259/jcas_53_21