

Angiolymphoid Hyperplasia with Eosinophilia Showing Promising Result with Intralesional Radio-frequency Ablation Therapy: A New Cost-effective and Hassle-Free Modality of Treatment

Dear Editor,

A 32-year-old female presented with itchy erythematous papules and nodules of varying sizes over the scalp for the past 7 years. Lesions were progressive and bled on manipulation.

Dermatological examination revealed multiple, firm, non-tender, scaly, erythematous papules and nodules, ranging from 0.5 cm × 0.5 cm to 1.5 cm × 2 cm, few of them arranged in clusters on the posterior aspect of the scalp. General physical and systemic examinations were normal. There was no lymphadenopathy [Figure 1a and b].

A provisional diagnosis of angiolymphoid hyperplasia with eosinophilia (ALHE) was considered. Routine blood investigations were normal. Biopsy revealed numerous capillaries with prominent plump endothelial lining with surrounding dense inflammatory infiltrates in the dermis, consistent with ALHE [Figure 1c and d]. She

was put on oral steroids (prednisolone 1 mg/kg/day) and topical imiquimod (3 days in a week) for 2 months, with no improvement, which led us to opt for a newer technique, intralesional radio-frequency ablation (RFA). We employed 'Mega Surg Gold' high-frequency radiosurgery unit (dermaindia) for the procedure [Figure 2]. After local infiltration with 2% lignocaine, a 22-gauge needle was inserted with its distal 3 mm–0.5 cm (depending on the size of the lesion) inside the lesion. RFA was performed at high power in coagulation mode by touching the needle at its proximal end [Figure 3] and needle was slightly lifted with help of forceps to avoid thermal damage to the uninvolved epidermis and dermis. With single epidermal entry point, fanning technique was employed, and energy was passed for an average of 15–20 s before the change of direction of the needle. Eight sessions were performed over a period of 4 months (at 2 week interval), treating 4–5 lesions in each session. By the end of the last session, there was remarkable resolution of lesions with

minimal scarring at the treated area, which was almost invisible after the growth of surrounding hair [Figure 4]. There was no recurrence of lesions during the follow-up period of 1 year.

DISCUSSION

Although ALHE is a benign vascular tumour, it is potentially disfiguring; hence, there is a need for therapy with good curative and cosmetic result as well.

Various topical agents such as timolol, imiquimod, tacrolimus and systemic agents such as corticosteroids, propranolol, retinoids, pentoxifylline and chemotherapeutic agents such as vinblastine and mepolizumab (anti-interleukin-5) have been tried with inconsistent results. Surgical excision can be considered, but local recurrences occur in 33–50% as the lesions are often multilobulated and poorly delineated.

Photodynamic therapy, electrocautery, cryosurgery and intralesional corticosteroids, interferon alfa-2a, lasers have shown some success.^[1-4] Although there are many modalities available in the treatment of ALHE, showing variable results, none of them are completely satisfactory and cost-effective.

Intralesional RFA is a minimally invasive procedure with added advantage of less surface damage and has been employed recently in the management of ALHE. In a report of ALHE being treated with intralesional RFA, an 18 gauge intravenous cannula Venflon was used with good results.^[5] We used 22 gauge needle, which is much cheaper than the intravenous cannula for intralesional RFA without any difference in outcome. This particular method is useful for widespread lesions where medical and surgical modalities produce suboptimal results.

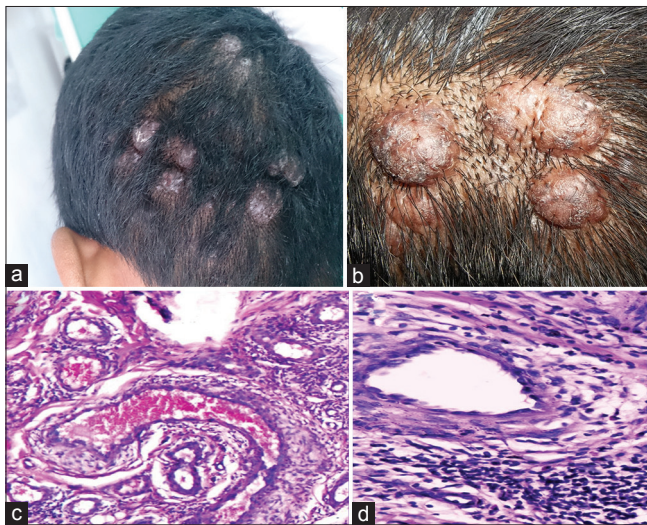


Figure 1: (a) Multiple, erythematous, papules and nodules arranged in clusters, (b) close-up view of lesions, (c) histopathology showing numerous blood vessels in the background of inflammatory infiltrate (d) close-up view of vessel lined by plump endothelial cells ‘epitheloid endothelial cells’ (H and E, ×100)

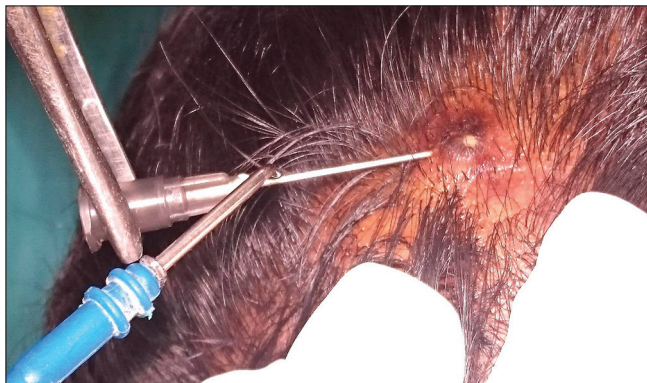

Figure 3: Intralesional radio-frequency ablation technique

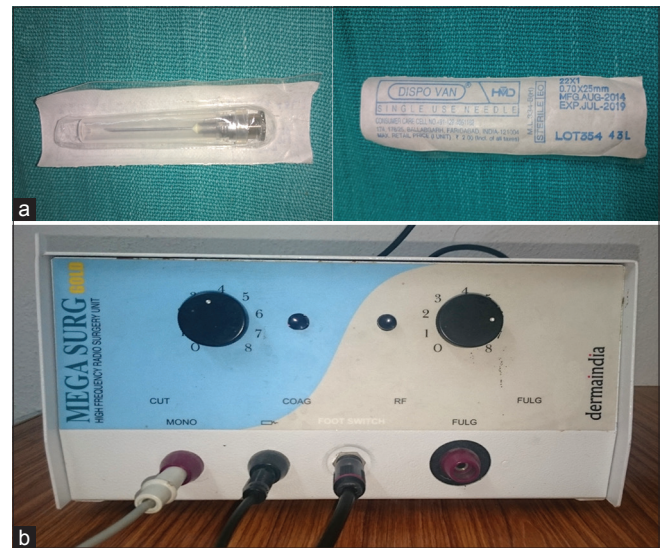

Figure 2: (a) 22-gauge sterile needle used for intralesional radio-frequency ablation and (b) radio-frequency ablation equipment

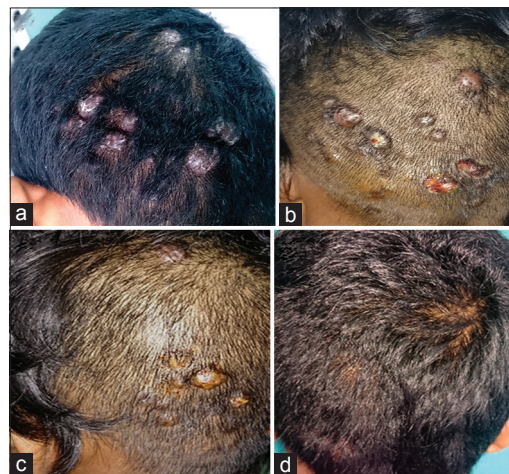

Figure 4: (a) Initial presentation of angiolymploid hyperplasia with eosinophilia, (b) at the end of the fourth session, (c) sixth session, (d) 2 weeks after the last session

Post-procedure complications include minimal scarring and depigmentation, which in areas such as scalp can be invisible/camouflaged with hair, like in our case.

This case is reported for intralesional RFA therapy being a new, cost-effective and easy-to-treat modality in the management of ALHE with a long-lasting result and no relapses, especially in limited resource settings, as it just requires an RFA and a sterile needle.

Financial support and sponsorship

Nil.

Conflicts of interest

There are no conflicts of interest.

**Chintaginjala Aruna, Senthil Kumar Alagappan,
Ramamurthy Damaraju Venkata Satya Bhaskara,
Sruthi Kondaveeti**

Department of DVL, Katuri Medical College and Hospital, Guntur,
Andhra Pradesh, India

Address for correspondence: Dr. Chintaginjala Aruna,
Department of DVL, Katuri Medical College and Hospital, Guntur,
Andhra Pradesh, India.
E-mail: draruna88@gmail.com

REFERENCES

1. Chacon AH, Mercer J. Successful management of angiolymphoid hyperplasia with eosinophilia in a split-face trial of topical tacrolimus and timolol solution. *G Ital Dermatol Venereol* 2014.

2. Lembo S, Balato A, Cirillo T, Balato N. A long-term follow-up of angiolymphoid hyperplasia with eosinophilia treated by corticosteroids: When a traditional therapy is still up-to-date. *Case Rep Dermatol* 2011;3:64-7.
3. Braun-Falco M, Fischer S, Plötz SG, Ring J. Angiolymphoid hyperplasia with eosinophilia treated with anti-interleukin-5 antibody (mepolizumab). *Br J Dermatol* 2004;151:1103-4.
4. Carlesimo M, Mari E, Tammara A, Persechino S, Camplone G. Angiolymphoid hyperplasia with eosinophilia treated with isotretinoin. *Eur J Dermatol* 2007;17:554-5.
5. Singh S, Dayal M, Walia R, Arava S, Sharma R, Gupta S. Intralesional radiofrequency ablation for nodular angiolymphoid hyperplasia on forehead: A minimally invasive approach. *Indian J Dermatol Venereol Leprol* 2014;80:419-21.

This is an open access article distributed under the terms of the Creative Commons Attribution-NonCommercial-ShareAlike 3.0 License, which allows others to remix, tweak, and build upon the work non-commercially, as long as the author is credited and the new creations are licensed under the identical terms.

Access this article online	
Quick Response Code: 	Website: www.jcasonline.com
	DOI: 10.4103/0974-2077.197088

How to cite this article: Aruna C, Alagappan SK, Bhaskara RV, Kondaveeti S. Angiolymphoid hyperplasia with eosinophilia showing promising result with intralesional radio-frequency ablation therapy: A new cost-effective and hassle-free modality of treatment. *J Cutan Aesthet Surg* 2016;9:281-3.

© 2016 Journal of Cutaneous and Aesthetic Surgery | Published by Wolters Kluwer - Medknow