

“Combination Grafting” of Scalp and Body Hair to Enhance the Visual Density of Hair Transplant and Coverage of Higher Grade of Baldness

Anil K. Garg, Seema Garg

Rejuvenate Plastic, Cosmetic and Hair Transplant Centre, Bhandari Marg, Indore, Madhya Pradesh, India

Abstract

Hair transplant is becoming the most common cosmetic procedure across the world with demand for higher density and coverage of baldness. This needs more number of donor hair follicles. Scalp donor has limitations to fulfill the required number of follicles for Norwood Grade VI and VII baldness. The body hair follicles can be used to cover up the deficit. The objective of this study was to observe the use of body hair follicles to increase the visual density and for better coverage for higher grades of baldness as an adjuvant to scalp hair follicles. **Materials and Methods:** A total of 16 patients were evaluated for the availability of body donor hair, and consent for body hair harvesting was obtained from them. The beard was the first preference and then chest and abdomen hair follicles were used in combination with scalp hair follicles to cover bald area of Norwood grade IV and above baldness. Body hairs were harvested using follicular unit extraction (FUE) technique. Postoperative pictures were taken, and patient satisfaction, doctor's observation, and global photographic evaluation was carried out. **Observations:** The patient's photographs were taken after 4, 8, and 12 months of hair transplant. The results were analyzed on the basis of global photography. The use of body hair with scalp has enhanced the visual density, leaving to better coverage in even higher grades of baldness.

Keywords: BHT, Body hair transplant, combination grafting, FUE, follicular unit extraction, NG, Norwood grade

INTRODUCTION

Hair transplant is becoming a very popular as well as a much-demanded procedure. Now the demand for higher density coverage with a normal look is increasing. This needs more number of donor hair follicles. The biggest limitation of the hair transplant procedure is the big discrepancy between demand and supply. Body hair is a good source of donor hair follicle.^[1,2] We use “combination grafting” in which scalp hair follicles are implanted with body hair follicles. Combination grafting is a similar procedure as mixed grafting^[3] in which multi-follicular units were implanted with follicular units (FUs). This not only increases the total number of donor hair follicles but also enhances results because of the higher visual density of beard hair. Although body hair other than the beard are thinner, but certainly better than micropigmentation.

Beard hair, which is thicker and curlier, having higher visual density, is used in the forelock and mid-scalp area. Beard, chest, and other body areas are extra-scalp sources of donor hair follicles, and their growth is androgen dependent, which is an advantage in androgenetic alopecia.

Aims and objective: The aims and objective of the study was to observe the advantages of the use of body hair follicles with scalp hair follicles to enhance the visual density of hair transplant and provide better coverage for higher grades of baldness.

Address for correspondence: Dr. Anil Kumar Garg MS, MCh Plastic surgeon, Rejuvenate Plastic, Cosmetic and hair transplant centre, Bhandari marg, Indore, Madhya Pradesh, India. E-mail: anilgarg61@yahoo.com

This is an open access journal, and articles are distributed under the terms of the Creative Commons Attribution-NonCommercial-ShareAlike 4.0 License, which allows others to remix, tweak, and build upon the work non-commercially, as long as appropriate credit is given and the new creations are licensed under the identical terms.

For reprints contact: reprints@medknow.com

How to cite this article: Garg AK, Garg S. “Combination grafting” of scalp and body hair to enhance the visual density of hair transplant and coverage of higher grade of baldness. J Cutan Aesthet Surg 2020;13:163-9.

Access this article online

Quick Response Code:



Website:
www.jcasonline.com

DOI:
10.4103/JCAS.JCAS_89_18

MATERIALS AND METHODS

Scalp hair follicles were mixed with body hair and transplanted to cover the bald area. In all 16 cases, the combination grafting was conducted. All cases of male pattern alopecia of Norwood grade IV and above were examined and evaluated for donor availability of scalp and body hair. Total period of study was 18 months. A detailed discussion was conducted with the patient, and consent was obtained for using the combination approach of implantation. In all cases, scalp donor hair TricoScan study at five places was carried out. Scalp hair can be harvested either by follicular unit transplantation (FUT) or follicular unit extraction (FUE). Selection of FUT or FUE for scalp harvesting was left on patients' choice. Body donor hair follicles were harvested using FUE technique.

1. In Norwood grade IV baldness, we planned 2500/3000 grafts. We harvested 20%–30% of the total grafts/follicles from the beard, (approximately 600–900) after obtaining consent.

Two centimeters in front of the defined hairline zone, including the transition zone, only scalp hair follicles were used and implanted as per the standard guidelines described by Shapiro.^[4] Then in the three rows just behind the defined zone, we mixed scalp to beard hair in the ratio of 2:1 for more natural look, whereas in forelock area, we mixed scalp to beard 1:1 for more fullness. Similarly, in the mid-scalp area, we implanted the remaining beard hair mixed with scalp hair follicles roughly in the ratio of 3:1. We did not cover the crown in the first stage of younger patients and advised them to take medicines. Figure 1A presents after scalp hair

follicle implantation and Figure 1B presents the image after beard hair follicle implantation showing the planning of combination grafting. Figure 1C presents actual planning on patient's scalp.

- In Norwood grade V baldness, 4000/5000 grafts were planned. In single harvesting, either by FUT or FUE, we harvested 2000–3000 grafts from scalp donor area and the remaining from the beard and/or chest. Planning of implantation of mixing of the scalp to body ratio remained the same as explained in grade IV baldness, only that the remaining body hairs were implanted in the mid-scalp area. The aforementioned procedure was carried out on 2 consecutive days. All scalp hair follicles were implanted on day 1, leaving space for beard/other body hair follicles for the next day. On the next day, body hair follicles were harvested and implanted in the gaps left in between the scalp hair follicles [Figure 2].
- In grade VI and VII baldness, detailed master planning of recipient and donor area was carried out after discussion with the patient. The total amounts of hair follicles (HF) to be implanted were calculated, and the number of follicles harvested from each area in multiple stages was planned, which is explained as follows:
 - As a routine, we implanted 6000–7000 grafts for grade VI baldness depending on donor availability and the patient's desire for how many grafts he wants. Of this total, we harvested 4500–5000 from the scalp in multiple stages and the remaining from the beard and other body parts.
 - In the first sitting, 2 consecutive days were planned. A total of 5000 grafts were harvested to cover up

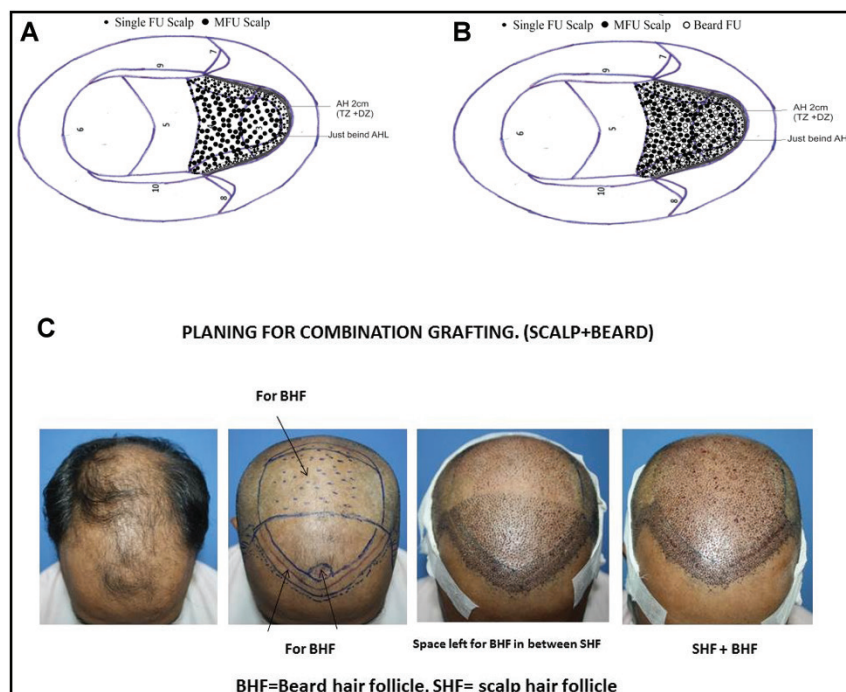


Figure 1: (A) After scalp HF implantation in Norwood grade IV. (B) After beard HF implantation. (C) Planning of combination grafting. AHL = anterior hair line, TZ = transition zone, DZ = defined zone, AH = anterior hair

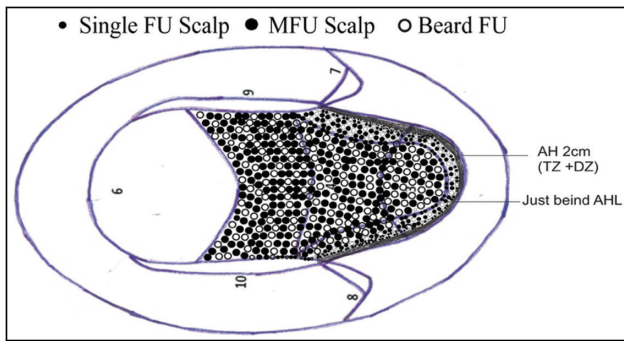


Figure 2: Planning of scalp and beard hair follicles in Norwood grade V. AHL = anterior hair line, TZ = transition Zone, DZ = defined zone, AH = anterior hair

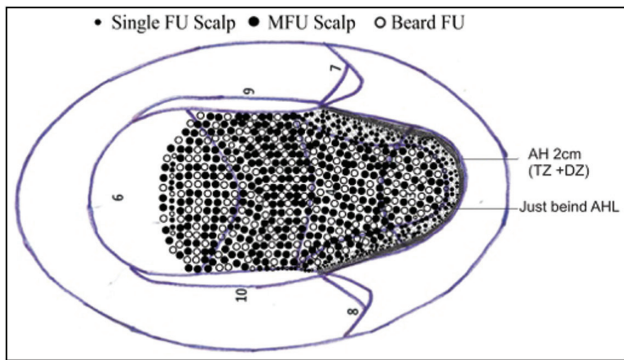


Figure 3: Grade VI planning. AHL = anterior hair line, TZ = transition Zone, DZ = defined zone, AH = anterior hair

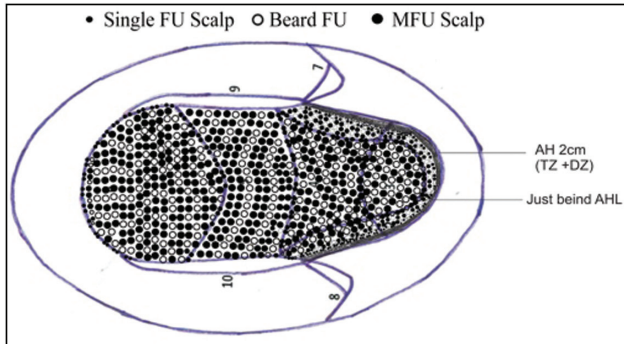


Figure 4: Grade VII planning. AHL = anterior hair line, TZ = transition zone, DZ = defined zone, AH = anterior hair

the area up to the vertex transition point. Of 5000 grafts, 2500–3000 grafts were harvested from the scalp and the remaining from the beard or other body parts. Planning of implantation in the front area remained the same as described in grade IV and V baldness, the remaining area of the scalp was implanted mixing with beard hair.

- If a patient wanted further stages then a minimum 4-month gap was given. It may be a 1- or 2-day harvesting session. On any given day, we did not harvest from more than two body areas, and all precautions were taken so that the dose of anesthetic agent remained within safe limits [Figure 3].

4. In grade VII baldness, we implanted 7000–8000 grafts in multiple sessions. Planning remained the same as in Norwood grade VI baldness [Figure 4].

RESULTS

Here pictures of few cases are shown. Figures 5 is a case of Norwood grade IV, Figure 6, is of diffuse pattern hair loss, Figure 7 is of Norwood grade III, Figure 8 and Figure 9 are case of Norwood grade VII. All these cases the use of scalp, and body hair follicles in combination has been done as per detail planning explained in method.

DISCUSSION

Total scalp hair-bearing area is approximately 520cm² (Bernstein *et al.*^[5] and Jimenez and Ruifernández^[6]), and of this, around 200cm² is safe donor area (Jimenez and Ruifernández,^[6] Cole and Devroye,^[7] and Unger^[8]), the remaining area is approximately 300cm², which is androgen dependent and vulnerable to baldness. To give the visual effect of reasonable density, we need to implant 30–40 grafts/cm² in this 300cm² area. For this, we need around 9000 grafts. As per standard calculation, the total number of grafts in the safe scalp donor area is 12,500, and of this, we can safely harvest 6,000 grafts. So there is a deficit of approximately 3000 grafts to cover a total bald area of grade VII. This deficit can only be covered by using extra-scalp hair follicles, that is, body hair follicles. By presuming that any patient presented with grade IV baldness or above has all the chances to go for grade VII, we might need approximately 9000 grafts in total to cover the baldness in the future. But certainly this calculation demands the search for extra-scalp donor area. Body hairs around 3000 and above can be harvested from beard, chest, and extremities as per the requirement and availability. We have not used donor hair from extremities.

The word "combination grafting^[3]" was used for a hair transplant procedure in which FUs along with multi-follicular multi unit grafts (MUGs) were implanted to increase density and to reduce implantation and overall surgical timing. The main advantage was better density, but if not carried out properly, there could be cosmetic compromise as proper planning of placement of MUGs with FUs was very important. This was used in the era of MUGs. But then the era of micrografting came in and cosmetic appearance superseded so MUGs almost disappeared. But still the need for higher density could not be overlooked. The recombinant grafting^[9] and high-density grafting^[10,11] have their own advantages and disadvantages. High-density grafting adversely affects graft survival, and recombinant grafting needs more number of donor hair follicles.

The advantages of body hair follicles^[1,2] is that this provides extra-scalp donor hair follicles. Beard hair is thicker, giving better illusion of density. Hair from other body areas decreases the scalp show.

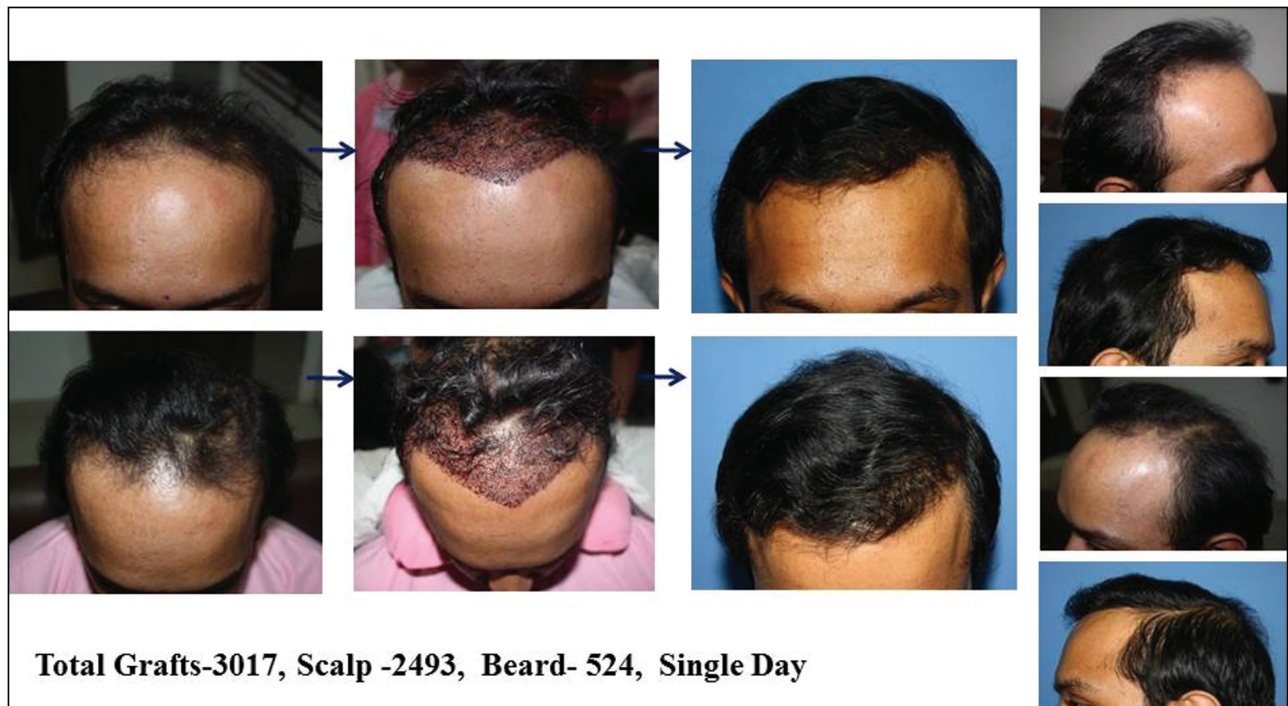

Figure 5: Case I, grade IV

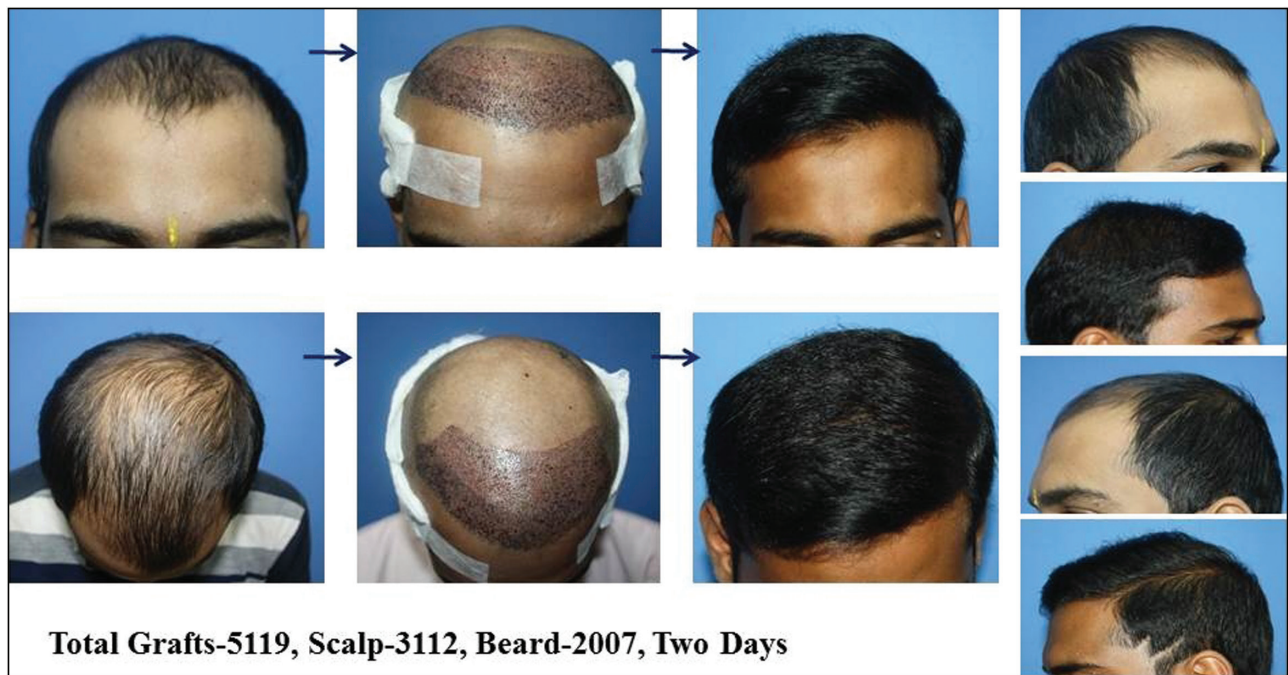

Figure 6: Case II, diffuse pattern hair loss

Author plans for body hair implantation even at the first hair transplant procedure so a proper scalp and body hair combination grafting is planned. In Norwood grade IV cases, as narrated, we implanted a total of 2500/3000 grafts and of this, we harvested 2000 follicles from the scalp and remaining from the beard and implanted them just behind the hairline, forelock, and mid-scalp. The reason of using beard hair even in grade IV cases is that it saves scalp

donor follicles for future use (for future anterior hairline corrections and temporal area reconstruction) and also the results are very encouraging in terms of visual density.

Similarly, the use of chest hair is good for the mid-scalp and crown along with the beard and scalp. The thickness of chest hair is not good as compared to the beard hair and scalp hair, but still because of curl of the hair, the visual density given is reasonable and certainly better than

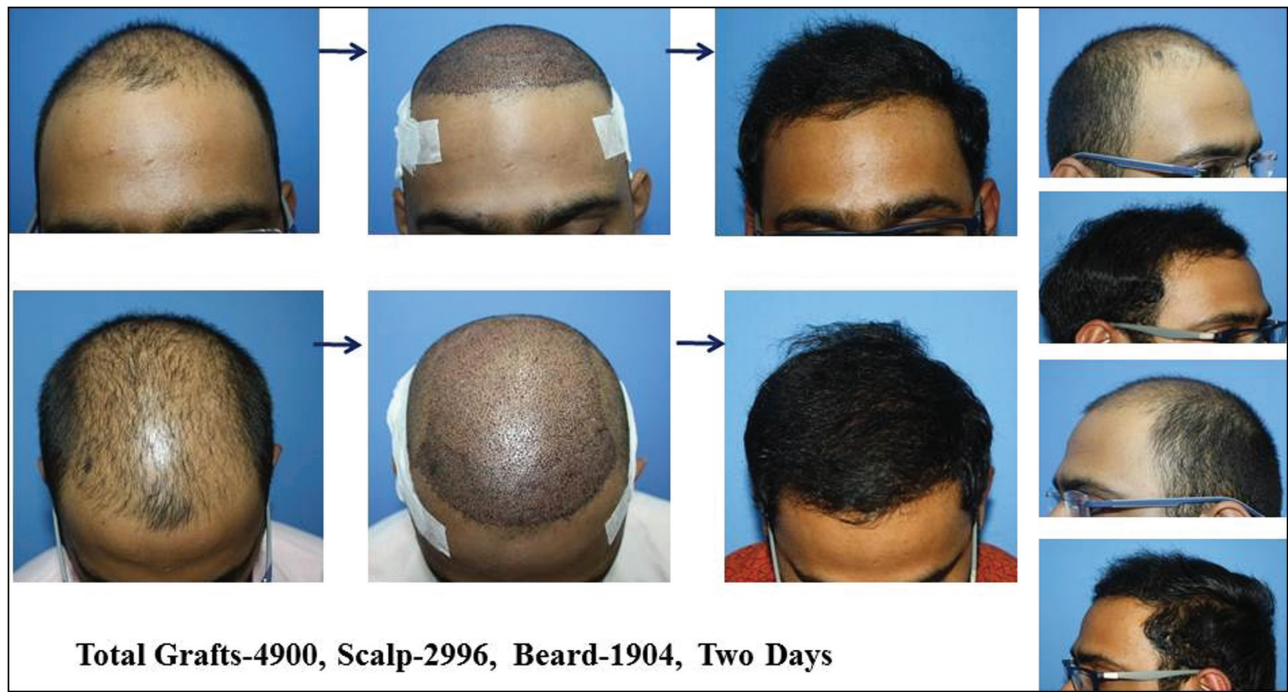

Figure 7: Case III, grade VI

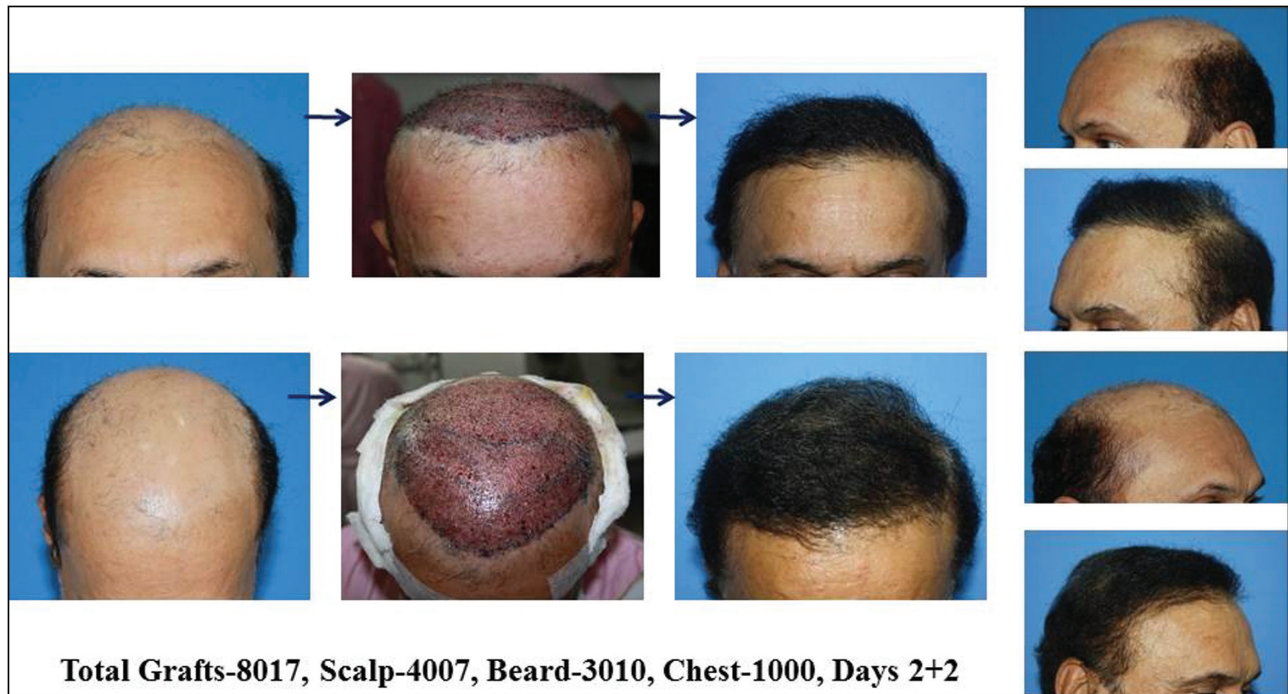

Figure 8: Case IV, grade VII

doing scalp micro pigmentation (SMP). Another good quality of hair is pubic hair, for which patients will be willing if harvesting is carried out by FUE.

As per the studies conducted by Hwang *et al.*,^[12] Hwang *et al.*,^[13] and Lee,^[14] when body hair is implanted on the scalp, the thickness remains unchanged, but the length and hair growth change. They become longer, and the growth rate also increases.

We have been harvesting body hair for more than 3 years and have been using Cole 0.75- and 0.8-mm sharp serrounded punch for beard, chest, and abdomen, but have no experience with extremities hair. In last two cases where chest and abdomen hair were very curly and long, we used 0.9-mm flared punch, and this reduced transection. We evaluated beard and chest donor hair for density and thickness. Patients' satisfaction with body hair is very

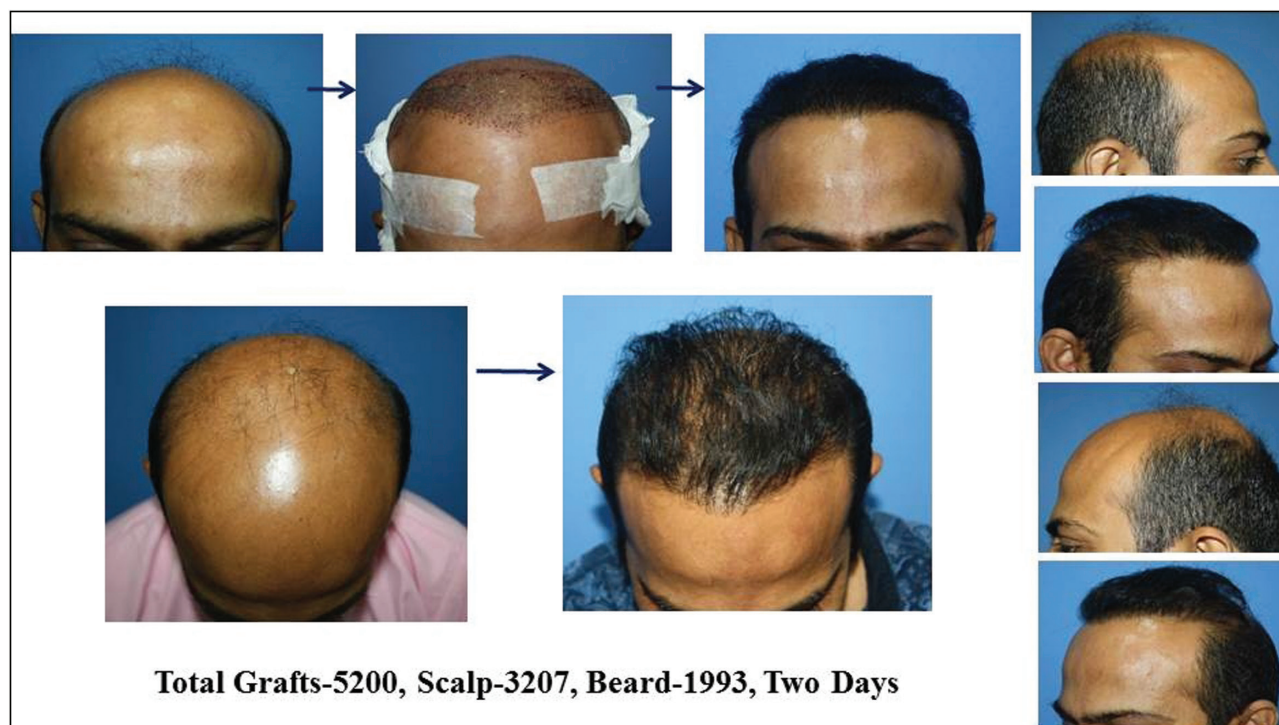

Figure 9: Case V. Body hair other than beard are thin, hence, they do not have a strong shaft to facilitate easy extraction. The body hair have greatly variable direction and pattern which makes extraction of body hair difficult. The position of extraction is also not comfortable for patient and surgeon.

high. In almost all cases, body hair after implantation did not go into anagen effluvium (no comparative study was conducted), but they were frizzy and dry initially and became better over the 2 years. In our experience, chest hair growth was slower (no comparative study was conducted, just an observation).

There are few limitations of body hair follicle harvesting and complications. Body hair follicles harvesting has a long learning curve because of reasons such as acute exit angle of hair, more superficially sitting follicles in collagenous dermis unlike scalp hair, which floats in fat, absent bony support, and bulky soft tissue. Hence, do not have a strong shaft to facilitate easy extraction, greatly variable direction, and pattern of body hair in beard and chest, difficult positions, anesthesia, and there are more telogen hair. Surgeon should be very careful about the overdose of an anesthesia. Few complications such as ingrown hairs or cysts, hypo-, or hyperpigmentation in donor area are observed, which can sometime be embarrassing for patients, specially in beard area. Accidental injury to facial nerve during beard hair follicle harvesting may give rise to facial nerve paralysis, which may be temporary or permanent.

CONCLUSION

Combination grafting is a good answer to cover higher grades of baldness as well as to enhance the result of hair transplant.

With experience, one can improve technical challenges of body hair harvesting such as anesthesia, harvesting speed, and transection, so that every hair transplant surgeon keeps body hair harvesting as a good adjuvant to hair transplantation.

Financial support and sponsorship

Nil.

Conflicts of interest

There are no conflicts of interest.

REFERENCES

1. Cole J. Donor area harvesting body to scalp. In: Unger WP, Shapiro R, editors. Hair transplantation. 5th ed. London, UK: Informa Healthcare; 2011. pp. 304-5.
2. Yu JM, Yu AY. Donor area harvesting beard to scalp. In: Unger WP, Shapiro R, editors. Hair transplantation. 5th ed. London, UK: Informa Healthcare; 2011. pp. 300-2.
3. Unger WP. Why mixed grafting: follicular units and multi-follicular unit grafts. In: Unger WP, Shapiro R, editors. Hair transplantation. 4th ed. New York: Marcel Decker; 2004. pp. 477.
4. Shapiro R. Principles of creating a natural hairline. In: Unger WP, editor. Hair transplantation. 5th ed. London, UK: Informa Healthcare; 2011. pp. 373-82.
5. Bernstein RM, Rassman WR, Seager D, Shapiro R, Cooley JE, Norwood OT. Standardizing the classification and description of follicular unit transplantation and mini-micro grafting techniques. The American Society for Dermatologic Surgery, Inc. Dermatol Surg 1998;24:957-63.
6. Jimenez F, Ruifernández JM. Distribution of human hair in follicular units: A mathematical model for estimating the donor size in follicular unit transplantation. Dermatol Surg 1999;25:294-8.

7. Cole J, Devroye J. A calculated look at the donor area. *Hair Transplant Forum Intl* 2001;11:150-4.
8. Unger W, Solish N, Giguere D, Bertucci V, Coleman W, Loukas M, *et al.* Delineating the "Safe" donor area for hair transplanting. *Am J Cosm Surg* 1994;11:239-43.
9. James AH. Recombinant follicular transplantation. In Unger WP, Shapiro R, editors. *Hair transplantation*. 5th ed. London, UK: Informa Healthcare; 2011. pp. 371.
10. Mayer M, Keene S, Perez-Meza D. Graft density production curve with dense packing. International Society of Hair Restoration Surgery Annual Meeting, Sydney, Australia; August 24–28, 2005.
11. Nakatsui T, Wong J, Groot D. Survival of densely packed follicular unit grafts using the lateral slit technique. *Dermatol Surg* 2008;34:1016-22.
12. Hwang S, Kim JC, Ryu HS, Cha YC, Lee SJ, Na GY, *et al.* Does the recipient site influence the hair growth characteristics in hair transplantation? *Dermatol Surg* 2002;28:795-8.
13. Hwang ST, Kim HY, Lee SJ, Lee WJ, Kim DW, Kim JC. Recipient-site influence in hair transplantation: a confirmative study. *Dermatol Surg* 2009;35:1011-4.
14. Lee SH, Kim DW, Jun JB, Lee SJ, Kim JC, Kim NH. The changes in hair growth pattern after autologous hair transplantation. *Dermatol Surg* 1999;25:605-9.