

A Novel Use of Micropipette Device Is a Better Option for Precise Chemical Cautery

Dear Editor

Chemical cautery is used in dermatology to destroy small-sized skin lesions on the face and body such as acne scars, freckles, lentigo, milia, molluscum contagiosum, xanthelasma, warts, and so on. Chemicals could leach into areas not intended for cauterization during a procedure. For precise and safe cautery, a variety of devices have been used.^[1,2] However, procuring it takes some time, and aseptic precautions are required. Furthermore, there is the possibility of chemical loss and injury during the procurement process. To simplify the chemical cautery device procurement and its safety, we have used micropipette.

A variety of micropipette devices are used in medical and chemistry labs. A disposable micropipette tip costs 35–40 paisa per piece, and a micropipette device costs between 700 and 1000 rupees. Depending on the amount of chemical needed, the pipette volume can be adjusted from 1 to 100 μL or more. To cauterise skin lesions, we typically use a fixed amount of the chemical

(1–3 μL) [Figure 1A and B]. It is held like a pen after the chemical has been withdrawn from its tip. The lesions are then only lightly touched with the pipette tips, with no pressure applied [Figure 1C–E]. For safety, micropipette tip can be stuffed with cotton wick. Larger lesions are rolled over with the tip. A customized cotton bud with plastic stick can be fixed over micropipette tips to do fast cautery on a larger lesions [Figure 2A and B]. Chemicals flow instead of capillary action when they come into contact with the skin. The lesions are precisely cauterised. No chemical spills or injuries have occurred. As a precautionary measure, the disposable micropipette tips are discarded. As a result, the graded micropipette device with disposable tips is an excellent choice. Thus, for precise chemical cautery, the graded micropipette device with disposable tips is a better and simpler alternative option.

Declaration of patient consent

The authors certify that they have obtained all appropriate patient consent forms. In the form the patient(s) has/have given his/her/their consent for his/her/their images and other clinical information to be reported in the journal. The patients understand that their names and initials will not be published and due efforts will be made to conceal their identity, but anonymity cannot be guaranteed.

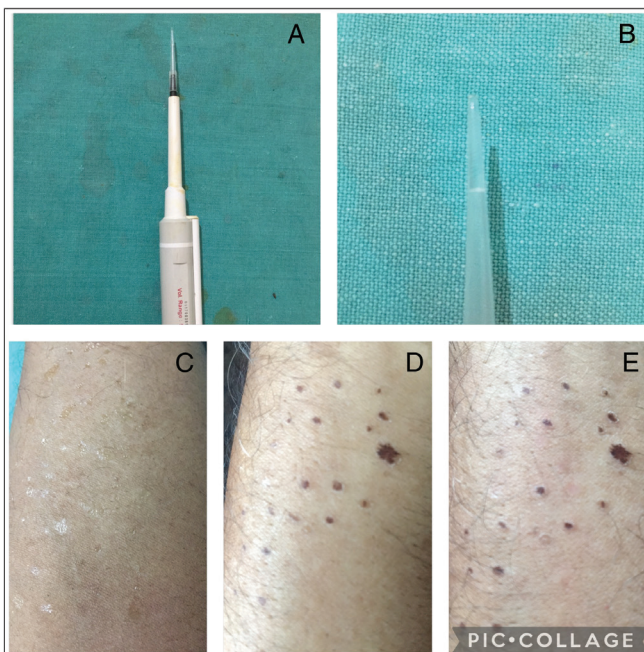


Figure 1: (A and B) Micropipette device having 3 μL of chemical in its tips. (C–E) The skin is precisely cauterized by touching with micropipette tips filled with trichloroacetic acid

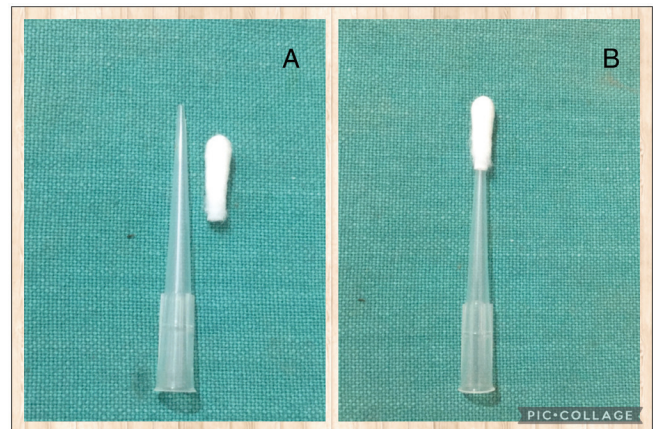


Figure 2: (A and B) A customized bud of plastic hollow swab stick is made to fix over micropipette tip for cautery of large lesion

Financial support and sponsorship

Not applicable.

Conflicts of interest

There are no conflicts of interest.

Muhammed Mukhtar, Nadia Mukhtar
Mukhtar Skin Centre, Katihar, Bihar, India

Address for correspondence: Dr. Muhammed Mukhtar,
Mukhtar Skin Centre, Katihar Medical College Road, Katihar 854105,
Bihar, India.
E-mail: drmmukhtar20@gmail.com

REFERENCES

1. Jangra RS, Gupta S, Gupta S, Dr A. Chemical cautery pen. J Am Acad Dermatol 2020;82:e193-4.
2. Mukhtar M. Disposable syringe for chemical cautery. J Am Acad Dermatol 2022;86:e93-5.

This is an open access journal, and articles are distributed under the terms of the Creative Commons Attribution-NonCommercial-ShareAlike 4.0 License, which allows others to remix, tweak, and build upon the work non-commercially, as long as appropriate credit is given and the new creations are licensed under the identical terms.

For reprints contact: reprints@medknow.com

Access this article online

Quick Response Code:



Website:

www.jcasonline.com

DOI:

10.4103/JCAS.JCAS_107_22

How to cite this article: Mukhtar M, Mukhtar N. A novel use of micropipette device is a better option for precise chemical cautery. J Cutan Aesthet Surg 2023;16:351-2.