

# Evidence-based Surgical Management of Post-acne Scarring in Skin of Color

Atula Gupta, Maninder Kaur<sup>1</sup>, Suman Patra<sup>1</sup>, Niti Khunger<sup>2</sup>, Somesh Gupta<sup>3</sup>

Skin Aid Clinic, Gurugram, Haryana, <sup>1</sup>Department of Dermatology, All India Institute of Medical Sciences, Bhopal, Madhya Pradesh, <sup>2</sup>Department of Dermatology and Venereology, Vardhman Mahavir Medical College & Safdarjung Hospital, <sup>3</sup>Department of Dermatology and Venereology, All India Institute of Medical Sciences, New Delhi, India

## Abstract

Acne scars are the reason for significant morbidity among dermatology outpatients. With more modalities being introduced every year, it is important to choose the best one suited for a particular type of scar for each patient to obtain an optimum result. Guidelines on acne scar management in the skin of color are not available where the therapeutic effect and side effect profile of the modalities can vary significantly. This narrative review looked at critical evaluation of the available modalities to find the level of evidence and therapeutic ladder of management of different types of acne scars. Treatment options for different types of scars have been described. Evidence level for each type of modality for the individual type of scar was calculated using the Strength of Recommendation Taxonomy (SORT) developed by editors of the US family medicine and primary care journals. In addition, various newer and emerging treatment options, such as dermal cell suspension, jet volumetric remodeling, and radiofrequency subcision, have been discussed. The highest level of evidence is available for microneedling, fractional radiofrequency, fractional CO<sub>2</sub>, and erbium:yttrium aluminum garnet laser for mild to moderate grade scars. Trichloroacetic acid chemical reconstruction of skin scars showed efficacy in ice pick scars. Grade 4 scars improve poorly with resurfacing procedures, where punch excision and punch elevation can be tried. Platelet-rich plasma therapy was effective in combination with lasers and microneedling. Overall there is lack of high-quality data in the management of post acne scars. Combination treatment has shown better efficacy compared to single modalities.

**Keywords:** Acne scars, evidence, surgical

## INTRODUCTION

Acne scars are a direct consequence of an altered wound healing response to cutaneous inflammation. Lesions such as comedones, papules, pustules, nodules, and cysts may cause scarring during resolution. As the severity of scarring is known to increase with prolonged inflammation it is imperative to initiate an early diagnosis and treatment of active acne.

## MATERIALS AND METHODS

For the purpose of this narrative review, articles were searched in PubMed using key words of “acne scar,” “surgical modalities for acne scars” along with the names of different modalities used in acne scars such as

“subcision,” “TCA CROSS,” “chemical peel for acne scars,” “microneedle radiofrequency in acne scars,” “laser and acne scars,” “dermal fillers and acne scars,” “microneedling and acne scars,” “scar revision surgery and acne scars,” “fat grafting for acne scars,” “punch techniques for acne scars,” “grading of acne scars,” “platelet rich plasma therapy and acne scars,” “microdermabrasion and acne scars,” and “botulinum toxin injection and acne scars.”

Those papers, which were on acne scars in skin of color, were predominantly selected. We tried to cover all the articles related to the modalities in the last 15 years. If required, we also looked at older articles.

**Address for correspondence:** Dr. (Prof) Somesh Gupta,  
Room No 4070, 4th Floor, Teaching Block,  
Department of Dermatology and Venereology, All India Institute of Medical  
Sciences, New Delhi 110029, India.  
E-mail: someshgupta@hotmail.com

All videos available online  
[www.jcasonline.com](http://www.jcasonline.com)

Access this article online

Quick Response Code:



Website:  
[www.jcasonline.com](http://www.jcasonline.com)

DOI:  
10.4103/JCAS.JCAS\_154\_19

This is an open access journal, and articles are distributed under the terms of the Creative Commons Attribution-NonCommercial-ShareAlike 4.0 License, which allows others to remix, tweak, and build upon the work non-commercially, as long as appropriate credit is given and the new creations are licensed under the identical terms.

**For reprints contact:** [reprints@medknow.com](mailto:reprints@medknow.com)

**How to cite this article:** Gupta A, Kaur M, Patra S, Khunger N, Gupta S. Evidence-based surgical management of post-acne scarring in skin of color. *J Cutan Aesthet Surg* 2020;13:124-41.

## CLASSIFICATION OF ACNE SCARS

Scars can heal with a depletion (atrophic acne scars) or net gain (hypertrophic acne scars) in collagen. The classification of scars was initially proposed keeping the therapeutic options in mind.<sup>[1]</sup> Broadly, acne scars can be classified into atrophic and hypertrophic acne scars. Atrophic scars constitute 80%–90% of all acne scars.<sup>[2]</sup> Atrophic acne scars have been further divided into ice pick (60%–70% of all), boxcar (20%–30% of all), and rolling scars (15%–25% of all).<sup>[3]</sup> Often all three types of atrophic acne scars may be present simultaneously in the same patient.

Hypertrophic and keloidal acne scars form as a result of decreased collagenase activity and exuberant collagen deposition.

## GRADING OF ACNE SCARS

Acne scars are graded based on four comprehensive parameters.<sup>[4]</sup> These include scar subtype/lesion counting,

subjective self-assessment, global acne scar severity scoring, and quantitative measurement of acne scars based on imaging. For the details, the reader can refer the review by Clark *et al.*<sup>[4]</sup>

## CLASSIFICATION OF AVAILABLE SURGICAL MODALITIES FOR ACNE SCARS

Different surgical procedures have been used to treat acne scars, and newer modalities are being continuously introduced in an attempt to achieve optimal results. Figure 1 shows the classification of different modalities used in acne scar management.

## EVIDENCE GRADING

For this review, the available evidence was evaluated using the Strength of Recommendation Taxonomy (SORT) developed by editors of the US family medicine and primary care journals.<sup>[5]</sup>

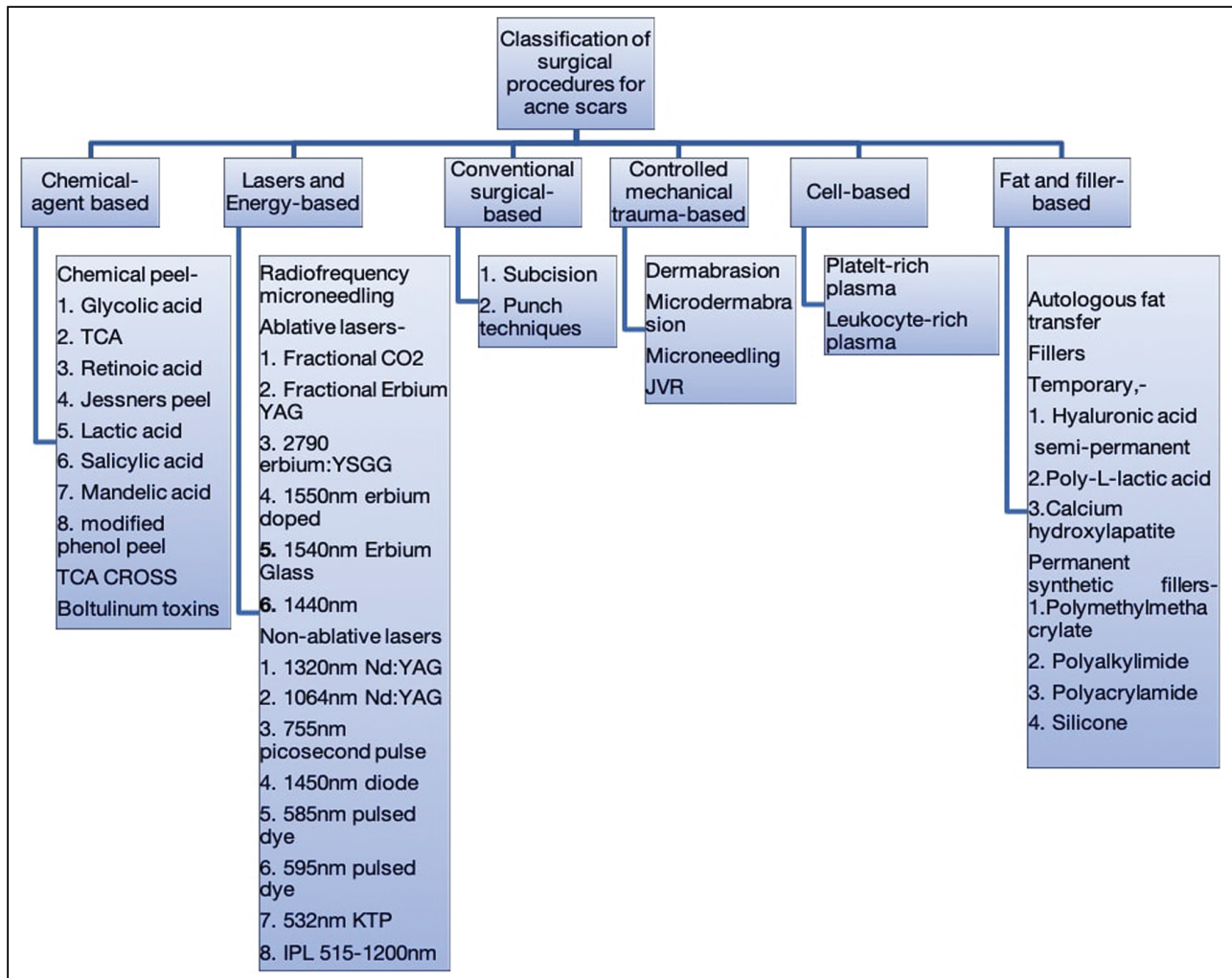


Figure 1: Classification of surgical modalities for acne scars

Evidence was graded using a three-point scale based on the quality of methodology (e.g., randomized control trial, case-control, prospective/retrospective cohort, and case series) and the overall focus of the study (i.e., diagnosis, treatment/prevention/screening, or prognosis) as follows:

- I: Good-quality patient-oriented evidence (i.e., evidence measuring outcome in terms of morbidity, mortality, symptom improvement, cost reduction, and quality of life)
- II: Limited-quality patient-oriented evidence
- III: Other evidence, including consensus guidelines, opinion, case studies, or disease-oriented evidence (i.e., evidence measuring intermediate, physiologic, or surrogate endpoints that may or may not reflect improvements in patient outcomes)

Clinical recommendations were developed on the best available evidence tabled in the guideline. The strength of recommendation (SoR) was ranked as follows:

- A: Recommendation based on consistent and good-quality patient-oriented evidence
- B: Recommendation based on inconsistent or limited quality patient-oriented evidence
- C: Recommendation based on consensus, opinion, case studies, or disease-oriented evidence

In those situations where documented evidence-based data were not available or had inconsistent or limited conclusions, expert opinion and the medical consensus was used to generate clinical recommendations.

In this review, level of evidence (LoE) and strength of recommendation (SoR) are mentioned in most of the modalities based on the best available evidence.

## CHEMICAL PEELS IN ACNE SCARS

For atrophic acne scars: LoE III, SoR C

For post-acne hyperpigmentation: LoE II, SoR B

The selection of the chemical peeling agent depends on the patient's skin type and severity of scarring. The most effective treatment outcomes are seen with macular pigmented acne scars. Superficial acne scars (post-acne hyperpigmentation) respond well to 30% salicylic acid peel used in multiple sessions at 4–6 weeks of intervals.<sup>[6]</sup> Full strength, 92% lactic acid (LA) has shown an improvement in texture and color of pigmented scars in skin type IV and V.<sup>[7]</sup> Jessner's solution combined with 35% or 20% trichloroacetic acid (TCA) has shown marked reduction of both ice pick and rolling scars.<sup>[8,9]</sup>

The primary concern with TCA is the risk of post-inflammatory hyperpigmentation (PIH), particularly in the skin of color. Moderate acne scars have been found to respond to 40%–70% pyruvic acid (PA) peel.<sup>[10]</sup> Glycolic acid (GA) is widely used in treating both acne and acne scars. It improves acne scars by increasing dermal and

epidermal hyaluronic acid (HA), resulting in remodeling of extracellular matrix.<sup>[11]</sup>

Several combinations of GA peel along with other modalities have been tried. These include topical retinoic acid, microneedling, and iontophoresis with ascorbyl 2-phosphate 6-palmitate and DL- $\alpha$ -tocopherol phosphate (for improvement in PIH).<sup>[12,13]</sup>

Mandelic acid 10% in combination with salicylic acid 20% (salicylic-mandelic peel, i.e., SMP) has been compared with 35% GA peel.<sup>[14]</sup> Modest improvement was observed in ice pick scars, boxcars, and rolling scars in both the groups, but the former was safer and more efficacious in PIH. A modified form of phenol peel (Exoderm) has been tried with good improvement, but considerable side effects such as dyspigmentation, prolonged erythema, and milia formation were seen.<sup>[15]</sup>

Considering their flexibility and low cost of treatment, chemical peels play an important role in the management of all grades of acne scars. Superficial peels such as Jessner's solution, full strength 92% LA, 20%–70% GA, SMP, and 10%–25% TCA are safe, and multiple sessions can attenuate superficial acne scars in patients with skin of color. Extra caution needs to be exercised with moderate depth (25%–50% TCA, TCA 35% + Jessner's solution, and 40%–60% pyruvic acid) and deep peels because of the risk of PIH and post-procedure scarring.

## CHEMICAL RECONSTRUCTION OF SKIN SCARS

For ice pick scars: LoE II, SoR B

TCA-chemical reconstruction of skin scars (CROSS) involves the serial local application of high concentration TCA with a wooden applicator to the scar.<sup>[16]</sup> No anesthesia is needed. TCA is applied for a few seconds until the scar displays a white frosting. A black crust forms in 3–4 days and heals in 7–10 days. The clinical effects of TCA are due to dermal collagen remodeling and an increase in the content of collagen, glycosaminoglycan, and elastin.

Varying concentrations of TCA ranging from 35% to 100% have been used. Good to excellent improvement has been reported in approximately two-third to three-fourth patients, depending on types and grades of scars. Approximately a third patients with darker skin type may develop PIH, which may persist in some patients.<sup>[17,18]</sup> Better results are observed with 100% compared to 65% TCA CROSS.<sup>[19]</sup> Phenol (88%) has been used in place of TCA (90%) with comparable results in V and VI skin type.<sup>[20]</sup> TCA CROSS has been combined with subcision and fractional lasers with good improvement.<sup>[21,22]</sup> There are studies comparing microneedling with TCA CROSS. Boxcar and rolling scars responded well to microneedling and ice pick scars to the CROSS technique.<sup>[23]</sup> Ramadan *et al.*<sup>[24]</sup> found TCA CROSS to be inferior to subcision in decreasing the size of scars with TCA having more

pigmentary alteration. It has been found to have comparable efficacy with 1550 nm Er:glass fractional laser in patients of type IV and V skin. Rolling scars had superior outcomes with laser, whereas ice pick scars had similar improvement with both techniques.<sup>[25]</sup>

## DERMABRASION

Superficial and small scars: LoE II, SoR B

Dermabrasion is a sequential removal of the skin layers to the desired level, from the epidermis to dermis. The procedure uses a wire brush, diamond fraise, or sterilized common sand paper and is performed under topical or infiltration anesthesia. After surgical cleansing, the scars are marked with the patient in sitting position, the skin is stretched and dermabrasion is performed up to the base of the scars, but not deeper than the junction of the upper and mid-reticular dermis. Crusting can last 7–10 days, depending on the depth of dermabrasion, and reepithelialization occurs from cells within the adnexal structures. Infections, persistent dyschromia, hypo- or hyperpigmentation, erythema, and scarring are possible complications. Dermabrasion is particularly successful in treating superficial atrophic acne scars, such as rolling or boxcar scars.<sup>[26]</sup> Strict sun protection is essential for the prevention of PIH, particularly in darker skin types.

## MICRODERMABRASION

Mild to moderate scars: LoE II, SoR B

Microdermabrasion is a superficial variation of dermabrasion, which only removes the outer layer of the epidermis. It is a minimally invasive technique of mechanical abrasion of the skin, which accelerates the natural process of exfoliation.<sup>[27]</sup> Earlier, the handpiece made use of aluminum oxide or sodium bicarbonate crystals for abrasion, whereas now diamond tips are commonly used to increase accuracy and decrease irritation. Post-procedure hyper- or hypopigmentation, and hypertrophic scarring are the potential complications, particularly in Fitzpatrick skin type IV and VI.<sup>[28]</sup>

In moderate to severe acne scars, satisfactory results are seen in only approximately 5%–20% of patients. Priming with topical adapalene 0.1% 2 weeks before the procedure can improve the outcomes. Bhalla<sup>[29]</sup> reported comparable results with microneedling and microdermabrasion. Most studies reported good improvement in around 50% of the grade 2 scars and 20% of the grade 3 scars, whereas no response was seen in grade 4 scars.<sup>[30]</sup>

## MICRONEEDLING

Mild to moderate scars: LoE I, SoR A

Microneedling is a minimally invasive therapeutic modality, involving superficial and controlled puncturing

of the skin by miniature fine needles fitted on a drum-shaped cylinder, which is rolled over scarred skin.<sup>[31,32]</sup> The procedure is performed under topical anesthesia. Each pass produces micropunctures in the stratum corneum, which results in a controlled skin injury. The treatment endpoint is identified as uniform pinpoint bleeding. A wound-healing cascade causes a release of growth factors, leading to neocollagenesis.<sup>[33]</sup> The needles also breakdown scar strands and allow the area to revascularize.

Dermapen is an electronic microneedling device, which has a detachable head of 33 G size consisting of 12 microneedles that can penetrate to variable depths in the skin, depending on preset values. A comparative study conducted between microneedling by Dermapen versus GA peel versus the combination of both suggests combination to be more effective.<sup>[34]</sup>

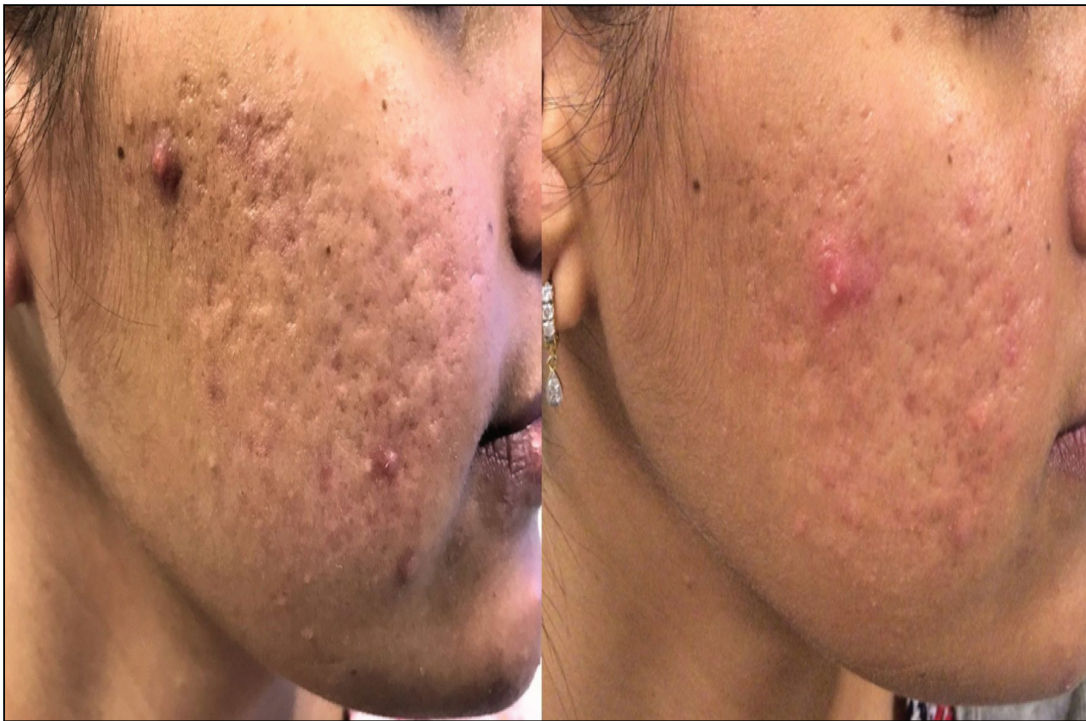Microneedling is moderately effective for the rolling type of acne scars.<sup>[35]</sup> All types of atrophic scars tend to improve (in the range of 50%–60%) with microneedling to a variable grade.<sup>[36]</sup> Afra *et al.*<sup>[37]</sup> found the efficacy of microneedling comparable to that of topical tazarotene 0.1% after four treatment sessions. Microneedling has been found to be inferior to Er:ytrium aluminum garnet (YAG) laser in a split face trial by Osman *et al.*<sup>[38]</sup>

## MICRONEEDLE RADIOFREQUENCY FRACTIONAL

Mild to moderate scars: LoE I, SoR A

Microneedle radiofrequency fractional (MNRF) has been found to be effective in reducing both atrophic acne scars and open pores. As the impedance of the dermis is lower (due to the higher water content) than the epidermis, the flow of energy is greater in the dermal tissue, leading to the formation of a larger coagulative thermal zone.<sup>[39]</sup> Radiofrequency energy disrupts the dermal fibrotic strands and triggers collagen remodeling.<sup>[40]</sup> It creates a pyramidal injury zone unlike the conical thermal damage induced by ablative lasers and greater depth of penetration of the microneedles (up to 3.5 mm) as compared to fractional lasers (0.7 mm) [Video 1] [Figure 2]. Insulated microneedle coagulates only the deeper part and protects the epidermis, but it is associated with bleeding. Uninsulated microneedle causes coagulation along the full length of the needle, thus prevents microbleeding.<sup>[41]</sup> MNRF usually requires 4–6 sessions for optimal results. The majority of patients show only mild to moderate (25%–50%) improvement.<sup>[42,43]</sup>

Comparative studies with lasers have shown similar efficacy. Chae *et al.*<sup>[44]</sup> compared MNRF with Er:glass laser in Korean patients. After 20 weeks of follow-up, scar severity scores improved by a mean of 18.6% and 25% in MNRF and Er:glass groups, respectively ( $P < 0.01$ ).<sup>[44]</sup> A combination of fractional CO<sub>2</sub> laser with MNRF was found to be better than laser alone.<sup>[45]</sup> Similarly, studies have combined MNRF with a diode laser, fractional



**Figure 2:** Baseline and post-treatment picture of combination of MNRF and SA peel 30% after five sessions

thulium lasers, and bipolar radiofrequency devices with combinations being more effective than monotherapy.

MNRF has minimal adverse effects such as pain, erythema, edema, and spot bleeding. Pain is significantly lower as compared to ablative fractional lasers. It is safe and moderately effective in all types of acne scars in type III and V skin (a color-blind procedure).

## LASERS AND LIGHT SOURCES

Laser treatment of atrophic acne scars can be divided into two main categories: ablative and non-ablative. Thermal injury delivered by lasers leads to stimulation of dermal fibroblasts, which initiate new collagen and elastin production. The cosmetic outcome depends on the ability to increase efficacy and reduce downtime and adverse effects associated with these devices.

An overview of lasers available for acne scarring is given in Table 1.

In darker skin types (IV and V), lower energy should be used to minimize PIH. Concurrent isotretinoin treatment is not considered as a contraindication for laser therapy.<sup>[46]</sup> Lasers should be avoided in areas of active inflammation and infection. Choosing appropriate settings for laser taking into consideration the depth of the scar, skin type, and tendency to PIH is of utmost importance. As the parameters vary considerably between different machines, it is advisable to start at lower fluence and increase gradually guided by the outcomes and adverse effects.

### Ablative laser resurfacing

*Fractional lasers:* Fractional lasers are based on the fractional photothermolysis. They create numerous microscopic thermal injury zones of controlled density, depth, and width, which are surrounded by normal skin that serves as a reservoir of tissue healing. This helps in decreasing the downtime of healing. Currently, a variety of ablative as well as non-ablative fractional lasers is in use due to their good cosmetic outcomes in acne scars and low-risk profile.

### Ablative fractional lasers

Fractional 10,600 nm CO<sub>2</sub> laser: LoE I, SoR A

Fractional 2,940 nm Er:YAG laser: LoE I, SoR A

The overall efficacy of ablative fractional lasers is higher than non-ablative fractional lasers with fewer treatment sessions needed in the former.<sup>[47]</sup> Recent studies have reported scar improvement ranging from 26% to 50% versus 26% to 83% in non-ablative versus ablative fractional lasers, respectively.<sup>[48-51]</sup>

The fractional CO<sub>2</sub> laser is most widely used in the management of acne scars worldwide. Most of the studies have shown a good response to fractional CO<sub>2</sub> laser in rolling scars;<sup>[52-54]</sup> however, a retrospective study of 107 Asian patients concluded that rolling scars had a poor clinical response as opposed to other scars.<sup>[55]</sup> Rolling scars may benefit more from subcision before fractional laser session.<sup>[56]</sup>

Most of the patients report post-procedure erythema and edema, which are transient. However, PIH is seen

**Table 1: Different types of lasers used in post-acne scarring<sup>[66]</sup>**

Ablative non-fractional	Ablative fractional	Non-ablative non-fractional	Non-ablative fractional
10,600 nm CO <sub>2</sub> (pulsed)	1,550 nm erbium doped	1,320 nm Nd:YAG 1,064 nm Nd:YAG	1550 nm erbium doped
2,940 nm erbium:YAG (pulsed)	1,540 nm erbium:glass	755 nm picosecond pulse 1,450 nm diode	1540 nm erbium:glass
2,790 erbium:YSGG	1,440 nm diode-based laser	585 nm pulsed dye 595 nm pulsed dye 532 nm KTP IPL 515–1,200 nm	1,440 nm diode-based laser

YAG = yttrium aluminum garnet, KTP = potassium titanyl phosphate, IPL = intense pulse light, YSSG = yttrium, scandium, gallium and garnet

in 6.4%–92.3% of patients with type IV and V skin.<sup>[57,58]</sup> A higher treatment density and fluence are associated with a greater degree of PIH.<sup>[58]</sup> It is short-lived in most of the patients with an average duration of 5 weeks. PIH can be treated with 4% hydroquinone cream.

Fractional 2940 nm Er:YAG is another fractional ablative laser used for acne scars. It produces one-third of the coagulation depth as compared to fractional CO<sub>2</sub> laser while giving similar clinical results. Pain and the incidence of PIH are less in comparison to fractional CO<sub>2</sub> laser.<sup>[59]</sup> In type IV and V Indian skin, it showed more than 25% improvement.<sup>[60]</sup> PIH was seen in only one patient. Better results were seen in rolling and superficial boxcar scars than ice pick or deep boxcars.<sup>[61]</sup>

### Non-ablative fractional lasers

Fractional 1540 Er:glass: LoE II, SoR B

Fractional 1550 nm Er-doped laser (EDL): LoE II, SoR B

Non-ablative fractional lasers resurfacing (NAFR) use the mid-infrared wavelengths (1550, 1440, and 1927 nm) emitted by laser sources such as Er and thulium to create microscopic thermal zones (MTZ) at 200–500 μm depths. The infrared and visible wavelength ranges emitted by them stimulate the formation of Type 1 and Type 3 collagen fibers. The main benefit is the low incidence of side effects and faster recovery time. However, multiple sessions are needed and only a modest response is seen in severe acne scarring.<sup>[62]</sup>

Various studies have been conducted on fractional 1540 nm Er:glass laser. In Asian patients with skin types II–IV, there was a 50% improvement in atrophic scars in two-third of the patients, with no persistent adverse events.<sup>[63]</sup> Boxcar scars show better improvement than rolling and ice pick scars.<sup>[64]</sup>

Fractional 1550 nm EDL improves the appearance of acne scars by as much as 50% after a series of four to five treatments. It also significantly improves acne PIH. The treatment settings for acne scars depend on skin type. For skin IV and V, the settings of 30–70 mJ of energy are used. This laser is safer than ablative lasers in dark skin types; still, caution is recommended.<sup>[65,66]</sup>

### Non-ablative, non-fractional lasers

1064 nm Q-switched Nd:YAG laser: LoE II, SoR B

1065 nm Pulsed dye laser (PDL): For post-acne erythema and hypertrophic scars: LoE I, SoR A

1320 nm laser: LoE II, SoR B

1064 nm Nd:YAG laser is also an effective noninvasive modality for mild to moderate facial acne scarring. Long-term collagen remodeling is seen. In a study conducted on 11 patients, it showed approximately 40% improvement in mild to moderate acne scars at the end of five sessions.<sup>[67]</sup>

PDL has been found effective in treating scar associated erythema. Usually, four or more treatments at approximately 1-month intervals are needed for good outcomes.

In a split-face study, the 585 nm flashlamp-pumped PDL showed 68% reduction in scarring and erythema at 6 months after treatment.<sup>[68]</sup> In another study of 10 patients with Fitzpatrick skin type I–IV, the average depth of scars reduced by 47.8%.<sup>[69]</sup>

Historically, the 1320 nm laser has been used to treat rhytides and for facial rejuvenation. Recently, it has been found to be effective in acne scars. In a study involving 29 patients of skin type I–IV, mean improvement after 2–17 sessions was 2.8 on a 0- to 4-point scale by physician assessment and 5.4 on a 0- to 10-point scale by patient assessment.<sup>[70]</sup>

### Intense pulsed light

Intense pulsed light (IPL) has been used mainly to treat acne scar-associated erythema. In a retrospective study of 33 patients, IPL using 560-nm filter was found to decrease erythema significantly after 3–6 sessions.<sup>[71]</sup>

### Emerging laser technologies

Picosecond 755 nm alexandrite laser: LoE III, SoR C

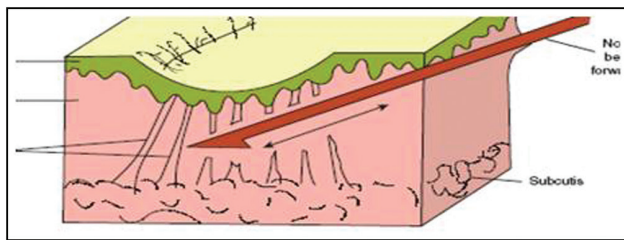
This laser consists of a diffractive lens array (DLA) that delivers pulses 500 μm apart enabling treatment of a larger surface area. It has been found to improve the appearance of rolling scars similar to ablative fractional

lasers. Melanin absorbs the picosecond light that leads to a localized plasma formation in the epidermis, leading to the formation of collagen and elastin and dermal remodeling. By delivering high energy to focused areas, the DLA minimizes complications. A study showed that treatment of facial acne scars with a DLA and 755 nm picosecond laser produced 24.3% mean improvement in scar volume at 3-month follow-up.<sup>[72]</sup>

## SUBCISION

LoE II, SoR B

Subcision or subcutaneous incisionless surgery is a simple technique for the elevation of depressed tethered scars by the introduction of a sharp needle beneath the scar, which breaks the fibrous adhesions and lifts the scar.<sup>[73]</sup> It can be carried out using either a Nokor needle or a disposable hypodermic needle. The sharp bevel of the needle acts like a scalpel and incises the fibrous tissue that binds down the scar [Figure 3]. In addition, the needle-induced trauma

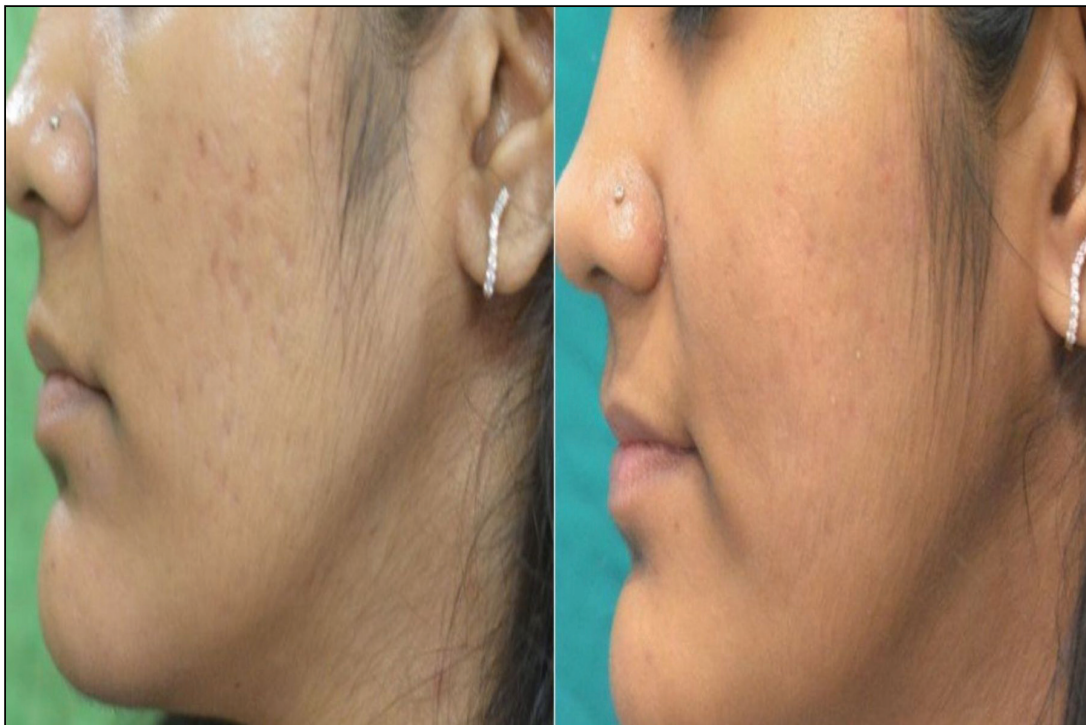

**Figure 3:** Schematic diagram showing cutting of fibrous strands in subcision

leads to the formation of connective tissue beneath the scar, without injuring the epidermis.

Subcision is most useful for rolling scars but can also help partially in the elevation of ice pick and boxcar scars [Figure 4]. It is contraindicated in patients with a bleeding diathesis as well as those on aspirin, vitamin E, or other drugs prolonging bleeding time as it can cause larger hematomas, leading to the formation of persistent fibrous nodules.

The procedure should be performed under infiltration anesthesia. After surgical cleansing, the needle (18–24 G, depending on the size of the scars) is introduced from the edge of the scar into the dermis moving in a horizontal plane. The bevel faces upward. It is then moved back and forth to cover the entire scar and then moved horizontally in a fanning motion to break all adhesions [Video 2]. The endpoint of subcision is a smooth movement of the needle without any grating sound or resistance and a visible lifting of the scars. Light pressure is given after the procedure to prevent a visible bruise or hematoma. Care should be taken not to penetrate deep and injure the vessels. The temporal and preauricular areas are danger areas as the branches of the facial nerve are superficial. Common complications of subcision include pain, bruising, hematoma, swelling, edema, induration, persistent fibrous nodules, and PIH. In an Indian study, the improvement ranged from 40% to 80% in rolling scars.<sup>[74]</sup> Alam *et al.*<sup>[75]</sup> reported improvement in appearance in 90% of the patients. The mean overall degree of improvement was 51%.



**Figure 4:** Improvement in rolling acne scars after two sessions of subcision

Several modifications of subcision have been described in the literature. One modification is bending the needle at right angles with the help of a sterile artery forceps.<sup>[76]</sup> This ensures that the plane of subcision remains horizontal. A further modification is that the needle is further bent at right angles and mounted on a syringe; it becomes a convenient and quick method [Video 3].<sup>[77]</sup> A needle holder can be used to hold the needle to maintain the position of the needle.<sup>[78]</sup> When a wide area of depressed scars is involved, a diamond-shaped subcision can be made using a sterile aspiration needle, called dermal tunneling.<sup>[79]</sup> In this technique, the area to be treated is marked in a diamond shape and subcision is carried out from all four corners. Spinal needle cannula has also been used to reduce the number of pricks.<sup>[80]</sup>

Subcision can be repeated every 2–4 weeks till optimum response is obtained. It has been combined with other techniques, such as fractional CO<sub>2</sub> lasers,<sup>[56]</sup> microneedling, cryoroller,<sup>[81]</sup> or PRP,<sup>[82]</sup> to improve the outcome.

### PUNCH TECHNIQUES FOR ACNE SCARS

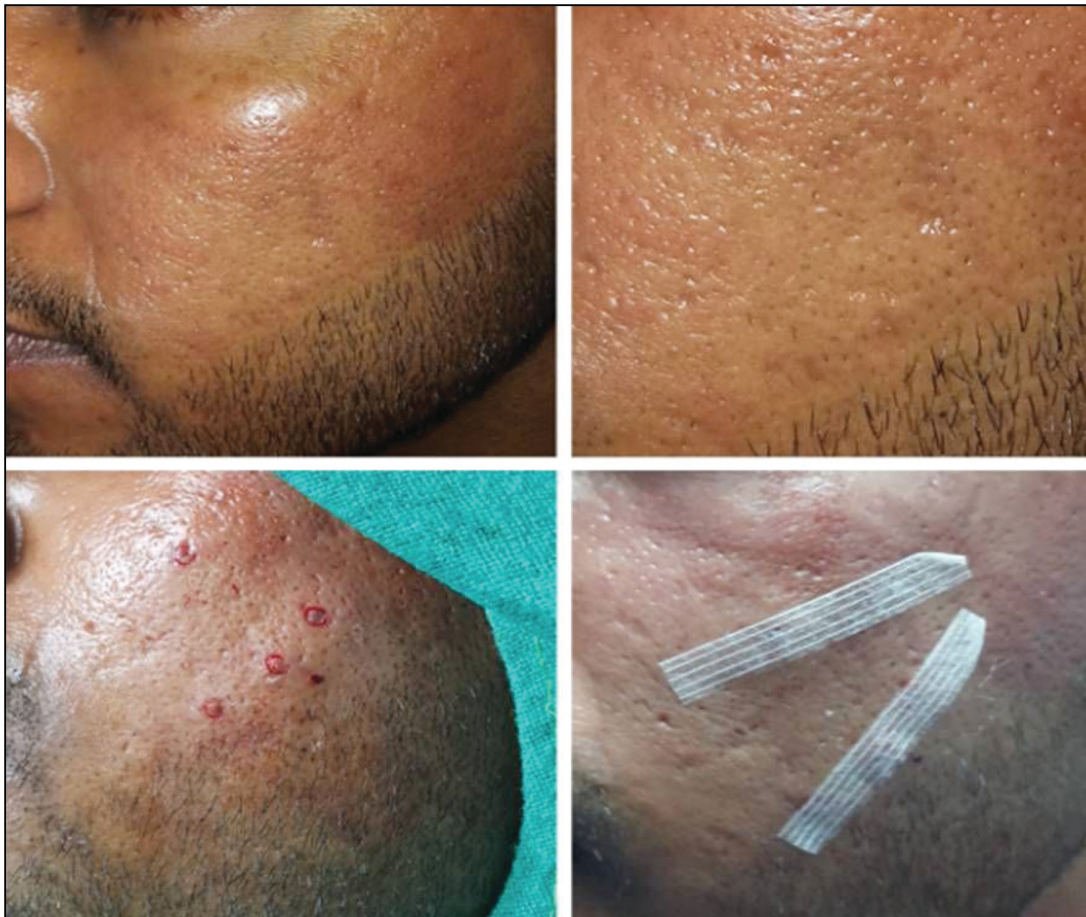Moderate to severe scars: LoE III, SoR C

Punch excision techniques are useful for deep depressed acne scars with sharp vertical walls such as ice pick and

boxcar scars.<sup>[83]</sup> These scars extend to the deep reticular dermis and hence cannot be safely treated with resurfacing techniques alone. Punch techniques include punch elevation, punch excision, or punch grafting. In punch excision, the scar is excised and sutured along the relaxed skin tension lines, thus replacing a wide circular scar with a smaller linear scar. In punch grafting, the scar is excised and replaced by dermis from autologous donor tissue. In punch elevation or punch flotation, the depressed scar is lifted from its bed by breaking the adhesions, which bind down the scar [Figure 5].

If the surface of the scar is atrophic and it is less than 3.5 mm, it is excised out and replaced by a donor punch graft from the postauricular region or gluteal region. If its size is more than 3.5 mm, a punch graft can leave a noticeable ring scar; hence, it is preferable to excise the scar and suture.

The scars that need excision and suturing are tackled first [Figure 6]. In punch excision and grafting, the donor grafts should have a snug fit to prevent a cobblestone appearance. This can be carried out by appropriate trimming of the graft. Grafts can be held in place by surgical glue or Steri-Strips, followed by a nonadherent dressing for 3–5 days. If



**Figure 5:** Punch elevation in grade 4 acne scars

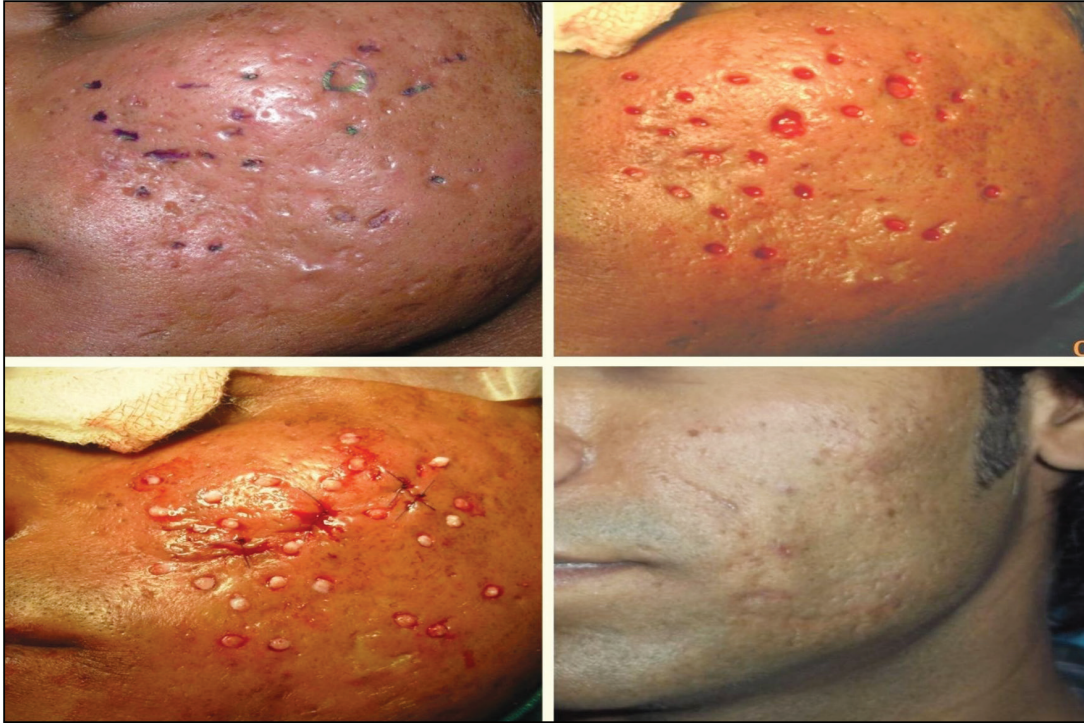


there are many closely packed scars, the procedure can be performed in two or more sessions.

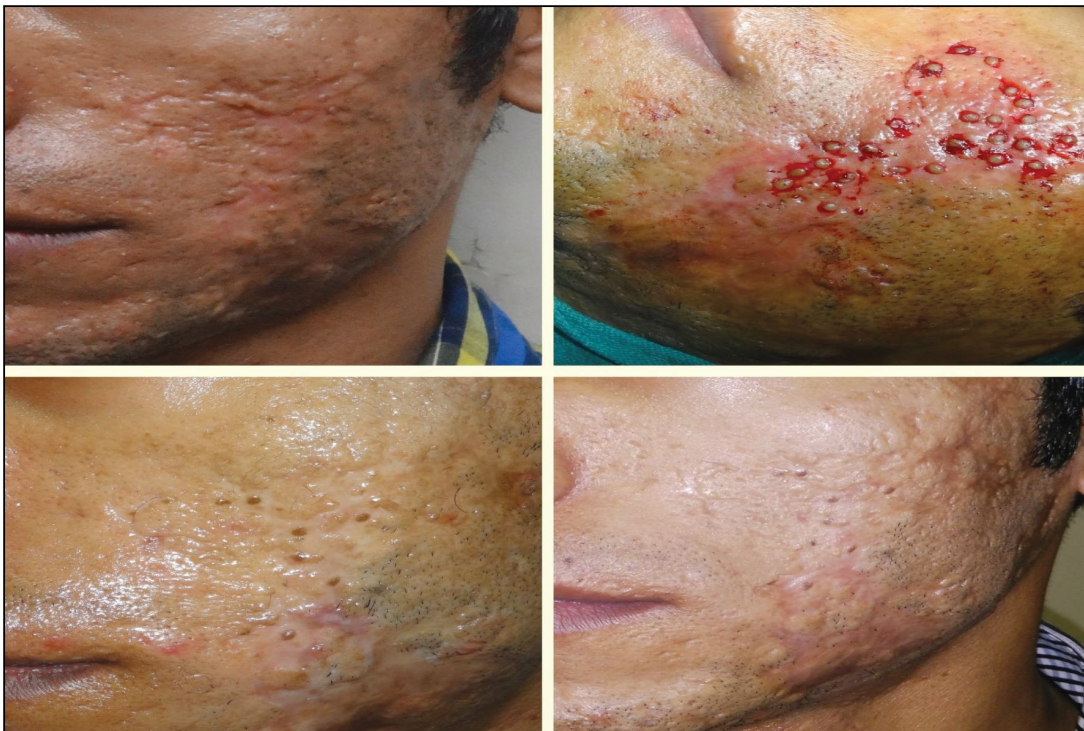Complications include failure-to-take off graft, graft extrusion, cobblestone appearance [Figure 7], PIH, ring scars at the margins of the punch, or widening of

the suture line. Hyperpigmentation can be treated with topical agents, and cobblestone appearance and ring scars by resurfacing.

It is advisable to combine these techniques with subcision either in preceding sessions or in the same session. Punch



**Figure 6:** Combined punch elevation and punch excision in severe acne scars



**Figure 7:** Cobble stoning after punch replacement

excision techniques should be followed by laser resurfacing to optimize results.

## PLATELET-RICH PLASMA AND RELATED TREATMENTS

Platelet-rich plasma (PRP) consists of the patient's plasma that is enriched with a high concentration of platelets. They contain storage pools of numerous growth factors, cytokines, and chemokines. PRP is thought to correct atrophic scarring through the release of growth factors from  $\alpha$ -granules. Another pathway that explains the effect of PRP is the generation of HA, which draws water into the matrix, causing it to swell, creating volume, and skin turgor. HA also promotes cell proliferation and extracellular matrix formation thereby modulating the diameter of the collagen fibers, thus improving atrophic scars. PRP has been studied mostly as adjunctive therapy to other treatment modalities like microneedling and fractional ablative laser.

### PRP and microneedling

LoE I, SoR A

The microneedling and PRP sessions are administered every 2 weeks for a total of 3 to 6 sessions. Both topical and intradermal injections of PRP combined with microneedling showed good results. No studies have compared the effect of topical versus intradermal PRP. A combination of PRP and microneedling showed significantly greater mean improvement (64.87%) compared to microneedling alone (27.87%).<sup>[84]</sup> A similar trend was observed by Porwal *et al.*,<sup>[85]</sup> with 58.58% improvement in the combination group compared to 43.03% in only microneedling patients. In another study, improvement in boxcar and ice pick scars was greater than with rolling scars.<sup>[86]</sup> Chawla *et al.*<sup>[87]</sup> noted that PRP was a better adjunct treatment with microneedling than vitamin C.

### PRP and lasers

LoE I, SoR A

The addition of PRP and L-PRP (leukocyte and PRP) to laser ablation produced added benefits in acne scarring in most of the studies. The variability in laser settings and PRP preparation methods limit the comparison between studies. In a split-face study, excellent to marked improvement was noted in 83% of patients on fractional CO<sub>2</sub> laser combined with PRP compared to 39% with laser alone. PIH occurred in 16.6% of patients on only laser-treated side.<sup>[88]</sup>

### PRP combined with fat graft, subcision, and/or needling

Modarressi<sup>[89]</sup> reported that combining fat with PRP improved fat graft survival. In another study of 40 patients, PRP and subcision showed greater improvement (32.08%) in acne scars after four sessions as compared to subcision alone (8.33%). Rolling acne scars responded best followed by boxcars (33.88%).<sup>[90]</sup> Bhargava *et al.*<sup>[91]</sup> combined PRP with subcision and needling in a randomized study of 30 patients.

Significantly more patients in the PRP group had >50% improvement in scars and the downtime was also less.<sup>[91]</sup>

## AUTOLOGOUS FAT GRAFTING

LoE II, SoR B

The resolution of nodulocystic acne often results in wide areas of depressed scars with loss of tissue, called lipoatrophic acne scars. These scars are more common in the lower cheeks and mandibular area, giving a gaunt and prematurely aged appearance to the patients. They are best treated by a filling substance such as a synthetic filler or autologous fat (lipofilling). Fillers are short-lived and are expensive. Hence, lipofilling is preferred, which also has the advantage of supplying adipose-derived stem cells, which have an important role in the regeneration of collagen.<sup>[92]</sup> Previously, boluses of fat were injected (macrofat and microfat), but results were unpredictable as chances of fat necrosis of the central core of fat tissue were higher. The recent technique to process the fat to finer components (nanofat) gives more predictable results.<sup>[93]</sup>

In this method,<sup>[93]</sup> fat is harvested either from the lower abdomen or the thigh after tumescent anesthesia. After the preparation of nanofat, it is then injected just beneath the dermis to replace lost tissue volume to get a smooth surface [Video 4]. In the treatment of acne scars, it is essential to do subcision and break all adhesions before lipofilling to prevent irregularities and outpouching of fat. Zichun *et al.*<sup>[94]</sup> injected nanofat in 20 patients with atrophic scars and observed significant improvement in the appearance. Azzam *et al.*<sup>[95]</sup> compared three sessions of fractional CO<sub>2</sub> laser versus a single session of autologous fat transfer in 22 patients with acne scars. Fat transfer was more effective in scar treatment. However, long-term follow-up was not available.

The advantages of lipofilling are that it is autologous, easy to obtain, minimal donor site morbidity, and large amounts can be harvested and with minimal downtime. It is easily contoured, feels natural, and has regenerative potential. The disadvantages include a variable retention rate and unpredictability; hence multiple procedures may be required.

## SYNTHETIC FILLERS

Fillers are commonly used in the treatment of facial tissue augmentation, but their role in the treatment of facial acne scars is yet to be fully exploited. To date, polymethyl methacrylate (PMMA) is the only US Food and Drug Administration (FDA)-approved filler for the treatment of atrophic acne scars, with a large randomized controlled trial, supporting its use. Dermal fillers may be considered for boxcar or rolling atrophic acne scars. There is insufficient evidence to support the use of fillers for deeper ice pick scars. Fillers are injected by various techniques such as linear threading, depot,

fanning, layering, and tower to achieve optimum volume augmentation. Commonly used fillers are given in Table 2.

## HA

LoE II, SoR B

Both immediate flattening and short-term improvement is noted after the injection of HA in various studies, but studies having a longer follow-up period are required.<sup>[96]</sup> In a recent modified tower technique for filler injections, the HA is deposited via a perpendicular approach in the deeper tissue plane with a gradual tapering of product deposition as the needle is withdrawn. A series of towers or struts are created to give a flattened look to acne scars.<sup>[97]</sup> Recently in a dual plane injection technique, a small amount of HA was injected in the atrophic dermal component of the scar, followed by subcision. HA was then further placed in the subdermal component.<sup>[98]</sup>

## Calcium hydroxylapatite

LoE II, SoR B

Calcium hydroxylapatite (CaHA) is a synthetic, semipermanent filler. It lasts for up to 18 months. A study of 10 patients showed improvement in boxcar scars but not in ice pick scars.<sup>[99]</sup> Recently, the combination of micro-focused ultrasound with CaHA filler was used with a significant overall improvement in acne scars.<sup>[100]</sup>

## Poly-L-lactic acid

LoE II, SoR B

Poly-L-lactic acid (PLL) is a biodegradable, semipermanent filler. Soft-tissue augmentation may last for up to 2 years. In a study by Sapra *et al.*,<sup>[101]</sup> 22 patients treated with PLL using depot or tunneling technique showed an overall investigator improvement ranging from 45% to 68%. Another study recorded a significant improvement in atrophic acne scars, which lasted up to 4 years.<sup>[102]</sup>

## Polymethyl methacrylate

LoE I, SoR A

PMMA is an inert, synthetic permanent filler. Patient satisfaction rates with PMMA-tissue augmentation are high and the effects long-lasting. In an RCT of PMMA versus placebo, there was 64% versus 33% improvement, respectively.<sup>[103]</sup> Adverse effects can also be long-lasting. Subcision has been combined with PMMA with a 96% improvement rate at the end of 8 months.<sup>[104]</sup>

**Table 2: Classification of various types of fillers used in acne scars**

Temporary	Semipermanent	Permanent
Hyaluronic acid	Poly-L-lactic acid Calcium hydroxylapatite	Polymethyl methacrylate Polyalkylimide Polyacrylamide Silicone

## Polyacrylamide

Polyacrylamide (Aquamid) is a nonabsorbable hydrogel that consists of 2.5% cross-linked polyacrylamide and 97.5% water. Two uncontrolled trials not exclusive for patients with acne scars reported high satisfaction rates but adverse effects, such as swelling, lumpiness, and abscess formation, were seen.<sup>[105]</sup>

## BOTULINUM TOXIN A INJECTION

Hypertrophic scar: LoE III, SoR C

In addition to botulinum toxin's well-known effect on reducing muscular activity, there also appears to be an inhibitory effect on fibroblasts,<sup>[106]</sup> thereby, offering a satisfactory outcome for scar treatment.

In a study comprising 26 Chinese patients, acne scars treated with botulinum toxin A injection showed significant improvement.<sup>[107]</sup>

## COMBINATION AND MULTIMODALITY TREATMENTS

Complete resolution of acne scars is a challenge and rarely achieved with the currently available modalities. Combining different treatments, either sequentially or in the same session, has shown to produce better outcomes. The goal remains to effectively exploit different technologies and treatment modalities to tackle post-inflammatory erythema, pigmentation, different types and depths of scars as well as reduce treatment downtime. Many studies have been conducted combining non-ablative lasers with ablative lasers, subcision, TCA CROSS, and PRP, to achieve an additional rejuvenation effect. Subcision has been combined with fractional lasers and microneedling to take care of deeper scars [Figure 8]. PRP has been used widely with many other modalities for better remodeling of scars and reducing post-procedure inflammation. Dermal fillers and autologous fat transplantation can be effectively combined with resurfacing procedures such as lasers or microneedling to achieve both volume restoration and rejuvenation.

## NEWER AND EXPERIMENTAL TREATMENTS

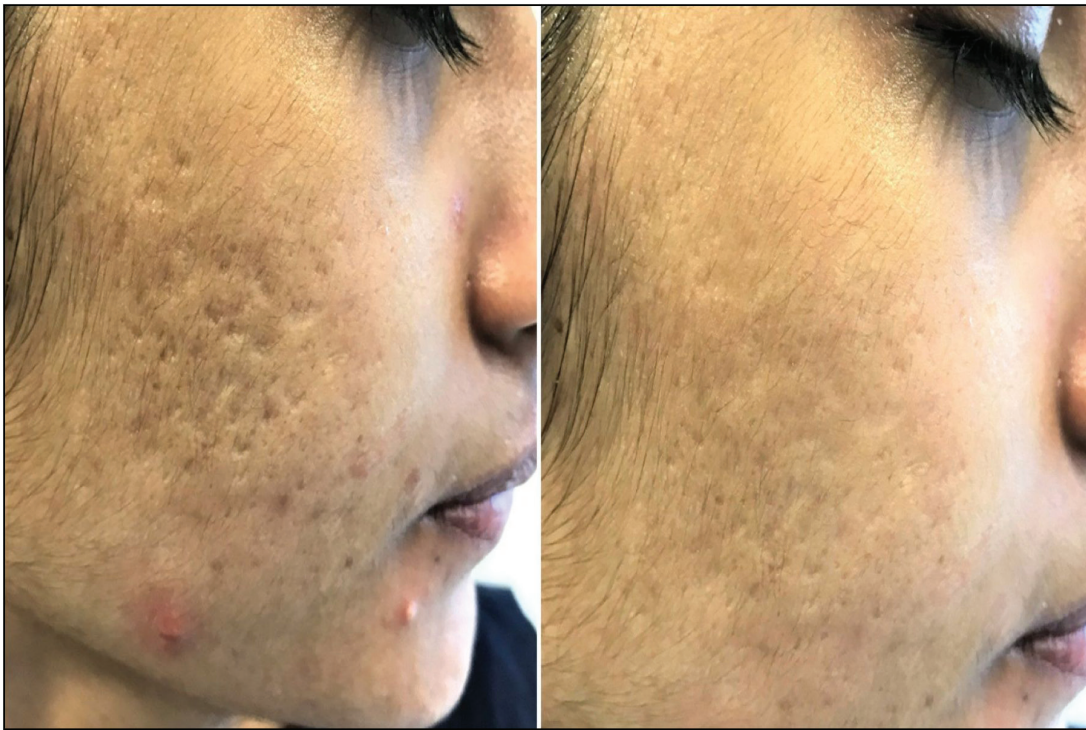### Autologous non-cultured dermal cell suspension

LoE III, SoR C

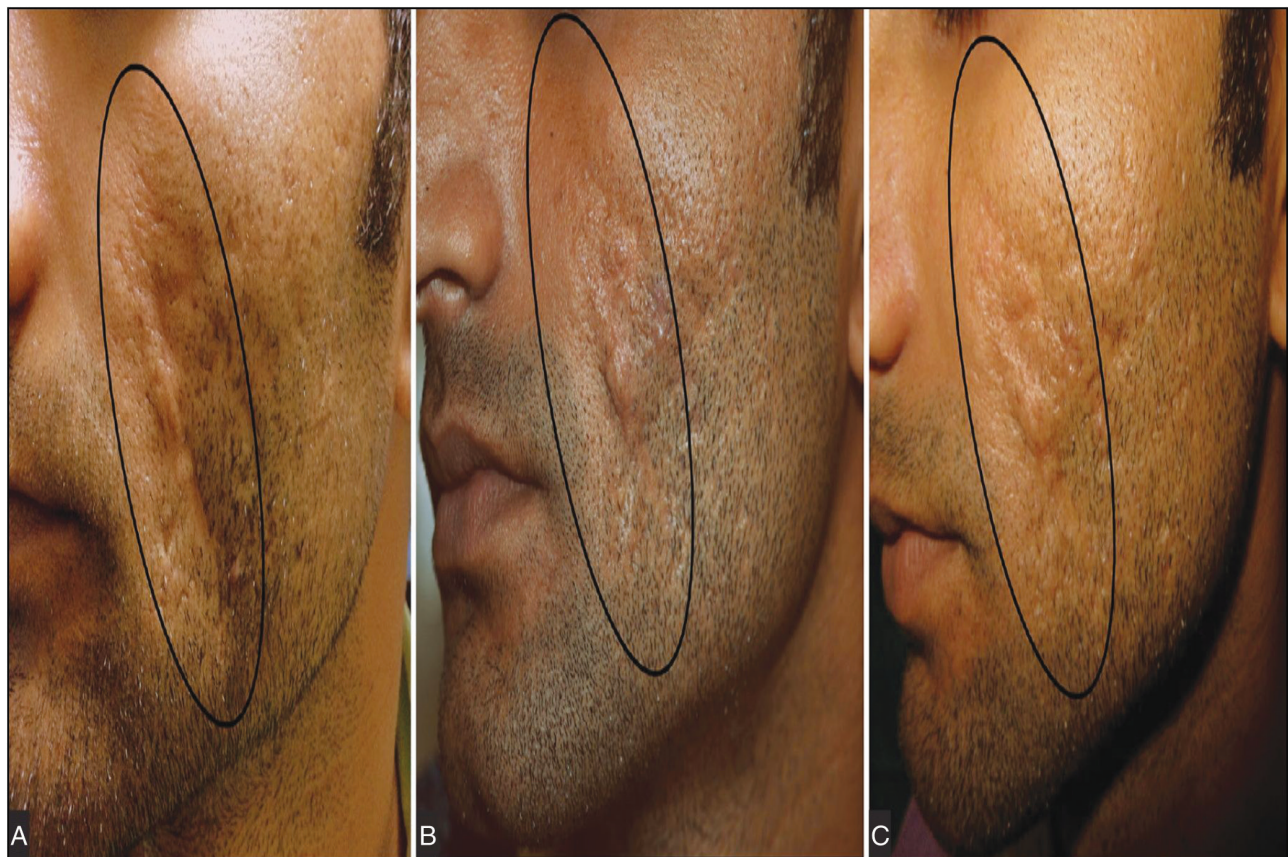In atrophic acne scars, the dermis is lost due to inflammation, therefore dermal suspensions could be an ideal volume replacement. Sahoo *et al.* prepared an autologous non-cultured dermal cell suspension by incubating a de-epithelialized dermal biopsy with collagenase 1. The suspension was then injected to correct localized facial volume loss. This resulted in significant improvement in the dermal atrophy group, but not in the lipoatrophy group [Figure 9].<sup>[108]</sup>

### Autologous fibroblast culture

LoE II, SoR B



**Figure 8:** Acne scar treated with two sessions of subcision, six sessions of MNRF and 30% SA peel



**Figure 9:** Dermal cell suspension in acne scar. (A) Baseline picture. (B) At 3 months showing 50% improvement. (C) At 6 months showing 60% improvement from baseline (Source: Sahoo *et al.*)

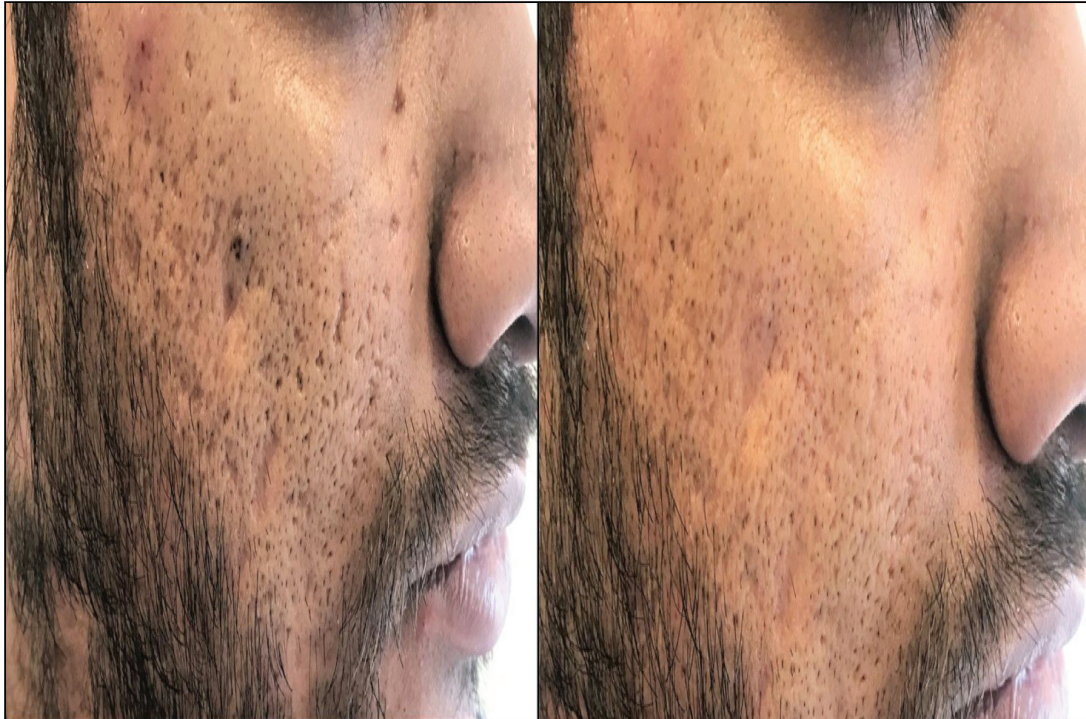Cultured fibroblasts also have been used in a pilot study by Munavalli *et al.*<sup>[109]</sup> They treated 99 patients with injections of autologous cultured fibroblasts into acne scars.<sup>[109]</sup> This was prepared by culturing skin biopsies for fibroblasts for several weeks. This was associated with significantly higher treatment success than the vehicle. There were no permanent side effects. There

was an increasing trend of improvement at 4 months of follow-up.

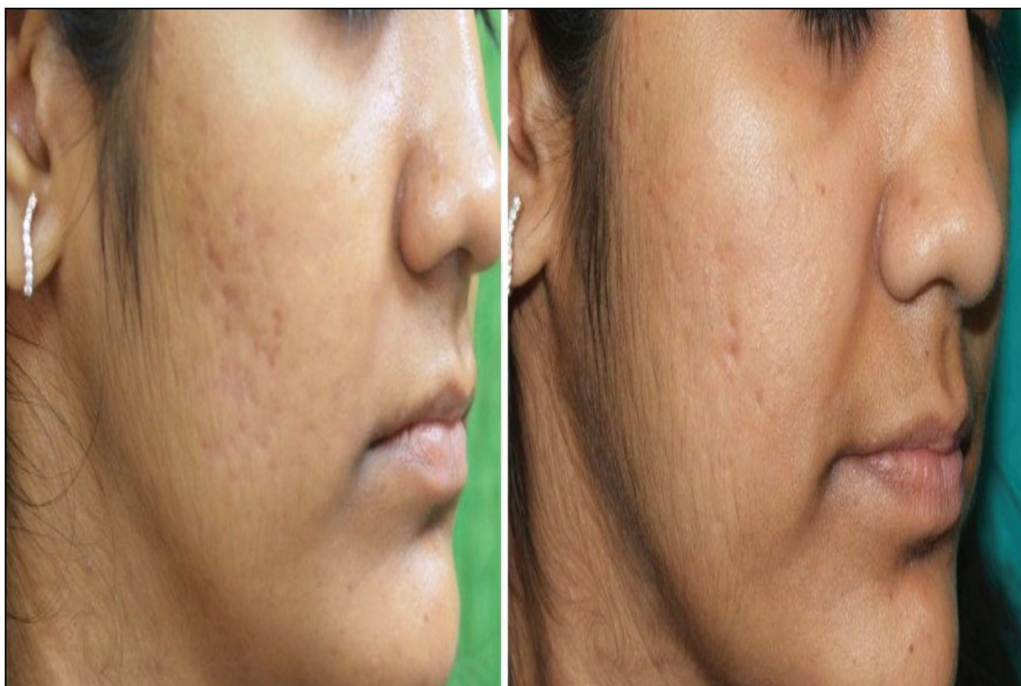### Jet volumetric remodeling

LoE III, SoR C

Jet volumetric remodeling (JVR) is a needle-free proprietary technology; which accurately delivers



**Figure 10:** Pre- and post-treatment picture of combination treatment with subcision, eight sessions of MNRF and one session of JVR



**Figure 11:** Improvement in acne scar with radiofrequency subcision

**Table 3: Level of recommendation for different procedures for acne scars**

		Evidence level	Recommendation	References	
Chemical peel	Superficial scars	III	C	[8-15]	
	Post-acne hyperpigmentation	II	B		
TCA CROSS	Used in ice pick scars	II	B	[16-25]	
Dermabrasion	Superficial and small scars	II	B	[26]	
Microdermabrasion	Mild to moderate scar	II	B	[27-30]	
Microneedling	Mild to moderate	I	A	[31-38]	
Fractional radiofrequency devices	Mild to moderate scars	I	A	[39-45]	
Lasers and light sources	Ablative non-fractional CO <sub>2</sub> laser 10,600 nm	II	B	[50]	
	Ablative Er:YAG	II, III	B, C	[47-49]	
	Fractional CO <sub>2</sub> laser	I	A	[54-58]	
	Fractional Er:YAG	I	A	[60,61]	
	Fractional 1,540 Er:glass	II	B	[63]	
	1,550 nm erbium-doped laser	II	B	[66]	
	PDL Erythematous and hypertrophic	I	A	[68,69]	
	1,064 Q-switched Nd:YAG	II	B	[62]	
	Subcision	All types	II	B	[74-81]
	Punch techniques	Moderate to severe	III	C	[83]
PRP and related treatments	PRP with dermaroller	I	A	[85-87]	
	PRP with fractional lasers	I	A	[88]	
	PRP with subcision	I	A	[90,91]	
Autologous fat grafting		II	B	[92-95]	
Synthetic fillers	HA	II	B	[96-98]	
	PLLA	II	B	[101,102]	
	PMMA	I	A	[103,104]	
	CH	II	B	[99,100]	
Botulinum toxin A injection	Hypertrophic	III	C	[107]	
Combination treatments	Subcision with MNRF	I	A	[112]	
	Subcision with fractional CO <sub>2</sub>	I	A	[56]	
	Subcision with microneedling	II	B	[91]	
	Microneedling with GA peel	I	A	[113]	
	Fractional ablative with MNRF	I	A	[45]	
	Fractional CO <sub>2</sub> with autologous fat	II	B	[114]	
	Punch elevation with fractional CO <sub>2</sub>	III	C	[115]	
PRP with nanofat	I	A	[89]		

PLLA = Poly-L-lactic acid, CH = Calcium Hydroxyapatite

kinetic energy and a healing compound at a high speed simultaneously via a tiny entry point in the epidermis [Video 5, Figure 10]. The particles, acting as nano-bullets, disperse in the dermis to create a microtrauma, which promotes neocollagenesis. The JVR device using HA has been used to treat acne scars in two patients in two sessions showing some improvement. There was minimal downtime.<sup>[109]</sup>

### Radiofrequency subcision

LoE III, SoR C

This modification of subcision uses radiofrequency energy for subcision. This method decreases the chances of postoperative bleeding and hematoma formation. The fibrotic strands get cut with ease without any mechanical force [Video 6, Figure 11].<sup>[110-115]</sup>

## TREATMENT RECOMMENDATION SUMMARY

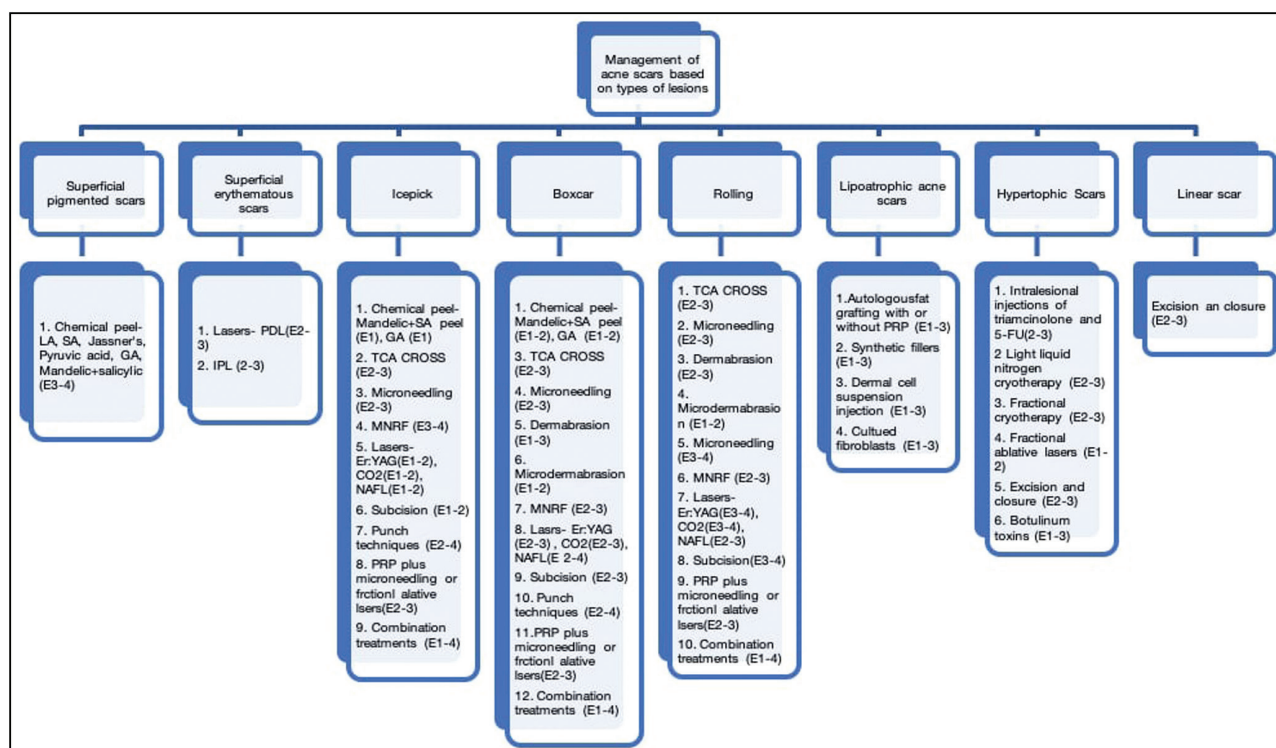
Treatment recommendation summary is given in Figure 12.

## EVIDENCE-BASED RECOMMENDATIONS

Table 3 summarizes the level of recommendations for different procedures for acne scars.

### Declaration of patient consent

The authors certify that they have obtained all appropriate patient consent forms. In the form the patient(s) has/have given his/her/their consent for his/her/their images and other clinical information to be reported in the journal. The patients understand that their names and initials will not be published and due efforts will be made to conceal their identity, but anonymity cannot be guaranteed.



**Figure 12:** Recommendation summary for management of acne scars

### Financial support and sponsorship

Nil.

### Conflicts of interest

There are no conflicts of interest.

### REFERENCES

- Jacob CI, Dover JS, Kaminer MS. Acne scarring: A classification system and review of treatment options. *J Am Acad Dermatol* 2001;45:109-17.
- Fabbrocini G, Annunziata MC, D'Arco V, De Vita V, Lodi G, Mauriello MC, *et al.* Acne scars: Pathogenesis, classification and treatment. *Dermatol Res Pract* 2010;2010:893080.
- Boen M, Jacob C. A review and update of treatment options using the acne scar classification system. *Dermatol Surg* 2019;45:411-22.
- Clark AK, Saric S, Sivamani RK. Acne scars: How do we grade them? *Am J Clin Dermatol* 2018;19:139-44.
- Ebell MH, Siwek J, Weiss BD, Woolf SH, Susman J, Ewigman B, *et al.* Strength of recommendation taxonomy (SORT): A patient-centered approach to grading evidence in the medical literature. *Am Fam Physician* 2004;69:548-56.
- Kontochristopoulos G, Platsidaki E. Chemical peels in active acne and acne scars. *Clin Dermatol* 2017;35:179-82.
- Sachdeva S. Lactic acid peeling in superficial acne scarring in Indian skin. *J Cosmet Dermatol* 2010;9:246-8.
- Puri N. Efficacy of modified Jessner's peel and 20% TCA versus 20% TCA peel alone for the treatment of acne scars. *J Cutan Aesthet Surg* 2015;8:42-5.
- Al-Waiz MM, Al-Sharqi AI. Medium-depth chemical peels in the treatment of acne scars in dark-skinned individuals. *Dermatol Surg* 2002;28:383-7.
- Berardesca E, Cameli N, Primavera G, Carrera M. Clinical and instrumental evaluation of skin improvement after treatment with a new 50% pyruvic acid peel. *Dermatol Surg* 2006;32:526-31.
- Chandrashekar BS, Ashwini KR, Vasanth V, Navale S. Retinoic acid and glycolic acid combination in the treatment of acne scars. *Indian Dermatol Online J* 2015;6:84-8.
- Sharad J. Combination of microneedling and glycolic acid peels for the treatment of acne scars in dark skin. *J Cosmet Dermatol* 2011;10:317-23.
- Kurokawa I, Oiso N, Kawada A. Adjuvant alternative treatment with chemical peeling and subsequent iontophoresis for postinflammatory hyperpigmentation, erosion with inflamed red papules and non-inflamed atrophic scars in acne vulgaris. *J Dermatol* 2017;44:401-5.
- Garg VK, Sinha S, Sarkar R. Glycolic acid peels versus salicylic-mandelic acid peels in active acne vulgaris and post-acne scarring and hyperpigmentation: A comparative study. *Dermatol Surg* 2009;35:59-65.
- Park JH, Choi YD, Kim SW, Kim YC, Park SW. Effectiveness of modified phenol peel (Exoderm) on facial wrinkles, acne scars and other skin problems of Asian patients. *J Dermatol* 2007;34:17-24.
- Lee JB, Chung WG, Kwahck H, Lee KH. Focal treatment of acne scars with trichloroacetic acid: Chemical reconstruction of skin scars method. *Dermatol Surg* 2002;28:1017-21; discussion 1021.
- Agarwal N, Gupta LK, Khare AK, Kuldeep CM, Mittal A. Therapeutic response of 70% trichloroacetic acid CROSS in atrophic acne scars. *Dermatol Surg* 2015;41:597-604.
- Khunger N, Bhardwaj D, Khunger M. Evaluation of CROSS technique with 100% TCA in the management of ice pick acne scars in darker skin types. *J Cosmet Dermatol* 2011;10:51-7.
- Stegman SJ. A comparative histologic study of the effects of three peeling agents and dermabrasion on normal and sun damaged skin. *Aesthet Plast Surg* 1982;6:123-35.
- Dalpizzol M, Weber MB, Mattiazzi AP, Manzoni AP. Comparative study of the use of trichloroacetic acid and phenolic acid in the treatment of atrophic-type acne scars. *Dermatol Surg* 2016;42:377-83.
- Kaur J, Kalsy J. Subcision plus 50% trichloroacetic acid chemical reconstruction of skin scars in the management of atrophic acne scars: A cost-effective therapy. *Indian Dermatol Online J* 2014;5:95-7.

22. Kang WH, Kim YJ, Pyo WS, Park SJ, Kim JH. Atrophic acne scar treatment using triple combination therapy: Dot peeling, subcision and fractional laser. *J Cosmet Laser Ther* 2009;11:212-5.
23. Dhollan N, Thirunavukkarasu V. Microneedling vs. chemical reconstruction of skin scars with trichloroacetic acid: A comparative study. *Int J Res Dermatol* 2017;3:277-81.
24. Ramadan SA, El-Komy MH, Bassiouny DA, El-Tobshy SA. Subcision versus 100% trichloroacetic acid in the treatment of rolling acne scars. *Dermatol Surg* 2011;37:626-33.
25. Kim HJ, Kim TG, Kwon YS, Park JM, Lee JH. Comparison of a 1,550nm erbium: Glass fractional laser and a chemical reconstruction of skin scars (CROSS) method in the treatment of acne scars: A simultaneous split-face trial. *Lasers Surg Med* 2009;41:545-9.
26. Aronsson A, Eriksson T, Jacobsson S, Salemark L. Effects of dermabrasion on acne scarring. A review and a study of 25 cases. *Acta Derm Venereol* 1997;77:39-42.
27. Tsai RY, Wang CN, Chan HL. Aluminum oxide crystal microdermabrasion. A new technique for treating facial scarring. *Dermatol Surg* 1995;21:539-42.
28. Spencer JM. Microdermabrasion. *Am J Clin Dermatol* 2005;6:89-92.
29. Bhalla M. Comparative efficacy of microdermabrasion versus microneedling in post acne scarring in pigmented skin. *J ClinExp Dermatol Res* 2016;7:4.
30. El-Domyati M, Hosam W, Abdel-Azim E, Abdel-Wahab H, Mohamed E. Microdermabrasion: A clinical, histometric, and histopathologic study. *J Cosmet Dermatol* 2016;15:503-13.
31. Doddaballapur S. Microneedling with dermaroller. *J Cutan Aesthet Surg* 2009;2:110-1.
32. Singh A, Yadav S. Microneedling: Advances and widening horizons. *Indian Dermatol Online J* 2016;7:244-54.
33. El-Domyati M, Barakat M, Awad S, Medhat W, El-Fakahany H, Farag H. Microneedling therapy for atrophic acne scars: An objective evaluation. *J Clin Aesthet Dermatol* 2015;8:36-42.
34. Saadawi AN, Esawy AM, Kandeel AH, El-Sayed W. Microneedling by Dermapen and glycolic acid peel for the treatment of acne scars: Comparative study. *J Cosmet Dermatol* 2019;18:107-14.
35. Minh PPT, Bich DD, Hai VNT, Van TN, Cam VT, Khang TH, *et al.* Microneedling therapy for atrophic acne scar: Effectiveness and safety in Vietnamese patients. *Open Access Maced J Med Sci* 2019;7:293-7.
36. Moftah NH, El Khayyat MAM, Ragai MH, Alaa H. Carboxytherapy versus skin microneedling in treatment of atrophic postacne scars: A comparative clinical, histopathological, and histometrical study. *Dermatol Surg* 2018;44:1332-41.
37. Afra TP, Razmi TM, Narang T, Dogra S, Kumar A. Topical tazarotene gel, 0.1%, as a novel treatment approach for atrophic postacne scars: a randomized active-controlled clinical trial. *JAMA Facial Plast Surg* 2019;21:125-32.
38. Osman MA, Shokeir HA, Fawzy MM. Fractional erbium-doped yttrium aluminum garnet laser versus microneedling in treatment of atrophic acne scars: A randomized split-face clinical study. *Dermatol Surg* 2017;43:47-56.
39. Ruiz-Esparza J, Gomez JB. The medical face lift: A noninvasive, nonsurgical approach to tissue tightening in facial skin using nonablative radiofrequency. *Dermatol Surg* 2003;29:325-32; discussion 332.
40. Zheng Z, Goo B, Kim DY, Kang JS, Cho SB. Histometric analysis of skin-radiofrequency interaction using a fractionated microneedle delivery system. *Dermatol Surg* 2014;40:134-41.
41. Cho SI, Chung BY, Choi MG, Baek JH, Cho HJ, Park CW, *et al.* Evaluation of the clinical efficacy of fractional radiofrequency microneedle treatment in acne scars and large facial pores. *Dermatol Surg* 2012;38:1017-24.
42. Pudukadan D. Treatment of acne scars on darker skin types using a noninsulated smooth motion, electronically controlled radiofrequency microneedles treatment system. *Dermatol Surg* 2017;43:64-9.
43. Chandrashekar BS, Sriram R, Mysore R, Bhaskar S, Shetty A. Evaluation of microneedling fractional radiofrequency device for treatment of acne scars. *J Cutan Aesthet Surg* 2014;7:93-7.
44. Chae WS, Seong JY, Jung HN, Kong SH, Kim MH, Suh HS, *et al.* Comparative study on efficacy and safety of 1550nm Er:glass fractional laser and fractional radiofrequency microneedle device for facial atrophic acne scar. *J Cosmet Dermatol* 2015;14:100-6.
45. Yeung CK, Chan NP, Shek SY, Chan HH. Evaluation of combined fractional radiofrequency and fractional laser treatment for acne scars in Asians. *Lasers Surg Med* 2012;44:622-30.
46. Mysore V, Mahadevappa OH, Barua S, Majid I, Viswanath V, Bhat RM, *et al.* Standard guidelines of care: Performing procedures in patients on or recently administered with isotretinoin. *J Cutan Aesthet Surg* 2017;10:186-94.
47. Jeong JT, Kye YC. Resurfacing of pitted facial acne scars with a long-pulsed Er:YAG laser. *Dermatol Surg* 2001;27:107-10.
48. Woo SH, Park JH, Kye YC. Resurfacing of different types of facial acne scar with short-pulsed, variable-pulsed, and dual-mode Er:YAG laser. *Dermatol Surg* 2004;30:488-93.
49. Hu S, Gold MH. Treatment of facial acne scars in Asian skin with the single-spot, 2940-nm Er:YAG dual-mode laser. *J Drugs Dermatol* 2010;9:1341-4.
50. Xu Y, Deng Y. Ablative fractional CO<sub>2</sub> laser for facial atrophic acne scars. *Facial Plast Surg* 2018;34:205-19.
51. Sardana K, Garg VK, Arora P, Khurana N. Histological validity and clinical evidence for use of fractional lasers for acne scars. *J Cutan Aesthet Surg* 2012;5:75-90.
52. Sardana K, Manjhi M, Garg VK, Sagar V. Which type of atrophic acne scar (ice-pick, boxcar, or rolling) responds to nonablative fractional laser therapy? *Dermatol Surg* 2014;40:288-300.
53. Chan HH, Manstein D, Yu CS, Shek S, Kono T, Wei WI. The prevalence and risk factors of post-inflammatory hyperpigmentation after fractional resurfacing in Asians. *Lasers Surg Med* 2007;39:381-5.
54. Manuskiatti W, Triwongwanat D, Varothai S, Eimpunth S, Wanitphakdeedecha R. Efficacy and safety of a carbon-dioxide ablative fractional resurfacing device for treatment of atrophic acne scars in Asians. *J Am Acad Dermatol* 2010;63:274-83.
55. Ochi H, Tan L, Tan WP, Goh CL. Treatment of facial acne scarring with fractional carbon dioxide laser in Asians, a retrospective analysis of efficacy and complications. *Dermatol Surg* 2017;43:1137-43.
56. Nilforoushadeh MA, Faghihi G, Jaffary F, Haftbaradaran E, Hoseini SM, Mazaheri N. Fractional carbon dioxide laser and its combination with subcision in improving atrophic acne scars. *Adv Biomed Res* 2017;6:20.
57. Huang L. A new modality for fractional CO<sub>2</sub> laser resurfacing for acne scars in Asians. *Lasers Med Sci* 2013;28:627-32.
58. Majid I, Imran S. Fractional CO<sub>2</sub> laser resurfacing as monotherapy in the treatment of atrophic facial acne scars. *J Cutan Aesthet Surg* 2014;7:87-92.
59. You HJ, Kim DW, Yoon ES, Park SH. Comparison of four different lasers for acne scars: Resurfacing and fractional lasers. *J Plast Reconstr Aesthet Surg* 2016;69:e87-95.
60. Chathra N, Mysore V. Resurfacing of facial acne scars with a new variable pulsed Er:YAG laser in Fitzpatrick skin types IV and V. *J Cutan Aesthet Surg* 2018;11:20-5.
61. Nirmal B, Pai SB, Sripathi H, Rao R, Prabhu S, Kudur MH, *et al.* Efficacy and safety of erbium-doped yttrium aluminium garnet fractional resurfacing laser for treatment of facial acne scars. *Indian J Dermatol Venereol Leprol* 2013;79:193-8.
62. Maluki AH, Mohammad FH. Treatment of atrophic facial scars of acne vulgaris by Q-switched Nd:YAG (neodymium: yttrium-aluminum-garnet) laser 1064nm wavelength. *J Cosmet Laser Ther* 2012;14:224-33.
63. Yoo KH, Ahn JY, Kim JY, Li K, Seo SJ, Hong CK. The use of 1540nm fractional photothermolysis for the treatment of acne scars in Asian skin: A pilot study. *Photodermatol Photoimmunol Photomed* 2009;25:138-42.
64. Sardana K, Manjhi M, Garg VK, Sagar V. Which type of atrophic acne scar (ice-pick, boxcar, or rolling) responds to nonablative fractional laser therapy? *Dermatol Surg* 2014;40:288-300.
65. Lee HS, Lee JH, Ahn GY, Lee DH, Shin JW, Kim DH, *et al.* Fractional photothermolysis for the treatment of acne scars: A report of 27 Korean patients. *J Dermatolog Treat* 2008;19:45-9.



66. Mahmoud BH, Srivastava D, Janiga JJ, Yang JJ, Lim HW, Ozog DM. Safety and efficacy of erbium-doped yttrium aluminum garnet fractionated laser for treatment of acne scars in type IV to VI skin. *Dermatol Surg* 2010;36:602-9.
67. Friedman PM, Jih MH, Skover GR, Payonk GS, Kimyai-Asadi A, Geronemus RG. Treatment of atrophic facial acne scars with the 1064-nm Q-switched Nd:YAG laser: Six-month follow-up study. *Arch Dermatol* 2004;140:1337-41.
68. Alster TS, McMeekin TO. Improvement of facial acne scars by the 585 nm flashlamp-pumped pulsed dye laser. *J Am Acad Dermatol* 1996;35:79-81.
69. Patel N, Clement M. Selective nonablative treatment of acne scarring with 585 nm flashlamp pulsed dye laser. *Dermatol Surg* 2002;28:942-5; discussion 945.
70. Bellew SG, Lee C, Weiss MA, Weiss RA. Improvement of atrophic acne scars with a 1,320 nm Nd:YAG laser: Retrospective study. *Dermatol Surg* 2005;31:1218-21; discussion 1222.
71. Mathew ML, Karthik R, Mallikarjun M, Bhute S, Varghese A. Intense pulsed light therapy for acne-induced post-inflammatory erythema. *Indian Dermatol Online J* 2018;9:159-64.
72. Brauer JA, Kazlouskaya V, Alabdulrazzaq H, Bae YS, Bernstein LJ, Anolik R, *et al.* Use of a picosecond pulse duration laser with specialized optic for treatment of facial acne scarring. *JAMA Dermatol* 2015;151:278-84.
73. Khunger N. Subcision. In: *Step by step acne scars*. New Delhi, India: Jaypee Brothers Medical; 2014. pp 76-88.
74. Al-Dhalimi MA, Arnoos AA. Subcision for treatment of rolling acne scars in Iraqi patients: A clinical study. *J Cosmet Dermatol* 2012;11:144-50.
75. Alam M, Omura N, Kaminer MS. Subcision for acne scarring: Technique and outcomes in 40 patients. *Dermatol Surg* 2005;31:310-7.
76. Khunger N, Khunger M. Subcision for depressed facial scars made easy using a simple modification. *Dermatol Surg* 2011;37:514-7.
77. Alsufyani MA, Alsufyani MA. Subcision: a further modification, an ever continuing process. *Dermatol Res Pract* 2012;2012:685347.
78. AlGhamdi KM, Al Ghamdi KM. A better way to hold a Nokor needle during subcision. *Dermatol Surg* 2008;34:378-9.
79. Lima EV. Dermal tunneling: A proposed treatment for depressed scars. *An Bras Dermatol* 2016;91:697-9.
80. Nilforoushadeh M, Lotfi E, Nickkholgh E, Salehi B, Shokrani M. Can subcision with the cannula be an acceptable alternative method in treatment of acne scars? *Med Arch* 2015;69:384-6.
81. Gadkari R, Nayak C. A split-face comparative study to evaluate efficacy of combined subcision and dermaroller against combined subcision and cryoroller in treatment of acne scars. *J Cosmet Dermatol* 2014;13:38-43.
82. Long T, Gupta A, Ma S, Hsu S. Platelet-rich plasma in non-invasive procedures for atrophic acne scars: A systematic review and meta-analysis. *J Cosmet Dermatol* 2020 Feb 15. [Epub ahead of print].
83. Khunger N; IADVL Task Force. Standard guidelines of care for acne surgery. *Indian J Dermatol Venereol Leprol* 2008;74:S28-36.
84. El-Domyati M, Abdel-Wahab H, Hossam A. Microneedling combined with platelet-rich plasma or trichloroacetic acid peeling for management of acne scarring: A split-face clinical and histologic comparison. *J Cosmet Dermatol* 2018;17:73-83.
85. Porwal S, Chahar YS, Singh PK. A comparative study of combined dermaroller and platelet-rich plasma versus dermaroller alone in acne scars and assessment of quality of life before and after treatment. *Indian J Dermatol* 2018;63:403-8.
86. Ibrahim ZA, El-Ashmawy AA, Shora OA. Therapeutic effect of microneedling and autologous platelet-rich plasma in the treatment of atrophic scars: A randomized study. *J Cosmet Dermatol* 2017;16:388-99.
87. Chawla S. Split face comparative study of microneedling with PRP versus microneedling with vitamin C in treating atrophic post acne scars. *J Cutan Aesthet Surg* 2014;7:209-12.
88. Abdel-Maguid EM, Awad SM, Hassan YS, El-Mokhtar MA, El-Deek HE, Mekkawy MM. Efficacy of stem cell-conditioned medium vs platelet-rich plasma as an adjuvant to post-ablative fractional CO<sub>2</sub> laser resurfacing for atrophic post-acne scars: A split-face clinical trial. *J Dermatolog Treat* 2019;10:1-24.
89. Modarressi A. Platelet rich plasma (PRP) improves fat grafting outcomes. *World J Plast Surg* 2013;2:6-13.
90. Deshmukh NS, Belgaumkar VA. Platelet-rich plasma augments subcision in atrophic acne scars: A split-face comparative study. *Dermatol Surg* 2019;45:90-8.
91. Bhargava S, Kroumpouzou G, Varma K, Kumar U. Combination therapy using subcision, needling, and platelet-rich plasma in the management of grade 4 atrophic acne scars: A pilot study. *J Cosmet Dermatol* 2019;18:1092-7.
92. Coleman SR, Katzel EB. Fat grafting for facial filling and regeneration. *Clin Plast Surg* 2015;42:289-300, vii.
93. Bhooshan LS, Geetha Devi M, Aniraj R, Binod P, Lekshmi M. Autologous emulsified fat injection for rejuvenation of scars: A prospective observational study. *Indian J Plast Surg* 2018;51:77-83.
94. Zichun Gu MS, Yirun Li BS, Hua Li BS. Use of condensed nanofat combined with fat grafts to treat atrophic scars. *JAMA Facial Plast Surg* 2018;20:128-35.
95. Azzam OA, Atta AT, Sobhi RM, Mostafa PI. Fractional CO(2) laser treatment vs autologous fat transfer in the treatment of acne scars: A comparative study. *J Drugs Dermatol* 2013;12:e7-13.
96. Dierickx C, Larsson MK, Blomster S. Effectiveness and safety of acne scar treatment with nonanimal stabilized hyaluronic acid gel. *Dermatol Surg* 2018;44:10-8.
97. Goodman GJ, Van Den Broek A. The modified tower vertical filler technique for the treatment of post-acne scarring. *Australas J Dermatol* 2016;57:19-23.
98. Artzi O, Cohen S, Koren A, Niv R, Friedman O. Dual-plane hyaluronic acid treatment for atrophic acne scars. *J Cosmet Dermatol* 2020;19:69-74.
99. Goldberg DJ, Amin S, Hussain M. Acne scar correction using calcium hydroxylapatite in a carrier-based gel. *J Cosmet Laser Ther* 2006;8:134-6.
100. Casabona G. Combined use of microfocused ultrasound and a calcium hydroxylapatite dermal filler for treating atrophic acne scars: A pilot study. *J Cosmet Laser Ther* 2018;20:301-6.
101. Sapra S, Stewart JA, Mraud K, Schupp R. A Canadian study of the use of poly-L-lactic acid dermal implant for the treatment of hill and valley acne scarring. *Dermatol Surg* 2015;41:587-94.
102. Beer K. A single-center, open-label study on the use of injectable poly-L-lactic acid for the treatment of moderate to severe scarring from acne or varicella. *Dermatol Surg* 2007;33:S159-67.
103. Karnik J, Baumann L, Bruce S, Callender V, Cohen S, Grimes P, *et al.* A double-blind, randomized, multicenter, controlled trial of suspended polymethyl methacrylate microspheres for the correction of atrophic facial acne scars. *J Am Acad Dermatol* 2014;71:77-83.
104. Epstein RE, Spencer JM. Correction of atrophic scars with artefill: An open-label pilot study. *J Drugs Dermatol* 2010;9:1062-4.
105. von Buelow S, von Heimburg D, Pallua N. Efficacy and safety of polyacrylamide hydrogel for facial soft-tissue augmentation. *Plast Reconstr Surg* 2005;116:1137-46; discussion 1147-8.
106. Zhibo X, Miaobo Z. Botulinum toxin type A affects cell cycle distribution derived of fibroblasts from hypertrophic scar. *J Plast Reconstr Aesthet Surg* 2008;61:1128-9.
107. Hong Suzhuang, Zhang Jingjing, Hong Fan. Long-term effect of botulinum toxin type A injection on hypertrophic acne scar. *Chinese Journal of Plastic Surgery* 2016;32:432-7.
108. Sahoo AK, Yadav S, Sharma VK, Parihar AS, Vyas S, Gupta S. Safety and efficacy of autologous noncultured dermal cell suspension transplantation in the treatment of localized facial volume loss: A pilot study. *Indian J Dermatol Venereol Leprol* 2019;85:44-50.
109. Munavalli GS, Smith S, Maslowski JM, Weiss RA. Successful treatment of depressed, distensible acne scars using autologous fibroblasts: A multi-site, prospective, double blind, placebo-controlled clinical trial. *Dermatol Surg* 2013;39:1226-36.
110. Patel T, Tevet O. Effective treatment of acne scars using pneumatic injection of hyaluronic acid. *J Drugs Dermatol* 2015; 14:74-6.
111. Yadav S, Gupta S. Radiofrequency-assisted subcision for postacne scars. *J Am Acad Dermatol* 2018;78:e9-10.

112. Faghihi G, Poostiyan N, Asilian A, Abtahi-Naeini B, Shahbazi M, Iraj F, *et al.* Efficacy of fractionated microneedle radiofrequency with and without adding subcision for the treatment of atrophic facial acne scars: A randomized split-face clinical study. *J Cosmet Dermatol* 2017;16: 223-29.
113. Rana S, Mendiratta V, Chander R. Efficacy of microneedling with 70% glycolic acid peel vs microneedling alone in treatment of atrophic acne scars-A randomized controlled trial. *J Cosmet Dermatol* 2017;16:454-459.
114. Tenna S, Cogliandro A, Barone M, Panasiti V, Tirindelli M *et al.* Comparative study using autologous fat grafts plus platelet-rich plasma with or without fractional CO<sub>2</sub> laser resurfacing in treatment of acne scars: Analysis of outcomes and satisfaction with FACE-Q. *Aesth Plast Surg* 2017;41:661-6.
115. Faghihi G, Nouraei S, Asilian A, Keyvan S, Abtahi-Naeini B, Rakhshanpour M, *et al.* Efficacy of punch elevation combined with fractional carbon dioxide laser resurfacing in facial atrophic acne scarring: A randomized split-face clinical study. *Indian J Dermatol* 2015;60:473-8.