



Innovations

Seal and heal: A novel deal for periungual wart

Sanjeev Gupta¹, Ravi Shankar Jangra², Aditi Dabhra¹, Namya Gupta³

¹Department of Dermatology, Venerology and Leprosy, Maharishi Markandeshwar Institute of Medical Science and Research, Mullana, ²Department of Dermatology, Sun Skin Clinic, Ambala, ³Department of Dermatology, Kalpana Chawla Government Medical College, Karnal, Haryana, India.

***Corresponding author:**

Sanjeev Gupta,
Professor and Head,
Department of Dermatology,
Venerology and Leprosy,
Maharishi Markandeshwar
Institute of Medical Science and
Research, Mullana, Haryana,
India.

sanjeevguptadr@gmail.com

Received: 22 October 2024
Accepted: 09 January 2025
Epub Ahead of Print: 18 February 2025
Published:

DOI
10.25259/JCAS_105_2024

Quick Response Code:



ABSTRACT

Periungual warts are a common yet challenging dermatological condition, often resistant to conventional treatments due to various factors that make these warts notoriously resistant to conventional treatment. We propose an innovative solution to this problem.

Keywords: Wart, Periungual, Innovation, Occlusion, Topical therapy

PROBLEM STATEMENT

Periungual warts are a common dermatological condition often encountered in outpatient settings [Figure 1]. These are caused by Human papillomavirus-1, 2, and 4.¹ Due to their proximity to the nails, periungual warts can be particularly troublesome, leading to nail deformities, discomfort, and secondary infections if left untreated. Cryotherapy, electrocautery, intralesional para-phenylenediamine (PPD), intralesional candida antigen, topical salicylic acid, imiquimod, and laser are examples of conventional procedures that can be done for periungual warts.² These warts are notoriously resistant to above said conventional treatments, largely due to factors such as poor patient compliance, limited penetration of topical medications due to a thick keratin layer, and frequent rubbing off of topical treatment due to trauma or repeated contact. Due to these challenges, many patients experience suboptimal outcomes in the treatment of periungual warts. Patients often become discouraged when treatments do not produce an immediate or complete resolution, resulting in discontinuation or inconsistent use of therapies, leading to frustration for both patients and healthcare providers.

RECOMMENDED SOLUTION

To solve this problem, we propose to use a condom/finger cot as an occlusive covering to enhance penetration and increase efficacy in such cases. For this, the patient is first asked to soak the affected area in lukewarm water to hydrate and soften the keratin, and the lesion is gently scrubbed and dried. Wart paint (a combination of salicylic acid and lactic acid) is then applied. Following this, a finger cot or condom, depending on the girth of the digit involved, is placed over the treated digit for 30 min [Figure 2]. The occlusive nature of the finger cot/condom increases moisture retention and creates a sealed environment, which facilitates better drug absorption through the thick keratin layer. This method was very effective for periungual warts as the finger cot/condom could be comfortably worn over the affected area without causing discomfort. We applied this methodology to multiple cases of periungual warts and found it to be both useful and

This is an open-access article distributed under the terms of the Creative Commons Attribution-Non Commercial-Share Alike 4.0 License, which allows others to remix, transform, and build upon the work non-commercially, as long as the author is credited and the new creations are licensed under the identical terms.

©2025 Published by Scientific Scholar on behalf of Journal of Cutaneous and Aesthetic Surgery

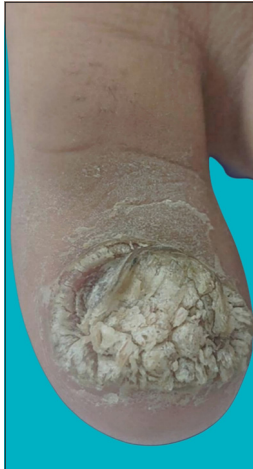

Figure 1: Verrucous lesion on the big toe.

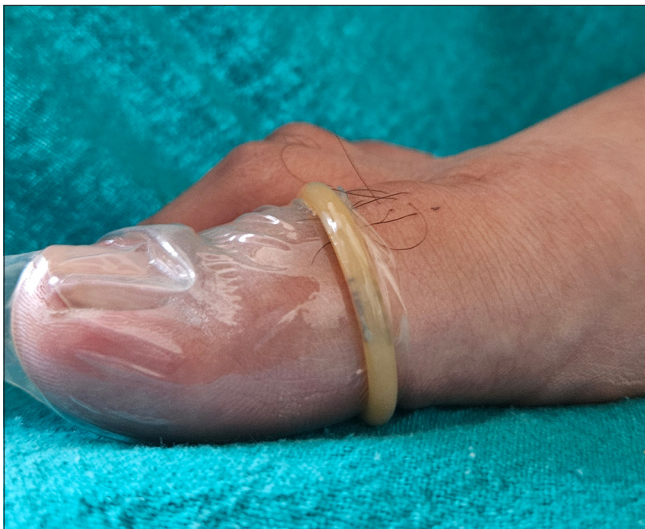

Figure 2: Condom worn over the big toe.

beneficial in promoting the resolution of warts [Figure 3]. This simple, easily available, and cost-effective technique may be a milestone in the treatment of periungual warts. The said case [Figures 1-3] was treated in 6 weeks of topical application under occlusion with a condom.

Authors' contributions: All authors have made equal and significant contributions to the diagnosis, case workup, literature review, writing, and editing of the manuscript.

Ethical approval: Institutional Review Board approval is not required.

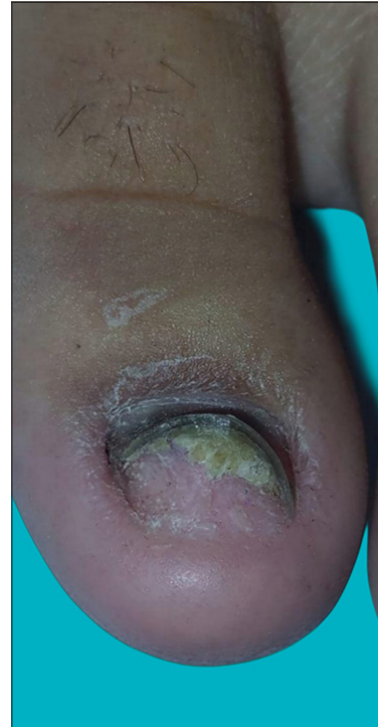


Figure 3: Complete clearance of lesion after topical application of wart paint and occlusion with Condom.

Declaration of patient consent: The authors certify that they have obtained appropriate patient consent for the images and clinical information presented in this article.

Financial support and sponsorship: Nil.

Conflicts of interest: There are no conflicts of interest.

Use of artificial intelligence (AI)-assisted technology for manuscript preparation: The authors confirm that there was no use of artificial intelligence (AI)-assisted technology for assisting in the writing or editing of the manuscript and no images were manipulated using AI.

REFERENCES

1. Tosti A, Piraccini BM. Warts of the nail unit: Surgical and nonsurgical approaches. *Dermatol Surg* 2001;27:235-9.
2. Kruter L, Saggar V, Akhavan A, Patel P, Umanoff N, Viola KV, et al. Intralesional bleomycin for warts: Patient satisfaction and treatment outcomes. *J Cutan Aesthet Surg* 2015;19:470-6.

How to cite this article: Gupta S, Jangra RS, Dabhra A, Gupta N. Seal and heal: A novel deal for periungual wart. *J Cutan Aesthet Surg*. doi: 10.25259/JCAS_105_2024