

Simplifying Injectables for Volumetric Rejuvenation of Face

Shehnaz Zulfikar Arsiwala

Renewderm Skin Hair Laser Aesthetics Centre, Mumbai, Maharashtra, India

Abstract

Volumetric rejuvenation with fillers is a minimally invasive technique used for facial volume restoration. Volume restoration demands adequate knowledge of fat pads and vascularity of the face and the understanding of the depletion patterns. Volumetric restoration with injectable has witnessed a paradigm shift in the last decade with a global rejuvenation, acquiring a predominant emphasis over focal wrinkle filling to restore the depletion pattern of facial fat layers. The techniques used to achieve optimal restoration of facial volume revolve around zonal lifting and tenting, and the impact of treatment on one zone of the surrounding zones is crucial. A face mapping performed for filler technique has thus evolved, with many experts advocating varied techniques from global restoration to point lifts at key areas, to improve the outcome of filler injections, albeit safely, thus simplifying the process. A systematic approach to various techniques and the point lifts in various zones pertaining to the face structure in the Indian skin are highlighted in this article.

Keywords: Injection techniques, point lifts, volume restoration

INTRODUCTION

Volumetric rejuvenation is defined as the method of restoring depletion in an aging skin by the usage of fillers injected into various depths of the skin from mid-dermis to subperiosteum, thus achieving facial harmony.

Volumetric rejuvenation with its newer dynamics and molecules has replaced surgical methods of face-lift largely because of its minimally invasive technique, predicable yet reversible results, and larger safety approaches available.

Volumetric restoration with injectable has witnessed a paradigm shift in the last decade with a global rejuvenation, acquiring a predominant emphasis over focal wrinkle filling, to restore the depletion pattern of facial fat layers. A face mapping performed for filler technique has thus evolved, with many experts advocating varied techniques from global restoration to point lifts at key areas, to improve the outcome of filler injections, albeit safely, thus simplifying the process.

Aging changes

Depletion in fat compartments, resorption of bone, and loss of skin elasticity as well as thickness define age-related changes, which along with the loss of muscle tone leads to sagging.^[1-3]

Volumetric restoration should precede the enhancement of an aging face. Bone resorption in aging reflects as changes in the skeleton, mostly in the orbital, periorbital, malar, submalar, and mandibular areas.^[4,5]

Racial variation and diversity in the features and anatomy have gained emphasis because of structural skeletal differences. The Indian faces have comparatively smaller bones, wide malar angles and mandibles, rounded and high cheeks, and heavier lower faces with descent downward and medial while aging, which are accentuated by the already short lower one-third and middle one-third of the face in the Indian skin. The periorbital area ages fastest in the Indian skin, reflecting prominent tear trough by mid-20s to 30s, thus defying the Greco-Roman standards of facial proportions.^[3,6]

Respecting the Indian anatomy that is characterized by small bones and more fat pads on the face and their subsequent depletion, one has to use techniques to restore and enhance in step with patient-derived desires of beauty,

Address for correspondence: Dr. Shehnaz Zulfikar Arsiwala,
Renewderm Skin Hair Laser Aesthetics Centre,
Nesbit Road, Mazgaon, Mumbai,
Maharashtra 400010, India.
E-mail: drshenaz@gmail.com

Access this article online

Quick Response Code:



Website:
www.jcasonline.com

DOI:
10.4103/JCAS.JCAS_67_18

This is an open access journal, and articles are distributed under the terms of the Creative Commons Attribution-NonCommercial-ShareAlike 4.0 License, which allows others to remix, tweak, and build upon the work non-commercially, as long as appropriate credit is given and the new creations are licensed under the identical terms.

For reprints contact: reprints@medknow.com

How to cite this article: Arsiwala SZ. Simplifying injectables for volumetric rejuvenation of face. J Cutan Aesthet Surg 2018;11: 51-9.

ensuring that there is no crowding of volume anteriorly to make the face heavier centrally [Figure 1].

Facial fat compartments

A cadaveric study showed that the subcutaneous facial fat is highly compartmentalized, and not only a change in volume but also a change in the position of these compartments with age is observed.^[1-3]

A few important aspects that need to be considered while understanding the depletion patterns of facial fat have led to important insights, which are as follows^[7-9]:

- Facial subcutaneous fat is compartmental—superficial and deep layers [Figure 2A and B]
- Each compartment is independent, and its depletion is not en masse
- Contour changes with individual compartment depletion reflect variable expression of age, which changes from person to person
- Ligaments confine fat areas. Retaining ligaments anchor and stabilize the skin and facial fascia. Lateral

laxity of ligaments is predominant than the central because of strong fixation points

- Surface anatomy reflects grooves because of volume depletion and ligament fixation

The fat pad depletion pattern makes the single crucial evaluation point needed for volumetric restoration. This emphasizes the aging curve for a particular patient and leads to predictive filler outcomes, if properly analyzed. The deep plane of fat in supraperiosteal layer is the first to deflate in orbital zone laterally and medially; medial cheek and chin fat is subsequently lost.^[4,8] Superficial pad fat compartment shows more lateral, temporal, and preauricular fat loss than that of the middle and medial cheeks.^[3,8,10,11] The nasolabial and jowl fold accentuation is more because of the loss of ligament strength than the fat loss, which happens much later^[8] [Diagram 1]. The pattern of fat loss is thus predictable, and the volume restoration should follow the pattern of fat depletion.

Retaining ligaments reflect grooves and confine fat loss to compartments and not en masse^[12] [Figure 3].

Patient assessment

Patient evaluation constitutes the key steps carried out before restoring volume with fillers. A face map needs to

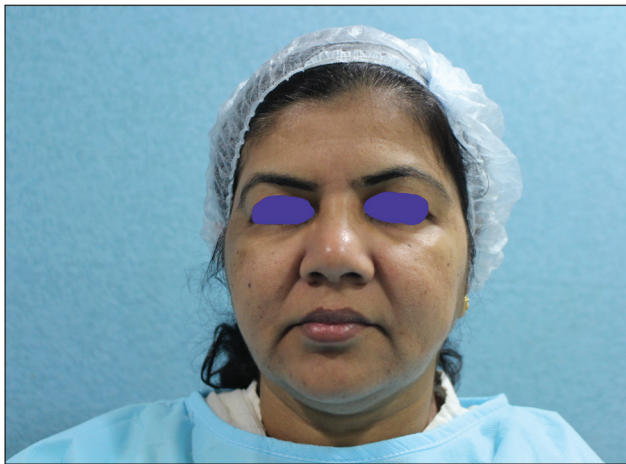

Figure 1: Indian face

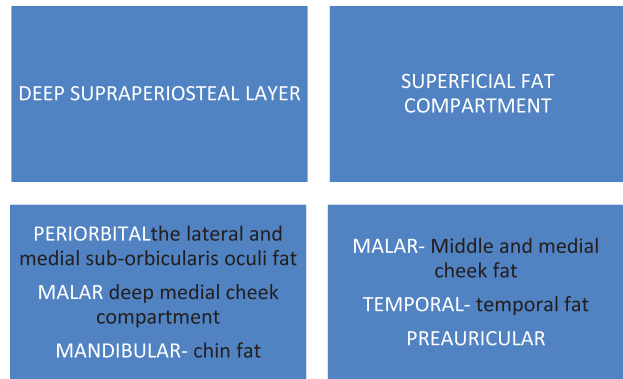


Diagram 1: Pattern of fat depletion

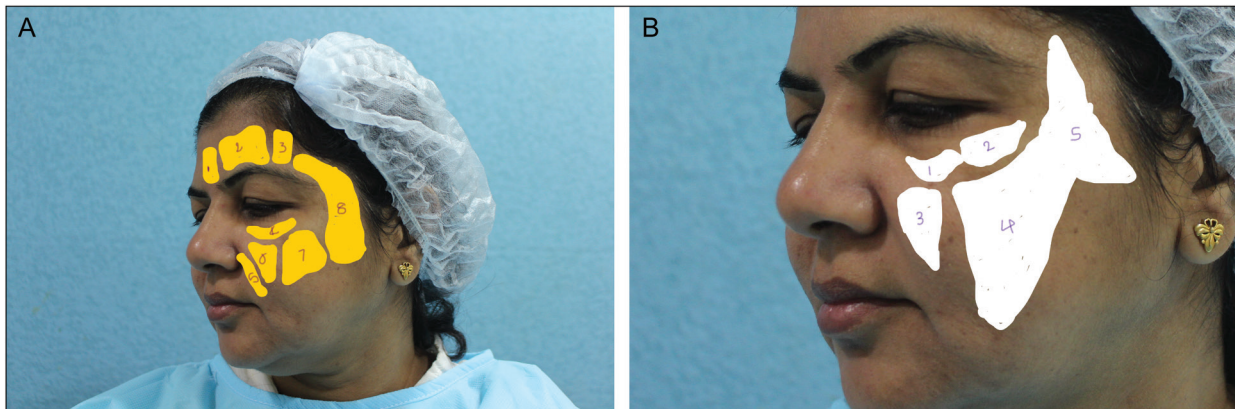


Figure 2: (A) Superficial pads of fat on the face. 1 = central fat compartments, 2 = medial fat compartments, 3 = lateral fat compartments, 4 = infraorbital compartments, 5 = nasolabial compartments, 6 = medial compartment of the cheek, 7 = middle cheek compartment, 8 = lateral compartment of temple and cheek. (B) Deep pads of fat on the face. 1 = medial sub orbicularis oculi fat, 2 = lateral sub orbicularis oculi fat, 3 = deep medial cheek fat, 4 & 5 = buccal pad of fat

be generated, incorporating physician and patient goals with a realistic consideration. The assessment includes consideration of age, race, gender, medical history, previous treatments, and so on. One must consider medical history, especially psychiatric illnesses, allergies, diabetes, hypertension, blood thinners and antiviral medications, history of cancer and hypertrophic scars or keloids potential, and so on, before conducting a filler rejuvenation. Previous injections used and their duration are of utmost importance; the previous need for hyaluronidase, usage of toxins, energy-based devices, and lasers are very important factors considered before conducting a filler treatment.

The patient's desire to improve a fold/line should be considered if realistic, and a restoration plan to alleviate the problem should be scientifically and logistically considered, for example, if prominent nasolabial fold is a concern for the patient, a physician has to work on the midface area at cheek, and the submalar area helps to efface the nasolabial fold. Understanding the vectors is important, and the patient has to be counseled for the same.

A physical examination is mandatory, especially to check for filler or toxin effects, preexisting brow ptosis, asymmetry, and so on.

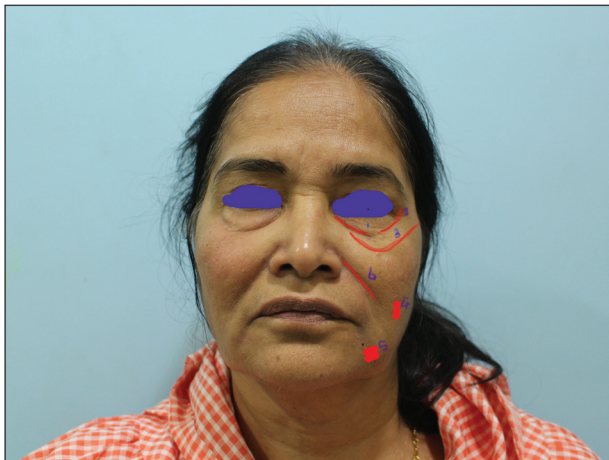

Figure 3: Retaining ligaments of face. 1 = tear trough ligament, 2 = orbital-retaining ligament, 3 = zygomatic cutaneous ligament, 4 = masseteric cutaneous ligaments, 5 = mandibular cutaneous ligaments, 6 = nasolabial ligament

Racial variations in the anatomic features and landmarks make for different techniques in the volumetric restoration, keeping in mind the requirements and trends for rejuvenation. Important topographical landmarks that help one in defining the safe implementation of filler injections are available.

Recent trends and techniques revolve around the deposition of the filler supraperiosteally, which is associated with safety. Swift and Remington^[13] have proposed the following anatomical bony landmarks that need to be identified [Figure 4]:

- Orbital rim
- Temporal crest
- Supra- and infraorbital notch
- Inferior maxillary border
- Zygomatic arch
- Pyriform fossa, gonial angle
- Medial and lateral limbus (parallel line from the edge of the cornea, where it joins the sclera, medially and laterally) constitutes the soft tissue landmarks with anterior border of masseter that makes the muscle landmark

The gender differences for male and female faces are considered before injections^[14,15] [Table 1].

The action of light and shadow on the face helps one to assess and rejuvenate. Observation commands assessing the aging face by viewing the deflation of volume,

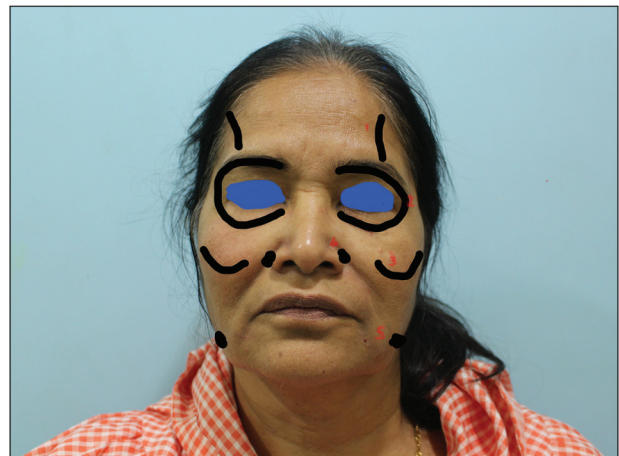

Figure 4: Anatomical landmarks. 1 = temporal crest, 2 = orbital rim, 3 = pyriform fossa, 4 = inferior maxillary border, 5 = gonial angle

Table 1: Aesthetic difference in male and female face

Male face	Female face
Anatomic variation: Thicker skin, more elastic and vascular, more solid bone structure, loss with age, fat depletion is same	Thinner skin, more elastoses, less vascular, less bone than men, loss with age, more bone loss after menopause, fat depletion on face is same
Anatomical features: muscular forehead, eyebrows horizontal, no arch, broad nose, square-shaped jawline, broad and wide mouth, thinner lips, flat cheeks	Anatomical features reference: arched brow, small sharp nose, forehead smooth, wide open-eyed look, high cheek bones, oval- or V-shaped jawline, full lips
Technique variation: avoid cheek augmentation and ogee curve injection	To enhance cheek, ogee curve's lateral and superior point to be injected
Practical consideration: feminization of male face to be avoided	Lateral cheek injections, enhance cheek mound and feminize the face

observing the deterioration of soft tissue, and analyzing the descent of soft tissue as a result of deflation and disproportion with dynamic discord of muscle action before injecting.^[13]

Vascular landmarks should be considered while conducting facial filler treatment. The potentially most serious side effect of a filler injection is vascular occlusion. Sheer vigilance and sound technique enable safer injection. The knowledge of key vessel pathway on the face is essential to practice safe injections. Important anatomic landmarks that help one to track the pathway of blood vessels are crucial [Figure 5].

The following arteries in the zones below have an important bearing while conducting a filler injection:

Glabella: Supratrochlear and supraorbital arteries. Injecting filler in this zone should be avoided, or the injection should be superficial.

Infraorbital: While injecting malar zone, one must stay lateral to infraorbital foramen to avoid the infraorbital vessels.

Nasolabial fold: Angular branch of facial artery/lateral nasal artery. In the lower part of nasolabial fold it is important to stay superficial while injecting and in upper 1/3 of the fold deep or periosteal injections are safest.

Nasal tip: Angular artery. Vessels here are superficial, while injecting on the nasal tip, it is best to carry out on the bone or cartilage to avoid the lateral nasal artery.

Temple: Temporal artery connected to internal carotid system and central retinal artery.

Lips: Labial artery—superior and inferior branch. In lips, injections should be less than 3-mm deep, subcutaneous at commissures.

The potential risk zones for vascular complications with fillers are identified as the nasolabial folds, where the

angular artery or lateral nasal artery can be occluded, the alar groove and nasal tip that have less subcutaneous tissue may reflect pressure occlusion from filler material. The glabellar region has arteries with smaller caliber and is a watershed area with minimal collateral circulation.^[16,17]

In the temporal fossa, the temporal artery traverses the temporoparietal fascia, and it may be blocked during an inadvertent injection. Thus, the injections at temple should be in the superficial, subcutaneous plane or bone deep.^[18,19]

Depth of injection

The injections can be placed superficial to bone deep, and this depends on the volume loss and fat pad depletion as well as anatomic landmark in that particular area. General rule depends on the amount of volumetric lift required as well as the presence of vascular structures in that area. The approach to filler treatment simplifies when the physician is aware of the depth of placement of the filling agent [Table 2].

Needles versus cannulas

Usage of a needle or cannula depends on the depth of the filler injection and vascular network in the area. The cannulas are generally considered nontraumatic and safer, but not always. The cannulas may be large bore or small bore and flexible or rigid [Table 2]. Large bore canulas are used for large size particle fillers and smaller ones for cohesive gel fillers. The choice of needle or cannula is largely injector dependent [Table 3].

Cheek augmentation, nose reshaping, and tear troughs can be carried out with rigid cannulas, whereas the areas that need manoeuvring, such as lips, nasolabial folds, and Marionette lines, can be treated with flexible cannulas.

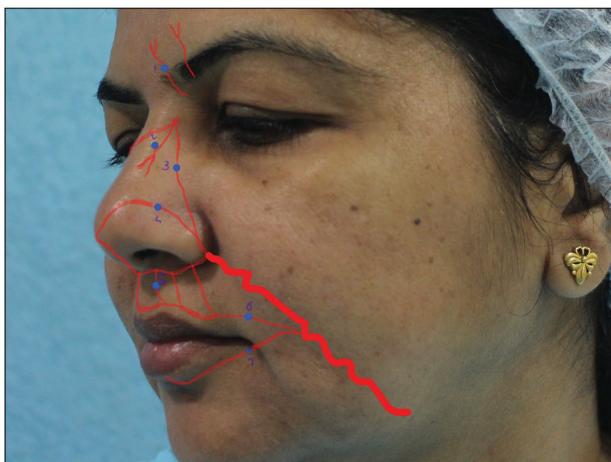


Figure 5: Course and important branches of facial artery. 1 = supratrochlear artery, 2 = dorsal nasal artery, 3 = angular artery, 4 = lateral nasal artery, 5 = columellar branch, 6 = superior labial artery, 7 = inferior labial artery

Table 2: Depth of filler placement at different sites

Site for filler injection	Depth of placement	Needle or cannula
Forehead	Bone	Needle
Temple	Bone	Needle
Eyebrow	Bone: ROOF#	Needle
Cheek	Bone, deep subcutaneous	Needle
Tear trough	Inferior orbital rim: bone	Needle
	Deep dermis	Cannula
Medial malar	Deep dermis	Cannula/needle with caution
Pyramidal fossa	Bone	Needle
Nasolabial	Deep dermis	Cannula/needle
Gonial angle	Bone	Needle
Jawline: pre-jowl	Deep dermis/ subcutaneous	Cannula
Lower lateral cheek	Dermal: superficial	Cannula
Chin	Bone/deep dermis/ subcutaneous	Needle/cannula

#Retro-orbicularis oculi fat

Table 3: Cannula specifications for different zones

Orbital zone	25	40 mm cannula	0.1–0.3 mL on each side, small aliquots	2–3 Points supraperiosteal
Deep malar	29 or 27 Gauge 21–23 Gauge cannula for large-sized fillers	25 mm long	0.1–0.2 per bolus	Lateral to medial
Mandible and jawline	29 or 27 Gauge	25/40 mm cannula	0.3–0.4 mL	Lateral to medial
Chin	27	25 mm needle	0.3–0.5 mL	
Lateral malar	25 g	40 or 50 mm long cannula	0.2–0.4 mL	Inferior to superior

Filler techniques and sequence of injection

For the ease of assessment, the face is divided into three zones: the upper one-third from the hairline to the nasion of the glabella, the middle one-third from the glabella to the nasal tip, and the lower one-third from the subnasal columella unit to the chin [Figure 6].

For the upper one-third restoration, periorbital forehead, glabella, and temples are addressed; whereas for middle one-third—periorbital, cheeks, nasolabial folds, and preauricular; and for lower one-third—marionette, chin, jawline, and neck.

Techniques

After a full pre-treatment consultation and a decision for the appropriate filler is taken, A 30 gauge needle or a 27 gauge is chosen, if filler is large particle sized depending on gel hardness it maybe easy or difficult to inject. Key focus is to inject slowly and without pressure. The key focus is to inject slowly and without pressure.

Some syringes are prefilled with lidocaine; however, mostly for deeper and large volume injections, an infiltrative anesthesia as field block injections may be advocated. Talkesthesia may work for small area treatments in compliant patients. Upright/slight semi-tilt posture with head rest is good to minimize the effects of gravity.

Injection techniques include linear threading, serial puncture and fanning, and bolus injections. Although serial puncture is most commonly used for injections, retrograde linear threading is the most appropriate. Serial puncture may be used on forehead and eyelids and linear threading in nasolabial and mentolabial folds or during crosshatching. Bolus injections are used for cheek, chin, temple, and point lifts, while treating submalar area or pyriform fossa in the nasolabial folds. Fractional microdepot is another technique, which is used where large bolus needs to be avoided and generally carried out in the periorbital zone.^[20,21]

Point lifts

The position and sequence of the small bolus injections in certain sites will anchor and bring support to the face. By injecting in a pattern in sequence, the volume of product used can be minimized, and still achieve maximum effect. Point lifts in filler techniques are more often used because of the various advantages as follows:

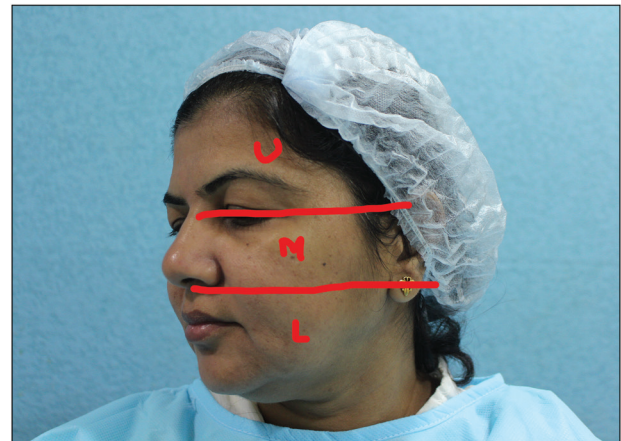


Figure 6: Three zones on the face. U = upper, M = middle, L = lower face

- Specific and focal injection points
- Small volume, graded buildup, long-term work
- Deep or supraperiosteal filling with more longevity
- More economical
- Point lift injections are generally conducted always with sharp needles and not cannulas, are always bolus single or multiple, large or small, and are placed largely supraperiosteal or deep dermal
- Point lift sequence of injections [Figure 7]: Deep restoration is first followed by superficial placements. The depth of injection placement is thus relocated from superficial to deeper planes. This builds deep support to the overlying structures and achieves volume repletion of subcutaneous fat compartments. This technique is used with respect to the Indian faces and their aging reflections to achieve a pattern of repletion with fillers using less volume, high G prime, and strategic placements of lateral to medial, superior to inferior, and deep to superficial to create liquid lift

When evaluating the areas to inject, creating structure and volume in one area of the face may lead to improvement in another, adjacent part.

Deep infraorbital injections that are used in injecting the infraorbital zone efface medial tear trough and nasojuugal fold, creating a seamless lid cheek junction. Deep orbital plane is injected, as deep and supraperiosteal. Points chosen are lateral and middle and central infraorbitals [Figures 8-10].

The orbital-retaining ligament and the thin nature of orbicularis oculi fibers should be kept in mind while working in this zone. Superficial placements may generate Tyndall effect.

DEEP LATERAL MALAR RESTORATION

The aging midface is highlighted by the loss of cheek projection and roundedness because of hypotrophy,

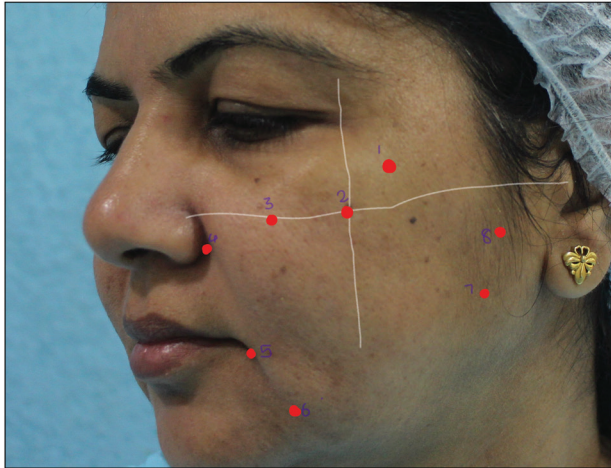


Figure 7: Sites of injection for point lifts. 1-8 = injection points for point lift

sagging, and accentuation of the nasolabial folds owing to pseudoptosis of the skin and lateral nasojuugal fold. This is often the first restoration that a physician prefers to achieve. Malar zone restoration has an impact of restoration in the same zone and a lift in the surrounding zones^[8,13] [Diagram 2]. This point is also called as “ogee curve” as coined by Swift and Remington^[13] and is a crucial point for cheek enhancement in women, and the impact of this restoration is immediate because of the reflection and projection of light from cheek counter for point lifts [Figure 7].

DEEP MALAR MEDIAL ZONE

Impact of fillers on malar zone on surrounding areas [Diagram 3]. The deep medial malar area restoration has a great impact on the midface and also lateral tear trough as well as the upper half of the nasolabial fold^[8] [Figures 11 and 12].

In the deep malar plane, treating laterally first and medially next impacts volume restoration on the lateral tear trough and the upper nasolabial fold. A deep support is created over the bone to support and lift the malar area.^[8] The lateral-to-medial sequence of injection helps in achieving a tenting effect so that less material is needed in the more medial compartment. This enables

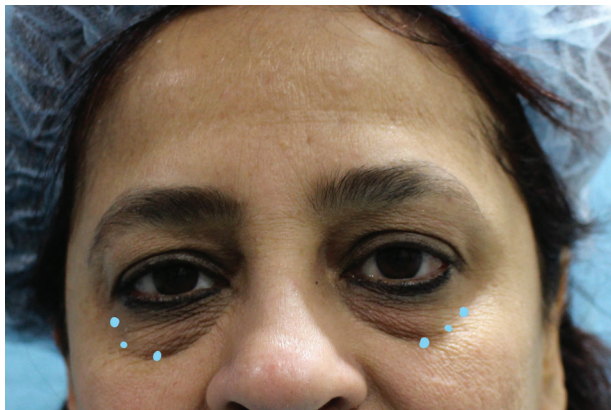


Figure 8: Points for infraorbital restoration

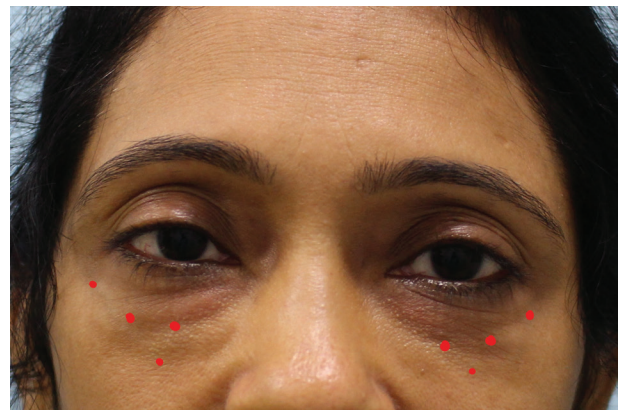


Figure 9: Points for periorbital and middle malar restoration

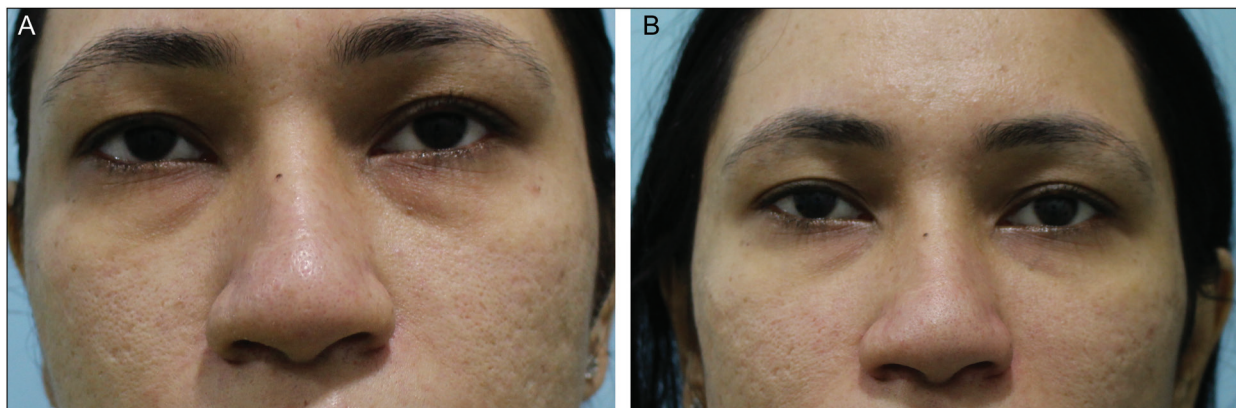


Figure 10: (A) Before periorbital and malar restoration. (B) After periorbital and malar restoration with fillers

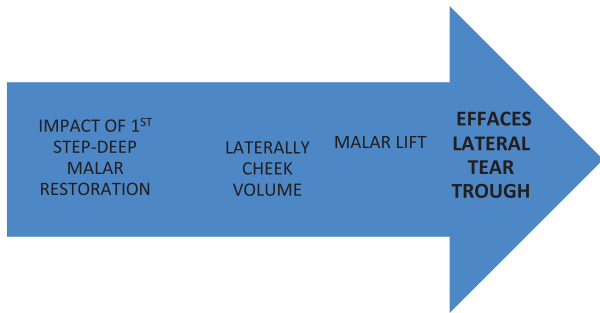


Diagram 2: Deep lateral cheek restoration

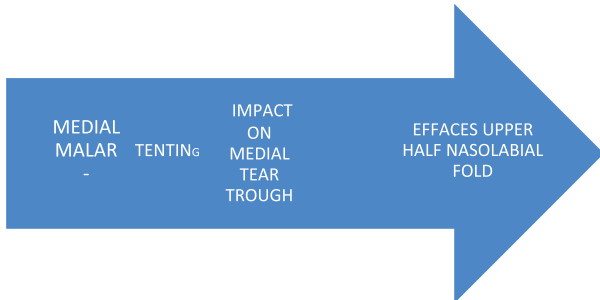


Diagram 3: Impact of treatment of medial malar zone with fillers

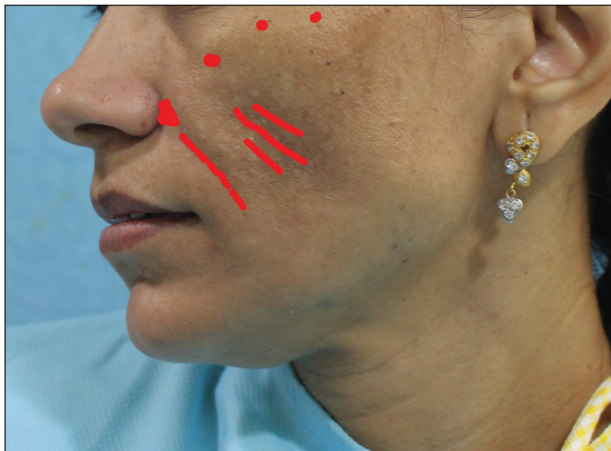

Figure 11: Points for midface and submalar restoration

enhancement of mid cheek and also anterior projection. Treatment of the cheekbones with volume may improve the appearance of the nasolabial fold and shorten the lid–cheek junction.^[8,22-24]

- Through understanding this rationale, the treatment of the jawline, pre-jowl sulcus, and Marionette lines should start in the upper midface along the zygomatic arch and cheekbones.

The mandibular zone rejuvenation includes treating around the mouth, chin, and jawline to create a harmony in the lower face unit. The volumetric rejuvenation in this zone has a great impact in restoring youthfulness [Diagram 4 and Figure 13A and B].

Superficial, subcutaneous layer is mostly important in the lateral compartments. The treatment includes temporal and preauricular placements.^[8] The impact of treating subcutaneous plane is highlighted in Diagram 5.

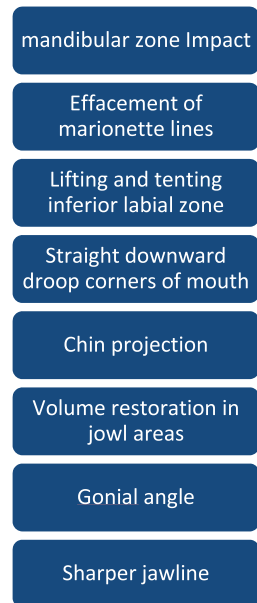


Diagram 4: Impact of volume restoration in mandibular zone

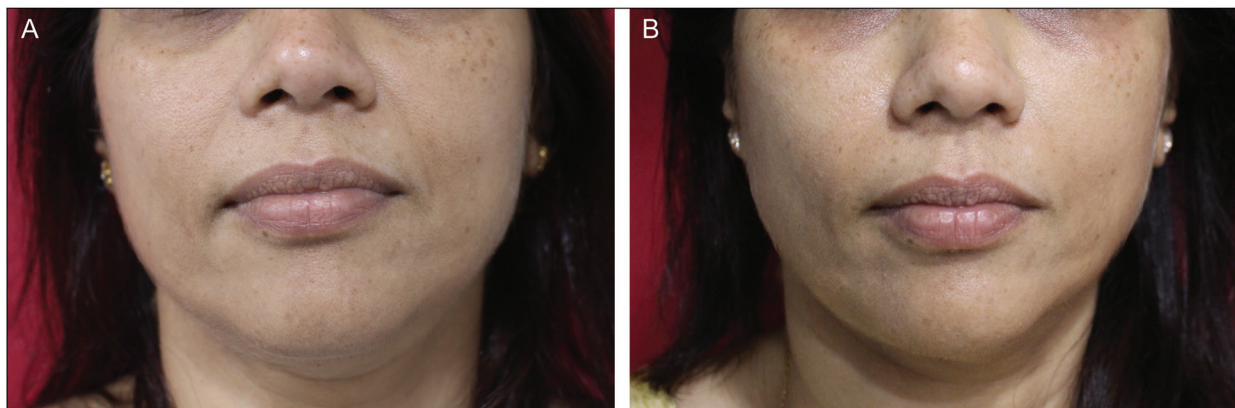


Figure 12: (A) Before midface and submalar restoration. (B) After midface and submalar restoration with fillers

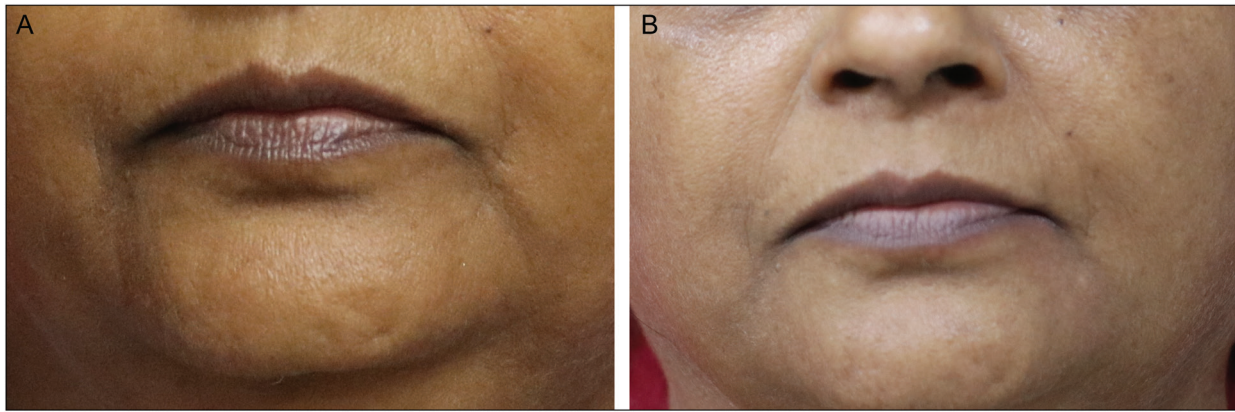


Figure 13: (A) Marionette lines. (B) Marionette lines after volumetric restoration

Oval face contour

convex contour between the temporal fusion line and thezygomatic arch

Prevents rat face and excess anterior projection

In a lean face impact on middle part of NL fold

Diagram 5: Impact of superficial subcutaneous volume restoration. NL = nasolabial fold

Tips for simplifying fillers are as follows:

- Injecting the deep plane is sufficient to have good results in terms of natural volume and projection of tissues, whereas the superficial plane allows for more tightening than volume
- Moderate placements to prevent heavily done face
- Injecting along the superficial compartment boundaries carries more risk of vascular damage, deep placements, and less vascular risks
- Layered point filling enables adequate restoration with less material
- Microinjections are a mainstay to achieve hydration and luminosity

SAFETY CONCERNS WHILE INJECTING

Safety is a key priority for achieving volumetric rejuvenation with injectable. A variety of mild-to-severe reactions can be encountered while treating with fillers, which range from bruising, swelling, infections, Tyndall effect, lumpiness to vascular occlusion, and even blindness.^[25-29] We follow a protocol as below to achieve safety:

- Aspiration
- Slow injections

- Graded pressure on plunger
- Cannula in heavily vascularized zones
- Supra- or subperiosteal when needle is used
- Observation for blanching/undue pain
- Caution for complications

CONCLUSION

Sound knowledge is essential with respect to aging changes on the face at various levels of fat compartments, teamed with a detailed assessment helps physician to choose the right patient for filler injections. The factors such as filler rheology, easy injections, longevity, and cross-linkage help to choose an appropriate filler. Precise injection techniques and safe methods enable the physician to achieve best outcomes with least side effects, and the process is simplified when perfect execution of all the above factors is conducted.

Declaration of patient consent

The authors certify that they have obtained all appropriate patient consent forms. In the form the patient(s) has/have given his/her/their consent for his/her/their images and other clinical information to be reported in the journal. The patients understand that their names and initials will not be published and due efforts will be made to conceal their identity, but anonymity cannot be guaranteed.

Financial support and sponsorship

Nil.

Conflicts of interest

There are no conflicts of interest.

REFERENCES

1. Fitzgerald R, Graivier MH, Kane M, Lorenc ZP, Vleggaar D, Werschler WP, *et al.* Update on facial aging. *Aesthet Surg J* 2010;30:11S-24S.
2. Vleggaar D, Fitzgerald R. Dermatological implications of skeletal aging: a focus on suprapariosteal volumization for perioral rejuvenation. *J Drugs Dermatol* 2008;7:209-20.

3. Rohrich RJ, Pessa JE. The fat compartments of the face: anatomy and clinical implications for cosmetic surgery. *Plast Reconstr Surg* 2007;119:2219-27; discussion 2228-31.
4. Shaw RB Jr., Kahn DM. Aging of the midface bony elements: a three-dimensional computed tomographic study. *Plast Reconstr Surg* 2007;119:675-81; discussion 682-3.
5. Mendelson B, Wong CH. Changes in the facial skeleton with aging: implications and clinical applications in facial rejuvenation. *Aesthetic Plast Surg* 2012;36:753-60.
6. Shetty R. Outer circle versus inner circle: special considerations while rejuvenating an Indian face using fillers. *J Cutan Aesthet Surg* 2015;8:169-72.
7. Casabona G. Dermatologist have now developed a 3 dimensional view of facial changes while aging. *Dermatol Surg* 2015;41:841-7.
8. Salti G, Rauso R. Facial rejuvenation with fillers: the dual plane technique. *J Cutan Aesthet Surg* 2015;8:127-33.
9. Arsiwala SZ. Current trends in facial rejuvenation with fillers. *J Cutan Aesthet Surg* 2015;8:125-6.
10. Russo PR, Fundarò PS. The invisible lifting. Florence, Italy: OEO; 2014. pp. 109-57.
11. Sandoval SE, Cox JA, Koshy JC, Hatef DA, Hollier LH. Facial fat compartments: a guide to filler placement. *Semin Plast Surg* 2009;23:283-7.
12. Ozdemir R, Kiliç H, Unlü RE, Uysal AC, Sensöz O, Baran CN. Anatomicohistologic study of the retaining ligaments of the face and use in face lift: retaining ligament correction and SMAS plication. *Plast Reconstr Surg* 2002;110:1134-47; discussion 1148-9.
13. Swift A, Remington K. Beautification™: a global approach to facial beauty. *Clin Plast Surg* 2011;38:347-77.
14. Tan SR, Glogau RG. Filler esthetics. In: Carruthers A, Carruthers J, editors. *Procedures in cosmetic dermatology series: soft tissue augmentation*. Philadelphia, PA: Saunders, 2005.
15. Leong PL. Aging changes in the male face. *Facial Plast Surg Clin N Am* 2008;16:277-9.
16. Glaich AS, Cohen JL, Goldberg LH. Injection necrosis of the glabella: protocol for prevention and treatment after use of dermal fillers. *Dermatol Surg* 2006;32:276-81.
17. Hirsch RJ, Cohen JL, Carruthers JD. Successful management of an unusual presentation of impending necrosis following a hyaluronic acid injection embolus and a proposed algorithm for management with hyaluronidase. *Dermatol Surg* 2007;33:357-60.
18. Glashofer MD, Flynn TC. Complications of temporary fillers. In: Carruthers J, Carruthers A, editors. *Soft tissue augmentation*. Toronto, Canada: Elsevier Saunders; 2013. pp. 179-87.
19. Kim DW, Yoon ES, Ji YH, Park SH, Lee BI, Dhong ES. Vascular complications of hyaluronic acid fillers and the role of hyaluronidase in management. *J Plast Reconstr Aesthet Surg* 2011;64:1590-5.
20. Monheit GD, Prather CL. Hyaluronic acid fillers for the male patient. *Dermatol Ther* 2007;20:394-406.
21. Lim AC, Lowe PM. Fractional filling with the microdepot technique as an alternative to bolus hyaluronic acid injections in facial volume restoration. *Australas J Dermatol* 2011;52:154-6.
22. Raspaldo H. Volumizing effect of a new hyaluronic acid sub-dermal facial filler: a retrospective analysis based on 102 cases. *J Cosmet Laser Ther* 2008;10:134-42.
23. Haddock NT, Saadeh PB, Boutros S, Thorne CH. The tear trough and lid/cheek junction: anatomy and implications for surgical correction. *Plast Reconstr Surg* 2009;123:1332-40; discussion 1341-2.
24. Rohrich RJ, Pessa JE, Ristow B. The youthful cheek and the deep medial fat compartment. *Plast Reconstr Surg* 2008;121:2107-12.
25. Haneke E. Managing complications of fillers: rare and not-so-rare. *J Cutan Aesthet Surg* 2015;8:198-210.
26. Carle MV, Roe R, Novack R, Boyer DS. Cosmetic facial fillers and severe vision loss. *JAMA Ophthalmol* 2014;132:637-9.
27. Shahrabi-Farahani S, Lerman MA, Noonan V, Kabani S, Woo SB. Granulomatous foreign body reaction to dermal cosmetic fillers with intraoral migration. *Oral Surg Oral Med Oral Pathol Oral Radiol* 2014;117:105-10.
28. Funt DK. Avoiding malar edema during midface/cheek augmentation with dermal fillers. *J Clin Aesthet Dermatol* 2011;4:32-6.
29. Rodrigues-Barata AR, Camacho-Martínez FM. Undesirable effects after treatment with dermal fillers. *J Drugs Dermatol* 2013;12:e59-62.