

Mondor's Disease after Aesthetic Breast Surgery: A Case Series and Literature Review

Alberto Goldman, Uwe Wollina¹

Clinica Goldman and Hospital Moinhos de Vento, Porto Alegre, Rio Grande do Sul, Brazil, ¹Department of Dermatology and Allergology, Städtisches Klinikum Dresden, Academic Teaching Hospital of the Technical University of Dresden, Dresden, Germany

Abstract

Background: Mondor's disease of the subcutaneous veins of the breast is an uncommon disorder. The etiology of Mondor's disease remains unclear. Usually, it is a self-limited disease. This condition has been associated with trauma, surgical biopsies, breast surgery (including silicone breast implant), physical activity, and a manifestation of breast cancer. **Materials and Methods:** This is a retrospective analysis of 652 female patients who underwent aesthetic breast surgery in the last 10 years. **Results:** We found three cases of Mondor's disease after plastic surgery of the breast (0.46%) and performed an analysis of the clinical aspects and therapeutic measures. The disease onset was a couple of weeks to 2 years after surgery, never within the first 2 weeks after surgery. We did not observe ulceration or breast cancer. Treatment was unnecessary in two patients, whereas hot compresses and nonsteroidal medical drugs were prescribed in one patient. All lesions healed within 2–3 weeks. **Conclusion:** Mondor's disease is a possible complication after aesthetic breast surgery but often runs a self-limiting course with spontaneous remission. It is important to exclude breast cancer. The patient should be informed that the disease runs a benign and self-limiting course.

Keywords: Mammoplasty, Mondor's disease, silicone implant, superficial thrombophlebitis

INTRODUCTION

Superficial vein thrombosis and thrombophlebitis were initially described by Mondor^[1] in 1939 in the subcutaneous veins of the anterolateral thoracoabdominal wall. Mondor's disease commonly affects the vessels of the lateral thoracic, thoracoepigastric, and superior epigastric veins. The involvement of upper arms, abdomen, groin, or penis is less common.^[2]

The concept of Mondor's disease has been further developed and now also includes subcutaneous thrombosis of the dorsal vein of the penis and retractile scarring of the fascia after breast surgery without concomitant superficial vein thrombosis.^[3]

The pathogenesis is not completely understood. The initial event may be a trauma, surgery, medical drug therapy, or hypercoagulability. The possible role of cancer has been debated as cancer can cause thrombotic events.^[4]

The sudden onset may scare patients. They may feel a strain or a painful induration under the skin, but the disease can

also be asymptomatic. One can see and palpate a cord-like induration of affected veins. Doppler ultrasound examination allows confirmation of the disease in the form of a superficially located, longitudinal, anechoic lesion such as rosary beads without blood flow.^[5]

In case of biopsy, immunohistochemical staining for CD31 and D240 is considered as reliable to distinguish small veins from lymphatic vessels. Differential diagnoses include (sclerosing) lymphangitis, lymphangiosis carcinomatosa, mastodynia, and penile fracture, depending on the affected sites.^[6]

Usually, Mondor's disease is a benign, self-limiting condition with spontaneous resolution. Nonsteroidal

Address for correspondence: Prof. Uwe Wollina,
Department of Dermatology and Allergology,
Städtisches Klinikum Dresden,
Academic Teaching Hospital of the Technical University of Dresden,
Friedrichstrasse 41, 01067 Dresden, Germany.
E-mail: wollina-uw@khdf.de

This is an open access journal, and articles are distributed under the terms of the Creative Commons Attribution-NonCommercial-ShareAlike 4.0 License, which allows others to remix, tweak, and build upon the work non-commercially, as long as appropriate credit is given and the new creations are licensed under the identical terms.

For reprints contact: reprints@medknow.com

How to cite this article: Goldman A, Wollina U. Mondor's disease after aesthetic breast surgery: A case series and literature review. *J Cutan Aesthet Surg* 2018;11:132-5.

Access this article online

Quick Response Code:



Website:
www.jcasonline.com

DOI:
10.4103/JCAS.JCAS_69_18

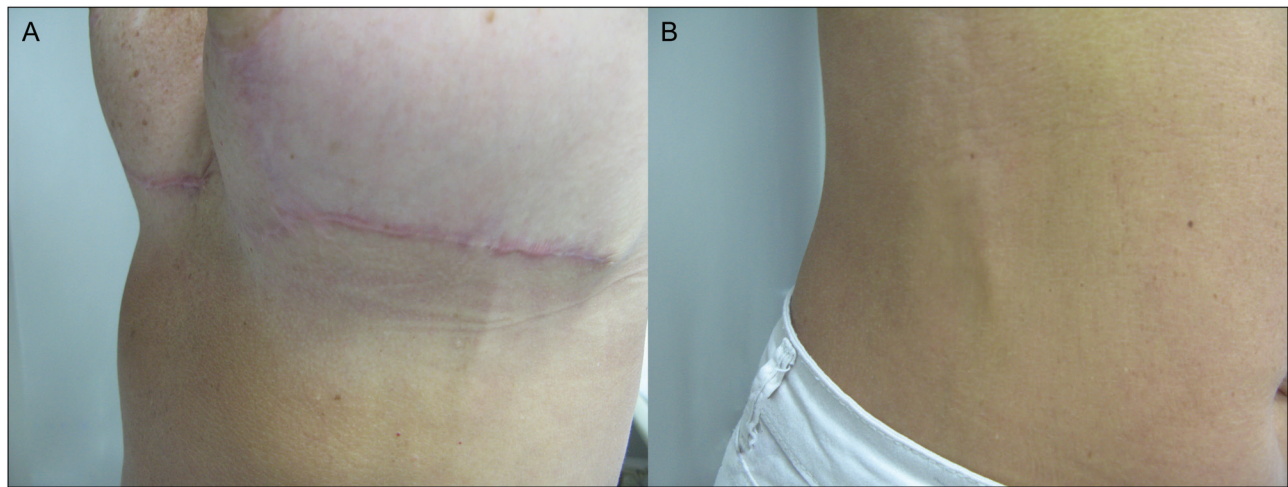


Figure 1: (A) Longitudinal fibrous strings after breast reduction. (B) The same patient with Mondor's disease of the abdominal wall

anti-inflammatory drugs, anticoagulation therapy, and even surgery have been used for its treatment as necessary.^[3,7] Successful triamcinolone injections have been reported recently.^[8]

CASE REPORTS

We report a retrospective analysis of 652 female patients who underwent aesthetic breast surgery within the last 10 years. Mondor's disease was confirmed by the Doppler ultrasound. Three cases aged 52, 34, and 38 years (0.46%) could be identified, who developed Mondor's disease after breast surgery. None of these patients had hypercoagulability, trauma (except surgery), or breast cancer.

Case report 1

A 52-year-old woman with breast ptosis and hypertrophy underwent bilateral breast reduction. The procedure was performed under general anesthesia. The postoperative period was entirely uneventful until 9 weeks later, when she presented with longitudinal fibrous strings in the lateral thoracic vessels (under the left breast) and also in the abdominal wall. No pain or other symptoms were reported. The clinical diagnosis was superficial thrombophlebitis (Mondor's disease) following breast surgery. The fibrous cord disappeared spontaneously 3 weeks later [Figure 1A and B].

Case report 2

A 34-year-old woman presented with Mondor's thrombophlebitis 2 years after augmentation mammoplasty. She did not report any problem after the surgery and remained asymptomatic for 2 years. She reported that after an exhaustive physical activity, a painful fibrous and hard cord tumor in the left side of the thoracoabdominal wall was observed. The physical examination showed a normal breast, without contracture and a good quality periareolar scar. Ultrasonography,

magnetic resonance imaging, and mammography were normal. The diagnosis was Mondor's disease. We prescribed warm compresses and nonsteroidal anti-inflammatory drugs. The symptoms disappeared in 2 weeks [Figure 2A and B].

Case report 3

A 38-year-old woman was admitted to obtain a bilateral retroglanular silicone breast implant via inframammary fold. The postoperative period was uneventful until the 3rd week. The patient observed a fibrous cord below the right breast without any other symptoms. The clinical diagnosis was thrombophlebitis of the subcutaneous vein as a symptom of Mondor's disease. The cord-like lesions disappeared 2 weeks later without any treatment [Figure 3].

DISCUSSION

Mondor's disease is a benign, self-limited vascular disease. Approximately 75% of the patients are women. The incidence of Mondor's disease among the female patients with breast disorders is between 0.5% and 0.8%.^[9]

Trauma to the breast can cause Mondor's disease. In the literature, ultrasound-guided core biopsy, mammotome biopsy, mastopexy with breast augmentation, breast reduction surgery, and tight bra, but also due to gigantomastia.^[10-18] It is important to exclude breast cancer in such cases.^[9,19,20]

In our case series of 652 women, breast surgery was the trigger for postoperative Mondor's disease in 0.46% of patients. The largest series has been reported from France with eight patients. The authors suggested that Mondor's disease is caused in this setting by fascial changes.^[21] An Italian group reported three cases after implant-based breast reconstruction in nonobese, nonsmoking patients without hypercoagulability of thrombotic risks.^[12] Another three cases have been reported after subfascial breast

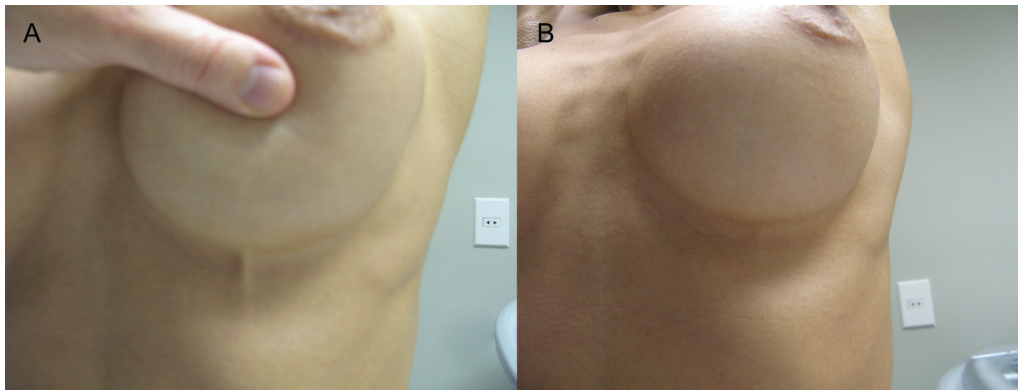


Figure 2: (A) Mondor's thrombophlebitis 2 years after augmentation mammoplasty. (B) The same patient 2 weeks after clinical treatment

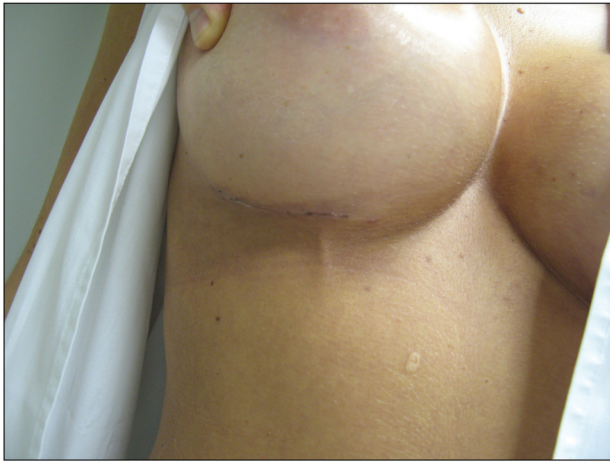

Figure 3: Mondor's disease presenting as a fibrous cord below the right breast 3 weeks after silicone breast implant

augmentation.^[13] We observed a delay of several weeks between surgery and the onset of symptoms. Sometimes the delay between surgery and Mondor's disease can be as long as 13 years.^[22] On the other hand, there is neither a close relationship between Mondor's disease and silicone breast implants nor between Mondor's disease and capsule contracture.^[23]

In two of our three patients, no treatment was warranted. The third patient was treated by nonsteroidal drugs and warm compresses. The lesions disappeared within 2–3 weeks without leaving any footprints. However, secondary ulcerations may rarely occur as a complication.^[24]

CONCLUSION

Mondor's disease is a rare but possible complication after aesthetic breast surgery. Although disconcerting for the patient, the disease is benign and self-limiting. Treatment is not always necessary, and in most of such cases, nonsteroidal anti-inflammatory drugs are the first choice.

Declaration of patient consent

The authors certify that they have obtained all appropriate patient consent forms. In the form the patient(s) has/have

given his/her/their consent for his/her/their images and other clinical information to be reported in the journal. The patients understand that their names and initials will not be published and due efforts will be made to conceal their identity, but anonymity cannot be guaranteed.

Financial support and sponsorship

Nil.

Conflicts of interest

There are no conflicts of interest.

REFERENCES

1. Mondor H. Tronculite sous-cutanee subaigue de la panoi thoracique antero-laterale. *Mem Acad Chir* 1939;65:1271-8.
2. Alvarez-Garrido H, Garrido-Ríos AA, Sanz-Muñoz C, Miranda-Romero A. Mondor's disease. *Clin Exp Dermatol* 2009;34:753-6.
3. Laroche JP, Galanaud J, Labau D, Van Kien AK, Brisot D, Boge G, *et al.* Mondor's disease: what's new since 1939? *Thromb Res* 2012;130:S56-8.
4. Shirah BH, Shirah HA, Alonazie WS. The effectiveness of diclofenac sodium in the treatment of Mondor's disease of the breast: the topical patch compared to the oral capsules. *Breast J* 2017;23:395-400.
5. Shah NA, Gryskiewicz J, Crutchfield CE 3rd. Successful treatment of a recalcitrant Mondor's cord following breast augmentation. *J Clin Aesthet Dermatol* 2014;7:50-1.
6. Salemis NS, Merkouris S, Kimpouri K. Mondor's disease of the breast. A retrospective review. *Breast Dis* 2011;33:103-7.
7. O'Neal JM, Castleberg E, Dinh VA. Diagnosis of Mondor's disease in the emergency department with bedside ultrasound. *Case Rep Emerg Med* 2015;2015:817960.
8. Alvarez-Garrido H, Sanz-Muñoz C, Pericet-Fernández L, Garrido-Ríos AA, Miranda-Romero A. Immunohistochemical clues to the diagnosis of Mondor's disease of the penis. *Clin Exp Dermatol* 2009;34:e663-5.
9. Pasta V, D'Orazi V, Sottile D, Del Vecchio L, Panunzi A, Urciuoli P. Breast Mondor's disease: diagnosis and management of six new cases of this underestimated pathology. *Phlebology* 2015;30:564-8.
10. Salemis NS, Vasilara G, Lagoudianakis E. Mondor's disease of the breast as a complication of ultrasound-guided core needle biopsy: management and review of the literature. *Breast Dis* 2015;35:73-6.
11. Kibil W, Hodorowicz-Zaniewska D, Kulig J. Mondor's disease in a patient after a mammotome biopsy. *Wideochir Inne Tech Maloinwazyjne* 2015;10:138-40.
12. Pignatti M, Loschi P, Pedrazzi P, Marietta M. Mondor's disease after implant-based breast reconstruction. Report of three

- cases and review of the literature. *J Plast Reconstr Aesthet Surg* 2014;67:e275-7.
13. Tijerina VN, Saenz RA. Mondor's syndrome: a clinical finding on subfascial breast augmentation. *Aesthetic Plast Surg* 2010;34:531-3.
 14. Marín-Bertolín S, González-Martínez R, Velasco-Pastor M, Gil-Mateo MD, Amorrortu-Velayos J. Mondor's disease and aesthetic breast surgery: report of case secondary to mastopexy with augmentation. *Aesthetic Plast Surg* 1995;19:251-2.
 15. Loos B, Horch RE. Mondor's disease after breast reduction surgery. *Plast Reconstr Surg* 2006;117:129e-32e.
 16. Thiery G, Liard O, Duboscq JC. [Mondor's disease: about two cases]. *Ann Chir Plast Esthet* 2005;50:251-4.
 17. Vincenza Polito M, De Cicco P, Apicella R. Tight bra in a 34-year-old woman: an unusual cause of Mondor's disease. *Ann Vasc Dis* 2014;7:149-51.
 18. Pasta V, Redler A, Giofrè M, Merola R, Monti M. Observations and considerations on a case of Mondor's syndrome associated with gigantomastia. *Ann Ital Chir* 2011;82:481-5.
 19. Catania S, Zurrida S, Veronesi P, Galimberti V, Bono A, Pluchinotta A. Mondor's disease and breast cancer. *Cancer* 1992;69:2267-70.
 20. Markopoulos C, Kouskos E, Mantas D, Kakisis J, Antonopoulou Z, Kontzoglou K, *et al.* Mondor's disease of the breast: is there any relation to breast cancer? *Eur J Gynaecol Oncol* 2005;26:213-4.
 21. Lhoest F, Grandjean FX, Heymans O. [Mondor's disease: a complication after breast surgery]. *Ann Chir Plast Esthet* 2005;50:197-201.
 22. Coscia J, Lance S, Wong M, Garcia J. Mondor's thrombophlebitis 13 years after breast augmentation. *Ann Plast Surg* 2012;68:336-7.
 23. Green RA, Dowden RV. Mondor's disease in plastic surgery patients. *Ann Plast Surg* 1988;20:231-5.
 24. Shousha S, Chun J. Ulcerated Mondor's disease of the breast. *Histopathology* 2008;52:395-6.