

Complications Associated With Medial Thigh Lift: A Comprehensive Literature Review

Andrea Sisti, Roberto Cuomo, Irene Zerini, Juri Tassinari, Cesare Brandi, Luca Grimaldi, Carlo D'Aniello, Giuseppe Nisi

Plastic Surgery Division, Department of General and Specialist Surgery, University of Siena, Siena, Italy

Address for correspondence: Dr. Andrea Sisti, Plastic Surgery Division, Department of General and Specialist Surgery, University of Siena, Siena, Italy.
E-mail: asisti6@gmail.com

ABSTRACT

Medial contouring of the thigh is frequently requested to improve appearance and function of medial thigh deformities, following massive weight loss or aging process. This surgical procedure can be associated with a significant rate of complications. Our aim was to consider the complications and outcomes according to the performed technique, through a wide and comprehensive review of the literature. A search on PubMed/Medline was performed using "medial thighplasty", "medial thigh lifting" and "technique" as key words. As inclusion criteria, we selected the clinical studies describing techniques of medial thighplasty. We excluded the papers in which complications related to medial thighplasty were not specified. We also excluded literature-review articles. We found 16 studies from 1988 to 2015. Overall, 447 patients were treated. Different techniques were applied. Complications were observed in 191/447 patients (42.72%). The most frequent complications were wound dehiscence (18.34%) and seroma (8.05%). No major complications, such as thromboembolism and sepsis, were observed. Minor complications occurred in a high percent of patients, regardless of the performed surgical procedure. Patients should be informed about the possible occurrence of wound dehiscence and seroma, as common complications associated with this surgical procedure.

KEYWORDS: Medial thigh lift, medial thighplasty, thigh rejuvenation, body contouring, complications

INTRODUCTION

Medial thighplasty is an intervention to reduce excess skin and fat in the medial part of the thighs. Because of the changes which occur with age and weight loss, the skin and subcutaneous tissue of the medial thigh region show relaxation and redundancy from the loss of tone and elasticity, with inevitable ptosis of the tissues^[1] [Figure 1]. The Pittsburgh Rating Scale^[2] is a validated measure of contour deformities after bariatric weight loss. In this study, the authors rated body areas most frequently demonstrating skin and soft-tissue laxity and ptosis (arms, breasts, abdomen, flank, mons, back, buttocks, medial thigh, hips/lateral thighs, and lower thighs/knees). A four-point grading system was

designed to describe the most common medial thigh deformities [Table 1]. For each rating, the indicated surgical procedures were outlined. This scale has applications in preoperative planning and evaluating surgical outcomes. When evaluating a patient for thigh rejuvenation, a critical assessment must be made of the quality, location, degree, and extent of skin excess. If the patient has a moderate to significant amount of fat in the medial thigh, the patient will require liposuction. If the skin quality is good and there is not a significant amount of skin excess, liposuction is performed

This is an open access article distributed under the terms of the Creative Commons Attribution-NonCommercial-ShareAlike 3.0 License, which allows others to remix, tweak, and build upon the work non-commercially, as long as the author is credited and the new creations are licensed under the identical terms.

For reprints contact: reprints@medknow.com

How to cite this article: Sisti A, Cuomo R, Zerini I, Tassinari J, Brandi C, Grimaldi L, *et al.* Complications associated with medial thigh lift: A comprehensive literature review. *J Cutan Aesthet Surg* 2015;8:191-7.

Access this article online

Quick Response Code:



Website:
www.jcasonline.com

DOI:
10.4103/0974-2077.172189

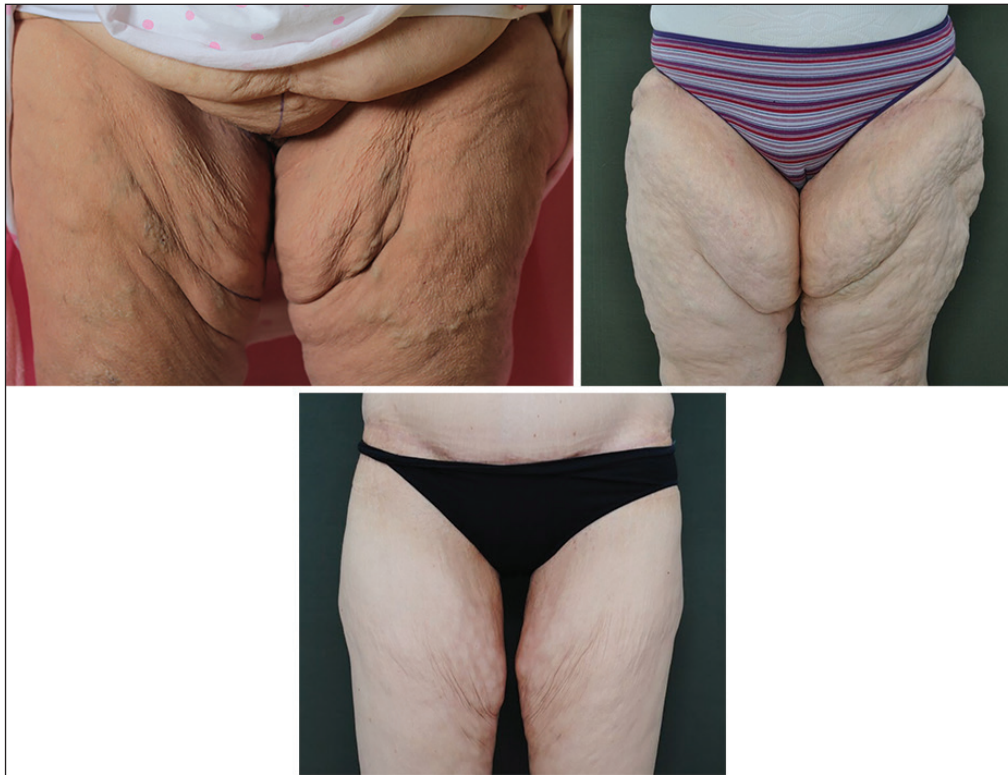

Figure 1: Typical skin-fat excess in the medial thigh

Table 1: Medial thigh deformities classification using the Pittsburgh Rating Scale

Scale		Preferred procedure
0	Normal	None
1	Excessive adiposity	Ultrasound-assisted and/or suction-assisted lipectomy ± excisional lifting procedure
2	Severe adiposity and/or severe cellulite	Ultrasound-assisted and/or suction-assisted lipectomy ± excisional lifting procedure
3	Skin folds	Excisional lifting procedure

without skin resection. When the skin quality prohibits liposuction alone, liposuction is initially performed followed by excisional surgery after a minimum of 6 months.^[3] Medial thighplasty represents one of the most commonly performed plastic surgical procedures. The very first description of thigh lift for aesthetic purpose dates back to 1957.^[4] Today, its popularity is growing. During the last few years, there has been a significant increase in the number of patients who undergo this surgery because of redundant skin due to prior bariatric surgery.

Unfortunately, this type of surgery can lead to a high percentage of postoperative complications [Figure 2]. The most frequent complications are scar migration, wound dehiscence, scar infection, hematoma, lymphedema, and gaping vulva.^[5-7] Over the years, new surgical techniques have been proposed to minimize these complications.

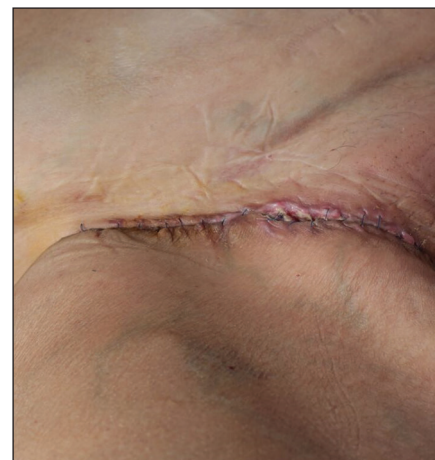

Figure 2: Wound dehiscence

Our aim has been to consider the studies in literature that describe the experience of medial thigh lift, with particular reference to the complications occurred.

MATERIALS AND METHODS

In order to verify the complications of medial thighplasty techniques, we selected the studies dealing with the use of this kind of surgery for the treatment of excessive amount of soft tissue and skin.

A systematic literature search of the PubMed database was carried out using the key words “medial thighplasty,”

“medial thigh lifting,” and “technique.” Additional articles were selected reviewing the references of the papers identified using the abovementioned key words.

Inclusion criteria among these papers were:

- The paper was a case study, case report, clinical trial, open label prospective study, case series, or retrospective study.
- Medial thighplasty was used as a surgical therapy.

Exclusion criteria were:

- The paper does not treat medial thighplasty under a surgical point of view
- The paper was a review of the literature
- Complications related to medial thighplasty were not specified.

The entire PubMed database was considered without restrictions of time. Both English and non-English language papers were included. Each article was tabulated as follows: authors, year of the study, number of patients, location, demographic data, surgical technique, follow-up time, and complications.

All kinds of medial thighplasty techniques were considered. We included patients regardless of the cause that drove the patient to this surgical procedure; it was not only postbariatric patients who were included.

The publications were screened manually and reviewed to identify reports for medial thighplasty techniques. Three investigators independently reviewed and extracted data from the papers according to the predetermined criteria.

RESULTS

We identified 48 full-text articles; 32 did not meet inclusion criteria, leaving 16 studies available from 1988 to 2015 [Table 2].

One was a case report and 15 were retrospective studies. Overall, 447 patients (age: 24-77 years) were treated in the 16 studies. Different surgical techniques were used for thighplasty: fascial anchoring,^[8,9] concentric medial lift,^[10] T-shaped technique,^[5,11] double triangle technique,^[12] scarpa lift,^[13] vertical lift,^[6,7,14] horizontal lift,^[6,7] L-shaped technique,^[15] and personal technique. Follow-up ranged from 0.5 month to 112 months.

The postoperative outcome was satisfactory, with most of the performed techniques. In general, almost all of the patients were satisfied with the dramatic improvement in their medial thigh contour.

Pooling the data, complications were observed in 191/447 patients (42.72%). The most frequent complications were: wound dehiscence (82/447 patients, 18.34%)^[5,6,8-10,12,17-19] seroma (36/447 patients, 8.05%),^[5,6,9,13,18] wound infection (21/447, 4.96%)^[6,11,15,18] hypertrophic scarring (11/447 patients, 2.4%),^[7-10,15] and scar migration (16/447 patients, 3.57%).^[7,10,16,18] Rare complications were partial skin necrosis (one patient)^[18] and lymph fistula (one patient).^[11]

No major complications, such as thromboembolism and sepsis, were observed. In all the studies, the surgical revision rate was 0-18%, with residual contour deformity and hypertrophic scarring representing the most common causes for revision.

Gusenoff^[6] reported the highest complication rate (68%, 72/106 patients) during 1-year follow-up. Wound dehiscence was the most frequent complication; a full-length vertical incision was associated with the highest number of complications.

DISCUSSION

Bariatric surgery for extreme obesity continues to grow in popularity. Massive weight loss following bariatric surgery frequently results in an excess of overstretched skin causing physical discomfort and negatively affecting the quality of life, self-esteem, body image, and physical functioning.^[20] Patients often cannot imagine the degree of dissatisfaction they will experience from the sagging skin that comes with weight loss.^[21] Patients who express unrealistic expectations may be more likely to express disappointment and dissatisfaction with their postoperative result, even if the surgeon believes that the result is acceptable^[22] [Figure 3].

Appropriate psychiatric screening and management of these patients is believed to play an important role in successful postoperative outcomes.

Body contouring surgery produces significant improvements in different aspects of body image, self-esteem, quality of life, physical functioning, social life, working conditions, and general psychopathology after

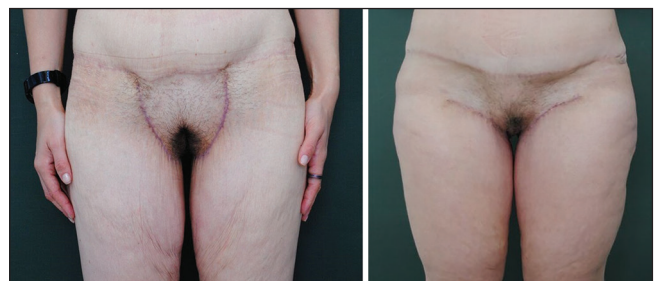


Figure 3: Clinical outcomes 6 months after medial thighplasty

Table 2: Overview of clinical studies on medial thigh lift

Author, year	No. of pts	Location	Demographic data	Surgical technique	Follow-up	Complications (pt = patient; pts = patients)
Lockwood, 1988 ^[8]	18	USA	Not specified	Fascial anchoring	6-24 months (average 12 months)	Slow healing of the posterior wound (2 pts) Unilateral residual adiposity (1 pt) Partial recurrence of ptosis with widening of the scar (1 pt)
Candiani, 1995 ^[9]	18	Italy	Females (35-63 years)	Fascio-fascial suspension	12 months	Seroma (3 pts) Wound separation and delayed healing in the gluteal region (4 pts) Scar revision (2 pts)
Le Louarn, 2004 ^[10]	25	France	Not specified	Concentric medial thigh lift (the direction of the skin stretching is concentric toward the <i>labia minora</i>)	Not specified	Delayed wound healing and scar widening (2 pts) Scar migration (1 pt) Insufficient lift effect (1 pt)
Wolf, 2007 ^[11]	19	Germany	Females	Medial thigh lift, with and without excision of varicose veins	Not specified	Wound infection (8 pts, 42%) Lymph fistula (1 pt)
Bruschi, 2009 ^[5]	35	Italy	Not specified	T-shaped	Not specified	Seroma (3 pts) Anemia (15 pts) Wound dehiscence (2 pts) Hematoma (5 pts)
Rezak, 2010 ^[12]	7	USA	BMI* < 30	Double-triangle technique (integration of the vertical medial thigh lift and monsoplasty)	Not specified	Prolonged lower extremity swelling (1 pt) Cellulitis and wound dehiscence (1 pt)
Richter, 2011 ^[13]	26	Germany	18 females, 8 males. Mean age 37.6 years (24-52 years)	Scarpa lift	3 months-2 years	Seroma (1 pt)
Labardi, 2012 ^[7]	45	Italy	45 females (mean age: 48 years, range: 33-67 years)	15 pts: thigh lift with a horizontal scar (\pm liposuction) 15 pts: a technique with a vertical scar (\pm liposuction) 15 pts: combined procedures (\pm liposuction)	60-month median follow-up (12-108 months)	Scar enlargement due to poor wound healing (1 pt) Scar migration (2 pts) Recurrence of ptosis (1 pt) Scar enlargement due to poor wound healing (3 pts) Scar enlargement due to poor wound healing (2 pts) Recurrence of ptosis (2 pt)
Kim, 2012 ^[14]	1	Korea	Female, 37 years-old	Vertical medial thigh-lift	Not specified	None
Bracaglia, 2013 ^[15]	16	Italy	Mean BMI (SD**) = 31.83 (8.51) kg/m ²	L-shaped medial thigh lift (after selective liposuction)	15 months-8 years	Hypertrophic scarring (2 pts) Wound infection (1 pt)
Aboueldahab, 2013 ^[16]	25	Egypt	Females (25-45 years) BMI < 27	20 pts: medial transverse thigh lift; 5 pts: vertical medial thigh lift with liposuction; circumferential thigh liposuction was performed in two of the vertical lift pts	1 year	Scar migration (2 pts)
Armijo, 2014 ^[17]	29	USA	Ages ranged from 30 years to 67 years	Four-step medial thighplasty	0.5 month- 9.5 years	Wound breakdown (10 pts)
Bertheuil, 2014 ^[18]	53	France	All females. The mean age of the patients was 47.2 \pm 11.4 years	Horizontal technique was used for 94.3% of the pts (n=50). Vertical incision was performed for 3 pts. Liposuction was performed for 71.7% of the pts	The mean follow-up period was 51.1 \pm 21.6 months (12-112 months)	39.6% of the patients experienced at least one complication. Posterior wound dehiscence (11 pts, 20.8%) Scar migration (9 pts, 17%) Seroma (5 pts, 9.4%) Wound infection (3 pts, 5.7%) Partial skin necrosis (1 pt, 1.9%)
Jandali, 2014 ^[19]	21	Scotland	18 females, 3 males Mean age was 38 years (range, 27-52 years)	Modified medial thigh lift (staged liposuction and subsequent resection of the horizontal component followed by deepithelialization of the vertical component; the vertical component is then buried during the closure)	6-12 months	Delayed wound healing (7 pts, 33.3%)

Table 2: (Continued)

Author, year	No. of pts	Location	Demographic data	Surgical technique	Follow-up	Complications (pt = patient; pts = patients)
Wollina, 2014 ^[11]	3	Germany	Female patients with lymph edema (aged 55 years, 72 years, and 77 years) BMI: 33, 35, and 42	T-shape (with laser-assisted liposuction)	2-4 years	Bruising (3 pts)
Gusenoff, 2015 ^[6]	106	USA	90 females, 16 males	14 pts underwent horizontal thighplasty, 24 pts underwent short-scar thighplasty 68 pts underwent full-length vertical thighplasty	12 months	72 pts (68%) had at least one complication. Complications included dehiscence (51%), seroma (25%), infection (16%), and hematoma (6%). Overall, 25 pts (23%) developed edema, which did not resolve in two patients by 12 months. Complication rate of 43% Complication rate of 67% Complication rate of 74%

*BMI: Body mass index, **SD: Standard deviation

bariatric surgery. However, these psychosocial benefits appear to be limited to the first few postoperative years,^[22] and the quality of the sex life of the patient does not seem to improve by this operation.^[23]

There is a significantly increased risk of postoperative complications after body contouring surgery in postbariatric patients as compared to nonbariatric patients; malnutrition, malabsorption may be a possible explanation.^[24,25]

Postbariatric surgery body contouring treatment represents a high cost for the patient or public health system. The severe complications increase by 2.96 times the average cost per patient.^[26]

Fischer,^[27] in 2013, analyzed a total of 1,797 patients who underwent body contouring. The most common area of intervention was the trunk region, with 1,652 patients (91.9%) receiving abdominal contouring and/or contouring of the hips and buttocks. Minor wound complications occurred in 114 (6.3%) individuals, 122 (6.8%) patients suffered a major surgical morbidity, and 40 (2.2%) patients experienced a medical complication. Multiple comorbidities, presence of bleeding disorder, preoperative albumin level, and malnutrition were associated with increased odds of minor wound complications. Inpatient procedures and functional status were associated with increased odds of major surgical morbidity.

Coon^[28] analyzed data of 609 massive weight loss patients who underwent body contouring procedures. The author concluded that minor complication rates

were higher in concomitant procedures than in single-procedure cases.

Body mass index (BMI) before medial thighplasty should be taken into consideration for patients willing to undergo a body-contouring procedure. High BMI before massive weight loss and before medial thighplasty were associated with a higher risk of developing a postoperative complication.^[18]

The most common complication observed in our review was wound dehiscence. Also, Bertheuil^[18] in a retrospective case series found wound dehiscence as the most frequent complication with a very similar complication rate (39.6% of the patients experienced at least one complication).

The analysis of the studies showed no uniformity between the performed surgical techniques. The time of follow-up was not specified in 5/16 studies and the demographic data were not reported in 3/16 studies.

In our review, the second most common complication was seroma.^[5,6,9,13,18] Superficial lymphatic structures and the great saphenous vein and its branches require special attention while performing a medial thigh lift. The thigh lift changes lymphatic drainage in the lower extremities according to lymphoscintigraphy analyses.^[29] Lymphocele treatment requires percutaneous drainage and surgical excision in multiple recurrent cases.^[30] Understanding the topographic anatomy of the limbs [Figure 4] may help explain body-contour deformities and provide the anatomic basis for a successful surgical correction.^[31,32]

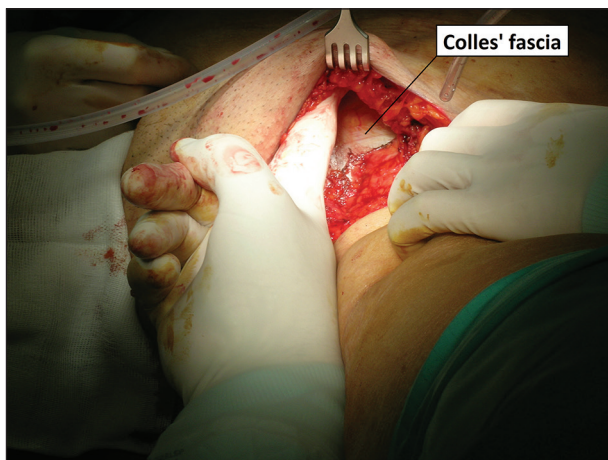


Figure 4: Colles' fascia (superficial perineal fascia); it is important to recognize and preserve this anatomical structure during dissection of the overlying skin-fat layer

The main limits of this analysis were the high heterogeneity of the study populations. Selection bias and lack of common outcome measures were some of the problems that prevented a proper meta-analysis. Although this review is not a meta-analysis, we critically assessed the literature and tried to identify high-quality studies. Moreover, many of the technique papers showing favorable results are biased by authors promoting their preferred techniques.

CONCLUSIONS

Medial thigh lift is a satisfying procedure because it provides aesthetic improvement in terms of skin excess and laxity. Complications are frequent but life-threatening complications have not been reported. The use of a vertical incision (wider than the horizontal one) is related to a higher risk of complication. Performing more concomitant surgical procedures on the same patient and a high preoperative BMI of the patient are related to a higher risk of complications.

Financial support and sponsorship

Nil.

Conflicts of interest

There are no conflicts of interest.

REFERENCES

- Lewis JR Jr. Correction of ptosis of the thighs: The thigh lift. *Plast Reconstr Surg* 1966;37:494-8.
- Song AY, Jean RD, Hurwitz DJ, Fernstrom MH, Scott JA, Rubin JP. A classification of contour deformities after bariatric weight loss: The Pittsburgh Rating Scale. *Plast Reconstr Surg* 2005;116:1535-46.
- Kenkel JM, Eaves FF 3rd. Medial thigh lift. *Plast Reconstr Surg* 2008;122:621-2.
- Lewis JR Jr. The thigh lift. *J Int Coll Surg* 1957;27:330-4.
- Bruschi S, Datta G, Bocchiotti MA, Boriani F, Obbialero FD, Fracalvieri M. Limb contouring after massive weight loss: Functional rather than aesthetic improvement. *Obes Surg* 2009;19:407-11.
- Gusenoff JA, Coon D, Nayar H, Kling RE, Rubin JP. Medial thigh lift in the massive weight loss population: Outcomes and complications. *Plast Reconstr Surg* 2015;135:98-106.
- Labardi L, Gentile P, Gigliotti S, Marianetti M, Colicchia GM, Pascali M, et al. Medial thighplasty: Horizontal and vertical procedures after massive weight loss. *J Cutan Aesthet Surg* 2012;5:20-5.
- Lockwood TE. Fascial anchoring technique in medial thigh lifts. *Plast Reconstr Surg* 1988;82:299-304.
- Candiani P, Campiglio GL, Signorini M. Fascio-fascial suspension technique in medial thigh lifts. *Aesthetic Plast Surg* 1995;19:137-40.
- Le Louarn C, Pascal JF. The concentric medial thigh lift. *Aesthetic Plast Surg* 2004;28:20-3.
- Wollina U, Heinig B, Nowak A. Treatment of elderly patients with advanced lipedema: A combination of laser-assisted liposuction, medial thigh lift, and lower partial abdominoplasty. *Clin Cosmet Investig Dermatol* 2014;7:35-42.
- Rezak KM, Borud LJ. Integration of the vertical medial thigh lift and monsoplasty: The double-triangle technique. *Plast Reconstr Surg* 2010;126:153e-4e.
- Richter DF, Stoff A. The scarpa lift — a novel technique for minimal invasive medial thigh lifts. *Obes Surg* 2011;21:1975-80.
- Kim SW, Han HH, Seo JW, Lee JH, Oh DY, Ahn ST, et al. Two cases of lower body contouring with a spiral and vertical medial thigh lift. *Arch Plast Surg* 2012;39:67-70.
- Bracaglia R, Tambasco D, Gentileschi S, D'Ettoire M. L-Shaped lipothighplasty. *Ann Plast Surg* 2015;75:261-5.
- Aboueldahab AK. Liposuction-assisted medial thigh lift in obese and non obese patients. *J Cutan Aesthet Surg* 2013;6:217-25.
- Armijo BS, Campbell CF, Rohrich RJ. Four-step medial thighplasty: Refined and reproducible. *Plast Reconstr Surg* 2014;134:717e-25e.
- Bertheuil N, Thienot S, Huguier V, Ménard C, Watier E. Medial thighplasty after massive weight loss: Are there any risk factors for postoperative complications? *Aesthetic Plast Surg* 2014;38:63-8.
- Jandali Z, Loh CY, Athanassopoulos T, Müller K. An improved dual approach to post bariatric contouring - Staged liposuction and modified medial thigh lift: A case series. *Indian J Plast Surg* 2014;47:232-5.
- de Zwaan M, Georgiadou E, Strohm CE, Teufel M, Köhler H, Tengler M, et al. Body image and quality of life in patients with and without body contouring surgery following bariatric surgery: A comparison of pre- and post-surgery groups. *Front Psychol* 2014;5:1310.
- Lanthaler M, Mattesich M, Nehoda H, Puelzl P, Matiasek J, Nitto A, et al. Long-term quality-of-life improvement in gastric banding patients from body-contouring surgery. *Am Surg* 2015;81:34-40.
- Sarwer DB, Fabricatore AN. Psychiatric considerations of the massive weight loss patient. *Clin Plast Surg* 2008;35:1-10.
- Bertheuil N, Thienot S, Chaput B, Varin A, Watier E. Quality-of-life assessment after medial thighplasty in patients following massive weight loss. *Plast Reconstr Surg* 2015;135:67e-73e.
- Hasanbegovic E, Sørensen JA. Malabsorption after bariatric surgery can increase the risk of post-operative complications of the following plastic surgery. *Ugeskr Laeger* 2014;176. pii: V01140051.
- Hasanbegovic E, Sørensen JA. Complications following body contouring surgery after massive weight loss: A meta-analysis. *J Plast Reconstr Aesthet Surg* 2014;67:295-301.
- Vilà J, Balibrea JM, Oller B, Alastrué A. Post-bariatric surgery body contouring treatment in the public health system: Cost study and perception by patients. *Plast Reconstr Surg* 2014;134:448-54.
- Fischer JP, Wes AM, Serletti JM, Kovach SJ. Complications in body contouring procedures: An analysis of 1797 patients from the 2005 to 2010 American College of Surgeons National Surgical Quality

- Improvement Program databases. *Plast Reconstr Surg* 2013;132:1411-20.
28. Coon D, Michaels J 5th, Gusenoff JA, Purnell C, Friedman T, Rubin JP. Multiple procedures and staging in the massive weight loss population. *Plast Reconstr Surg* 2010;125:691-8.
 29. Moreno CH, Neto HJ, Junior AH, Malheiros CA. Thighplasty after bariatric surgery: Evaluation of lymphatic drainage in lower extremities. *Obes Surg* 2008;18:1160-4.
 30. Borud IJ, Cooper JS, Slavin SA. New management algorithm for lymphocele following medial thigh lift. *Plast Reconstr Surg* 2008; 121:1450-5.
 31. Abu-Hijleh MF, Roshier AL, Al-Shboul Q, Dharap AS, Harris PF. The membranous layer of superficial fascia: Evidence for its widespread distribution in the body. *Surg Radiol Anat* 2006;28:606-19.
 32. Tourani SS, Taylor GI, Ashton MW. Understanding the three-dimensional anatomy of the superficial lymphatics of the limbs. *Plast Reconstr Surg* 2014;134:1065-74.