

# Syringocystadenoma Papilliferum of the Scalp Arising from a Nevus Sebaceous

Mathangi Chandramouli, Digvijay Sarma, Kapil Tejaswy, Gabriel Rodrigues

Department of General Surgery, Kasturba Medical College, Manipal University, Manipal, Karnataka, India

**Address for correspondence:** Prof. Gabriel Rodrigues, Department of General Surgery, Kasturba Medical College, Manipal University, Manipal - 576 104, Karnataka, India. E-mail: drbelapadhiar@gmail.com

## ABSTRACT

Syringocystadenoma papilliferum (SCAP) is a rare, benign tumour with varied presentations that arises from the apocrine glands and at times can lead to a diagnostic dilemma. A 53-year-old male presented with a 40-year history of a scalp nodule and a recent 2-year change in its character, and a sanguinopurulent discharge. Examination revealed a 4 cm × 2 cm firm nodule upon left side of the scalp vertex, actively discharging pus and blood. No regional lymph nodes were noticeably palpable. Incision biopsy performed elsewhere showed evidence of a squamous cell carcinoma-*in-situ*. He underwent a wide local excision with a bilobed flap reconstruction. Histopathologically, the lesion was reported to be SCAP. On follow-up, the patient has since remained asymptomatic with an acceptable cosmetic recovery.

**KEYWORDS:** Excision, prognosis, reconstruction, scalp nodule, squamous cell carcinoma, syringocystadenoma papilliferum

## INTRODUCTION

Syringocystadenoma papilliferum (SCAP), due to its numerous presentations, and relative scarcity, is more often than not, misdiagnosed.<sup>[1]</sup> Albeit a benign hamartomatous tumour, it has the capacity to mimic a malignancy.<sup>[2]</sup> Being aware of this condition can prevent misdiagnoses and perhaps even overtreatment.

## CASE REPORT

A 53-year-old male presented with a swelling on the vertex of his scalp of 40-year duration. It was initially a minimally raised lesion of about 1 cm and was non-progressive in size or shape. Over the past 2 years, he noticed an insidious, progressive growth into a painless, nodular swelling that had also started to secrete pus and bloody discharge. The patient is otherwise known to be generally healthy, with no comorbidities. Detailed background history revealed no family history of malignancies or prolonged exposure to sunlight. Local

examination revealed a 4 cm × 2 cm firm, immobile, non-tender, non-fluctuant, verrucous swelling on the vertex of the scalp and slightly favouring the left side. Sanguinopurulent discharge was evident along with crusting surrounding the lesion [Figure 1]. No other lesions were present, nor were regional lymph nodes palpable. The patient was otherwise clinically normal on systemic examination. Routine laboratory tests inclusive of a haemogram and a complete metabolic profile were within normal limits. Chest roentgenogram and cardiac parameters were also within acceptable bounds. An incisional biopsy done at another institution revealed squamous cell carcinoma *in situ*, which was reconfirmed in this institution during the slide review. Due to the clinical presentation of the patient, as well as a presumably reliable histopathologic diagnosis,

This is an open access article distributed under the terms of the Creative Commons Attribution-NonCommercial-ShareAlike 3.0 License, which allows others to remix, tweak, and build upon the work non-commercially, as long as the author is credited and the new creations are licensed under the identical terms.

**For reprints contact:** reprints@medknow.com

**How to cite this article:** Chandramouli M, Sarma D, Tejaswy K, Rodrigues G. Syringocystadenoma papilliferum of the scalp arising from a nevus sebaceous. *J Cutan Aesthet Surg* 2016;9:204-6.

### Access this article online

#### Quick Response Code:



**Website:**  
www.jcasonline.com

**DOI:**  
10.4103/0974-2077.191656

a decision was made to excise the lesion. The patient underwent a wide local excision with 1 cm clear margins. The defect was reconstructed with a bilobed flap, where two triangle flaps are designed; the angle of the first flap is three-fourths the angle of a rhombus at the defect site, and the angle of the second flap is also three-fourths that of the first flap [Figures 2 and 3]. Grossly, the lesion was 3.5 cm × 3.5 cm showing a nodule. Cut section revealed a cyst of 1 cm × 0.8 cm filled with haemorrhagic material, containing a tiny grey nodule, surrounded by grey-white and yellow fatty areas. Microscopically, it showed a hyperkeratotic epidermis with foci of papillomatosis, focal absence of hair follicles, focal primitive hair germ-like proliferations with patchy perivascular lymphocytic infiltrate. Dermis and subdermis contained a large uniloculated cyst lined by flattened epithelium, containing a focus of closely packed slender papillary projections with hyalinised cores and lined by bilayered epithelium: Luminal columnar apocrine epithelium and abluminal round clear myoepithelial cells. No atypical or malignant cells were seen [Figure 4]. In view of the

archetypal findings, a diagnosis of SCAP was made. Postoperatively, the patient made a good recovery though minimal flap edge necrosis occurred, that was managed conservatively. On follow-up of 6 months, the lesion showed no evidence of recurrence, and cosmetically exhibited suitable restoration [Figure 5]. The patient continues to follow-up in the clinic.

## DISCUSSION

SCAP, once a rare phenomenon, is becoming an increasingly diagnosed entity. It is a benign hamartomatous tumour arising from the adnexae of sweat glands.<sup>[2]</sup> The exact origin is still being debated; it is understood to be either eccrine or apocrine, which can only be distinguished by immunohistochemistry and ultrastructural studies.<sup>[3]</sup>

SCAP can present in a multitude of manners based on the type, given by the classification according to Katoulis

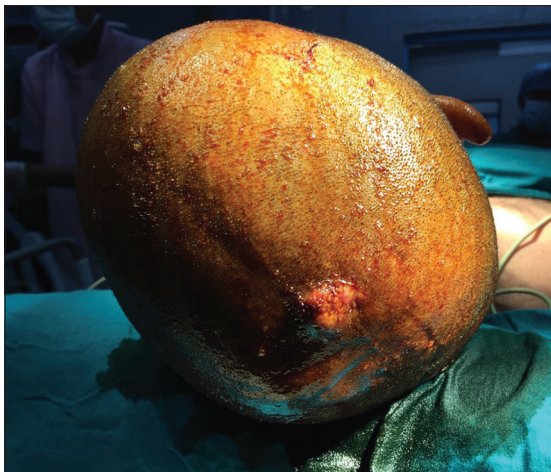


Figure 1: Intraoperative picture showing ulcerated, nodular lesion on the vertex

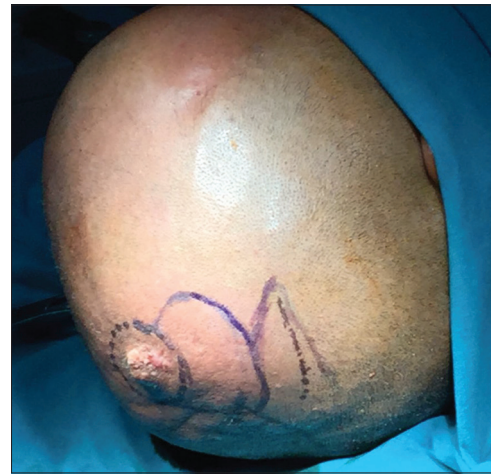

Figure 2: Marking for wide local excision and bilobed flap reconstruction

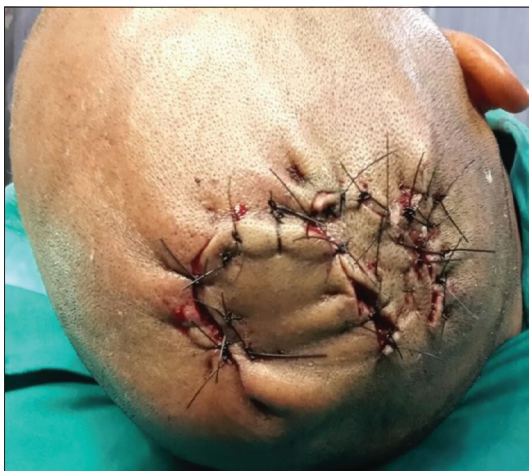

Figure 3: Post-surgery and reconstruction

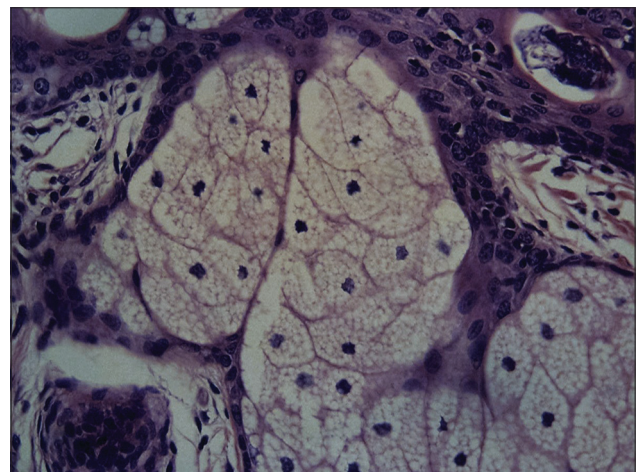
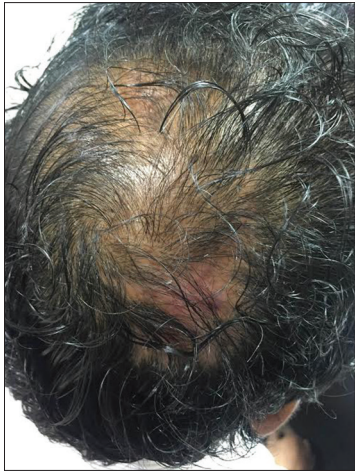

Figure 4: Photomicrograph showing hyperkeratotic epidermis with foci of papillomatosis, focal absence of hair follicles, focal primitive hair germ-like proliferations with patchy perivascular lymphocytic infiltrate (H and E, ×60)





**Figure 5: Follow-up, 6 months**

and Bozi.<sup>[4]</sup> The first, a plaque type, presents upon the scalp as a hairless lesion, which can be present from birth, and thereafter increases during the onset of puberty into nodular or verrucous entity. This type is most often closely, but not mandatorily, associated with a sebaceous nevus of Jadassohn. The second, a linear type, usually presents with multiple papules of similar size, with an umbilicated appearance, often being confused with a diagnosis of molluscum contagiosum. The last, a solitary nodule, usually presents on the trunk, perhaps on the genitalia, shoulders or axillae.

Regardless of the type, the histopathology of the lesion is usually the same and renders the same prognosis. Malignant transformation of this lesion is possible, usually to basal cell carcinoma in 10% of cases, uncommonly to squamous cell carcinoma and rarely to its malignant counterpart: Syringocystadenocarcinoma papilliferum.<sup>[5]</sup>

Clinical diagnosis is, on most counts, not feasible. Due to the various presentations and possible differential diagnoses, histopathology would yield the most practical, as well as accurate option. Having said that, knowledge of this diagnosis would add a supplementary alternative to our clinical suspicions.

Treatment for SCAP is surgical excision, which has a two-pronged benefit. Should this lesion undergo future

malignant degeneration, excision sufficiently eliminates that risk. Secondly, excision allows cosmetic relief for the patient, should it be a concern. A bilobed flap is usually used to reconstruct the scalp defects which has advantages such as: (1) The dispersion tension on the flap provides stable circulation and prevents expansion of scar formation; (2) since the suture line is zigzag, alopecia at the suture line can be hidden under the hair; (3) since this flap is a random pattern flap using galea aponeurotica with blood flow to the skin, flap design is possible for any part of the scalp and (4) design and elevation of this flap are easy and do not take much time.<sup>[6]</sup> It has also been treated with Mohs micrographic surgery and CO<sub>2</sub> laser excision with success.<sup>[1]</sup>

## CONCLUSION

Awareness of the various possible presentations of SCAP can prevent misdiagnoses and overtreatment. Natural history of SCAP is yet to be determined, thus prevention is not yet an option. Excision of the lesion is the mainstay of treatment, but wide margins are not necessary.

## Financial support and sponsorship

Nil.

## Conflicts of interest

There are no conflicts of interest.

## REFERENCES

1. Arslan H, Diyarbakir M, Batur S, Demirkesen C. Syringocystadenocarcinoma papilliferum with squamous cell carcinoma differentiation and with locoregional metastasis. *J Craniofac Surg* 2013;24:e38-40.
2. Peterson J, Tefft K, Blackmon J, Rajpara A, Fraga G. Syringocystadenocarcinoma papilliferum: A rare tumor with a favorable prognosis. *Dermatol Online J* 2013;19:19620.
3. Castillo L, Moreno A, Tardío JC. Syringocystadenocarcinoma papilliferum *in situ*: Report of a case with late recurrence. *Am J Dermatopathol* 2014;36:348-52.
4. Katoulis AC, Bozi E. Syringocystadenoma papilliferum. *Orphanet Encyclopedia* 2004;1:1-3.
5. Iga N, Fujii H, Miyake T, Ehara M, Kore-Eda S. Syringocystadenocarcinoma papilliferum in the perianal area. *Case Rep Dermatol* 2015;7:84-9.
6. Iida N, Ohsumi N, Tonegawa M, Tsutsumi Y. Reconstruction of scalp defects using simple designed bilobed flap. *Aesthetic Plast Surg* 2000;24:137-40.