



Review Article

Potential execution of vitiligo surgery by the most conceivable technique – which, where, and why?

Sushil S. Savant Jr¹, Satish S. Savant¹

¹Department of Dermatology, The Humanitarian Clinic: Skin, Hair and Laser Centre, Mumbai, Maharashtra, India.

***Corresponding author:**

Sushil S. Savant Jr.,
Department of Dermatology,
The Humanitarian Clinic:
Skin, Hair and Laser Centre,
Mumbai, Maharashtra, India.
sushilsavant786@gmail.com

Received: 27 July 2023
Accepted: 17 August 2023
Published: 21 October 2024

DOI
[10.25259/jcas_128_23](https://doi.org/10.25259/jcas_128_23)

Quick Response Code:



ABSTRACT

While various treatment options exist for vitiligo, surgical interventions have gained significant attention due to their potential for long-lasting repigmentation. Several surgical procedures have been developed, including miniature punch grafting, thin Theirsch's split-thickness skin grafting (STSG), suction blister technique, and ultrathin STSG. The decision-making process should also consider the potential risks and benefits associated with each technique. Factors such as graft survival, color match, post-operative complications, and long-term stability of repigmentation should be evaluated. In addition, patient factors such as comorbidities, skin type, and psychological impact should be carefully considered to ensure optimal surgical outcomes. We, hereby, aim to explore the potential execution of vitiligo surgery using the most conceivable technique, considering factors such as efficacy, safety, and patient-specific characteristics.

Keywords: Efficacy, Vitiligo, Safety, Surgery

INTRODUCTION

In stable vitiligo, surgical intervention is indicated when it is refractory to the conventional medical line of treatment/phototherapy.^{1,2} This can be achieved by various surgical methods such as permanent camouflaging – tattooing (T)^{3,4} or surgically activating the lesional and perilesional dormant melanocyte reservoir – therapeutic wounding (TW)^{3,5,6} or seeding (transplanting) the area either through autologous tissue graft/grfts – miniature punch grafting (MPG),^{3,7} thin Theirsch's split-thickness skin grafting (STSG),^{3,8} suction blister technique (SBT),^{3,9} ultrathin split-thickness skin grafting (UTSG)^{3,10,11} single – hair follicular unit transplant (FUT),¹² follicular unit extraction (FUE),¹³ eyelash transplantation,¹⁴ or cellular suspensions/culture – autologous non-cultured melanocytes – keratinocytes cell suspension (NCMKCS),^{3,15-18} autologous cultured melanocytes,^{3,15,19,20} autologous epidermal cell transfer technique (Jodhpur technique),²¹ etc. Most of them have claimed good to excellent results (60–95% re-pigmentation)^{3,22} with whichever surgical method they have adopted, depending on the type, size, site, and stability of the vitiligo lesion, and age and color complexion of the patient. Addition of psoralen (P) and ultraviolet radiation (UVA) (PUVA) or psoralen and UVA obtained by sunlight (PUVASOL), or narrow-band ultraviolet light B (NBUVB), or excimer laser/lamp phototherapy enhances the rate of pigmentation with an increased overall success rate (90–95%).^{3,11,20-23} All these techniques aim to achieve uniform re-pigmentation, color match, and good cosmesis. The dermatosurgeon is often in a dilemma to deciding the ideal surgical modality in an individual case as all these have their advantages, disadvantages, limitations, and complications.^{3,22-24}

This is an open-access article distributed under the terms of the Creative Commons Attribution-Non Commercial-Share Alike 4.0 License, which allows others to remix, transform, and build upon the work non-commercially, as long as the author is credited and the new creations are licensed under the identical terms.

©2024 Published by Scientific Scholar on behalf of Journal of Cutaneous and Aesthetic Surgery

TATTOOING (T)

Advantages

It is only a camouflaging procedure. It is useful for small patches located on the lip [Figure 1], nipple, and genitalia in dark-complexioned individuals to achieve a good color match. It gives instantaneous results and is useful in emergencies (impending marriage, job interviews, and medical examinations).^{3,4,22}

Disadvantages

It has limitations and complications such as mismatched color, change in color shade, fading of color, and reaction to tattoo pigments over time.^{3,4,22}

THERAPEUTIC WOUNDING (TW)

Advantages

In this technique, faster re-pigmentation can be induced with various wounding techniques to cover large areas (dermabrasion/laser ablation) as well as small residual areas (phenol, trichloroacetic acid [TCA], and needling with or without 5-fluorouracil [5-FU] cream) [Figure 2].^{3,5,6,22,25}

Disadvantages

It can be carried out only in hairy areas where 25–50% of the existing hair is black.^{3,5,6,22,25}

MINIATURE PUNCH GRAFTING (MPG)

Advantages

It is a simple and friendly office-based technique for dermatologists with a high success rate of re-pigmentation and can be carried out on most body parts [Figure 3]. It is best suited and highly recommended for acral vitiligo (fingertips and toe tips) [Figure 4], for palms and soles, and genital vitiligo [Figure 5].^{3,7,22,24} None of the other available techniques give satisfactory results due to local factors such as the absence of hair follicles thick epidermis, constant (frictional) trauma, and inadequate depth achieved during dermabrasion/carbon dioxide (CO₂) laser ablation.^{3,7,22,24} Other than T, punch grafting can be done over the vulva with the fixation of grafts with cyanoacrylate glue.²⁶

Disadvantages

Cobble-stoning, polka dot appearance, de-pigmented junctional line, superficial scarring of the donor site, etc., are some of its limitations and complications.^{3,7,22,24}

Over time, changes have been made to procedures such as the way tissue for transplants is obtained, which has reduced

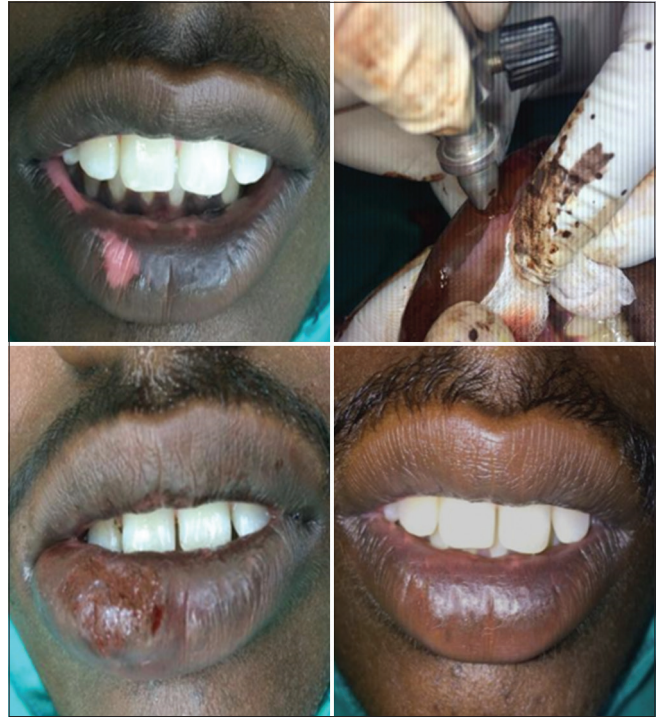

Figure 1: Tattooing in lip vitiligo.

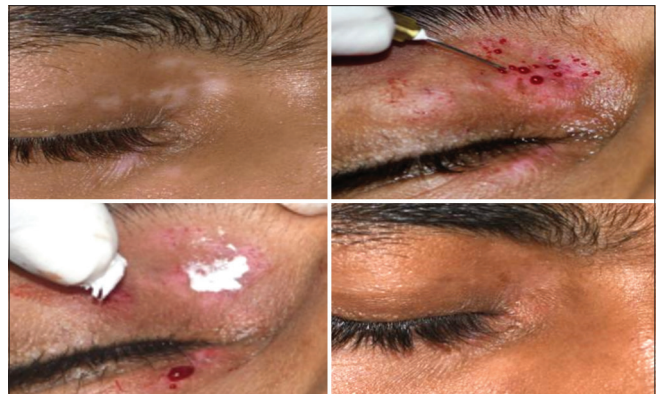

Figure 2: Therapeutic wounding.

the possible complications. In a case study, Hirobe and Enami showed the use of an electric micro-drill to create a graft that was 1.5–1.8 mm deep and had a diameter of 0.6–1.0 mm. This reduced the chance of cobblestoning and enhanced pigment distribution.²⁷ According to a clinical trial conducted by Ragab *et al.*, the greatest degree of repigmentation and fastest response were obtained with mini-punch grafting and weekly needling over 6 months. Only transverse needling and mini-punch grafts outperformed the control group in terms of outcomes. There were no documented negative effects related to steroids. Consequently, the application of transverse needling after mini-punch grafting positively impacts the ultimate therapeutic outcomes. Compared to MPG and needling done separately, this adjustment enables

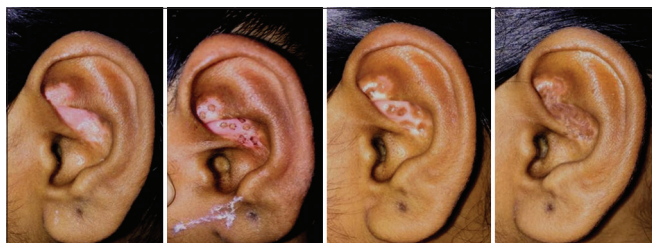


Figure 3: Miniature punch grafting for vitiligo focalis in conchae or ear.

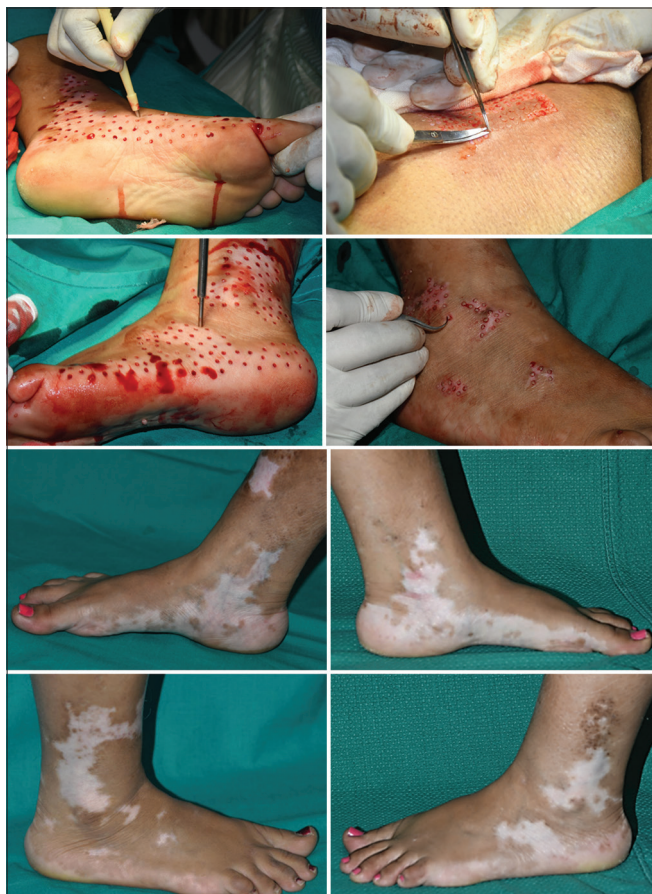

Figure 4: Miniature punch grafting for acral vitiligo.

one to achieve a higher degree of repigmentation in less time and with the lowest cumulative dose of NB-UVB.²⁸

THIN THIERSCH'S SPLIT THICKNESS SKIN GRAFT (STSG)

Advantages

It achieves fast results; large areas can be covered with a high rate of excellent pigmentation, color match, and cosmesis. It can cover most of the body sites except fingertips, toe tips, palms, and soles.^{3,8,22,24}

Disadvantages

Hyperpigmentation of the graft at the recipient area, perilesional halo, stuck-on tire appearance, beaded borders, etc., are some of its main limitations and complications.^{3,8,22,24}

SUCTION BLISTER TECHNIQUE (SBT)

Advantages

It is one of the best methods to obtain excellent repigmentation and color match as there is direct transfer/transplant of melanocytes from the epidermal graft [Figure 6]. It is a safe, inexpensive office-based procedure.^{3,9,22,24}

Disadvantages

It is time-consuming, sometimes there may be hyperpigmentation or incomplete pigmentation, and only small areas (lips and eyelids) can be treated at 1 time.^{3,9,22,24}

Consequently, other methods that are effective for creating suction blisters for grafting have been recently developed. These methods include a unique Korean method based on cups with valves, modified syringe procedures that include a three-way tap system, or a formula that uses an automated device called CelluTome™ for epidermal graft harvesting.²⁹⁻³⁴ All body areas appear acceptable for blister formation, although the thigh or the forearm remains the preferable site, given that scarring following suction blister epidermal graft (SBEG) is an extremely rare complication.³⁵ Furthermore, research findings have indicated that SBEG is effective in treating regions such as the lips' angles, which are commonly considered to be extremely difficult to cure.⁹ Iwanowski *et al.* and Hann *et al.* found that phototherapy can be used as a complementary treatment following successful grafting.^{35,36}

ULTRATHIN SPLIT-THICKNESS SKIN GRAFTING (UTSG)

Advantages

It is one of the best methods to obtain a high success rate of excellent re-pigmentation, color match, and cosmesis as there is direct transfer/transplant of melanocytes from the ultrathin graft which dries off or is peeled off or slightly thicker graft (>0.005 inch/0.1 mm) gets taken up as STSG [Figure 7]. Vitiliginous areas of any size, shape, and at any place can be treated except fingertips, toe tips, palms, and soles.^{3,10,11,22,23}

Disadvantages

Time consuming procedure, requires expensive equipment, and surgical expertise, and can cover vitiliginous areas in a 1:1 ratio only.^{3,10,11,22,23}

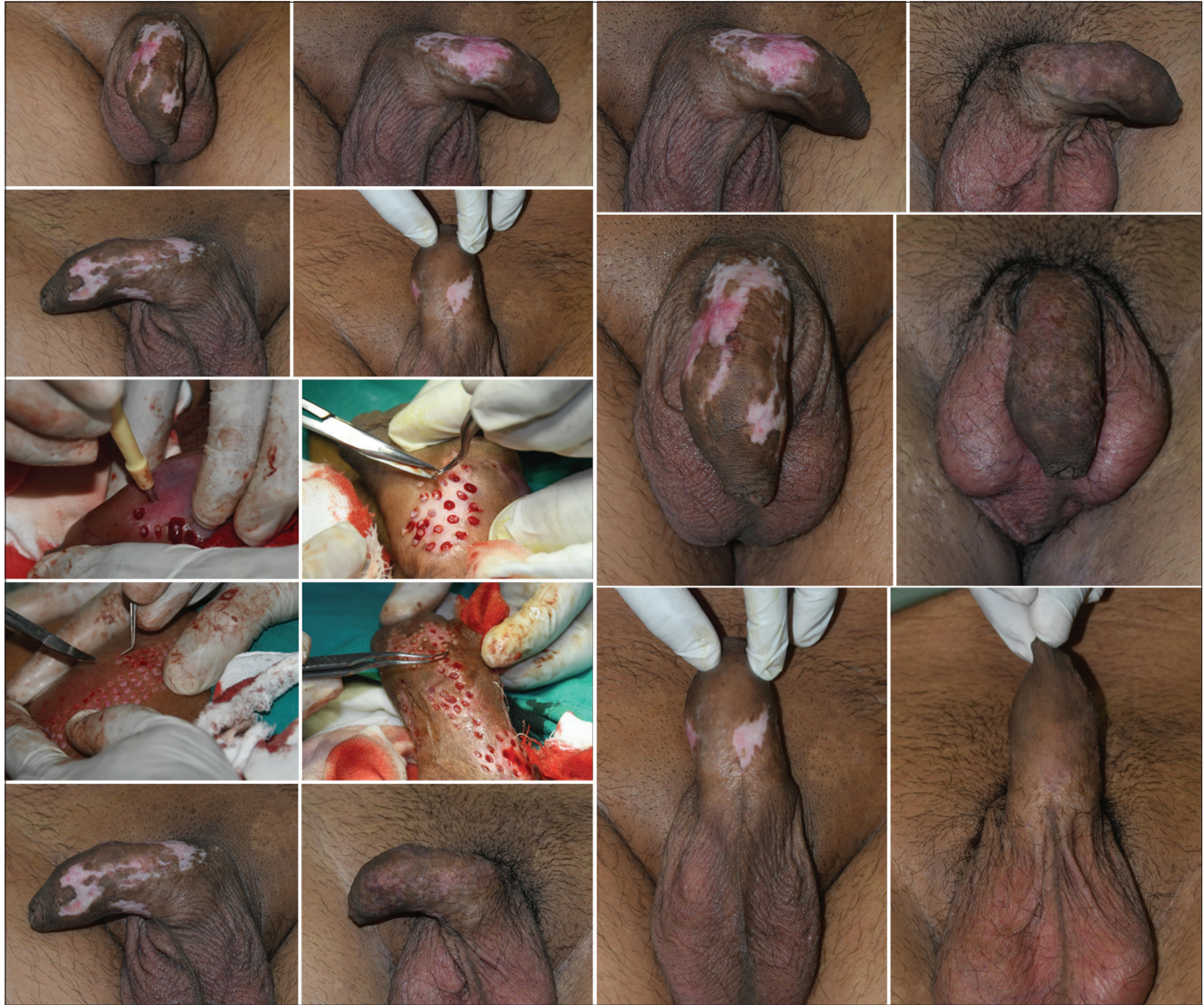

Figure 5: Miniature punch grafting for genital vitiligo.

SINGLE - HAIR FOLLICULAR UNIT TRANSPLANT (FUT), FOLLICULAR UNIT EXTRACTION (FUE), AND EYELASH TRANSPLANTATION

Advantages

These are extremely good methods to treat vitiliginous patches on the scalp, leukotrichia of eyelashes or eyebrows, mustache, and beard areas with good re-pigmentation.¹²⁻¹⁴

Disadvantages

It is tedious, time-consuming, requires a longer learning curve, there is scarring at the donor site and it is difficult to treat medium to large-size lesions and glabrous areas with

them. Donor hair can be taken from any hairy area, for example, scalp beard, or any other body parts.¹²⁻¹⁴

AUTOLOGOUS NON-CULTURED MELANOCYTES - KERATINOCYTES CELL SUSPENSION (NCMKCS) TRADITIONAL METHOD AND MODIFIED METHOD WITH READYMADE KIT

Advantages

This is a very good method to achieve excellent re-pigmentation, color match, and cosmesis as there is direct transfer/transplant of melanocytes to the recipient's vitiliginous lesion. Ten-fold (average 5 folds) large vitiliginous area can be treated at 1 time with small size donor graft

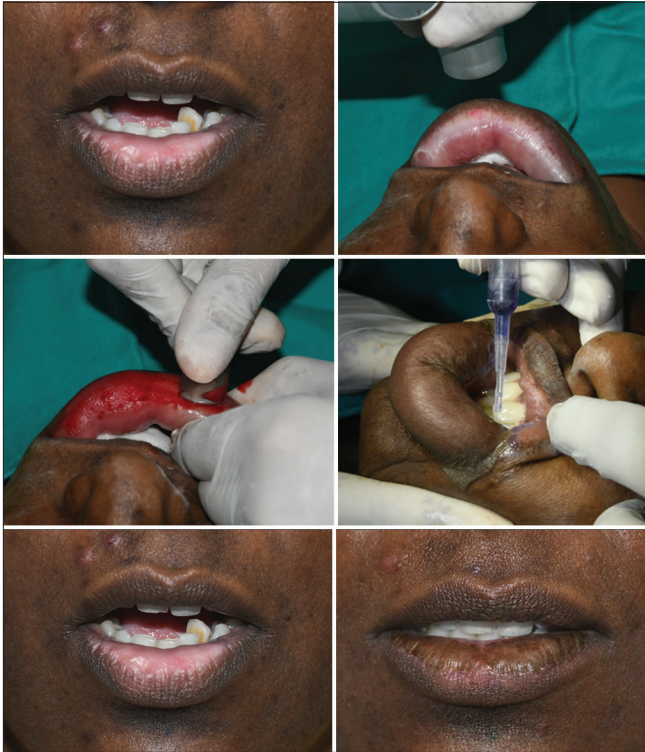

Figure 6: Suction blister grafting for lip vitiligo.

[Figure 8]. Vitiliginous areas of any size, shape, and at any place can be treated except fingertips, toe tips, palms, and soles.^{3,15-18,22,24,37}

Disadvantages

It requires a long time for the spread of pigment, special efforts such as making the suspension viscous are required to retain the suspension (liquid form) over the grafted recipient sites, is time-consuming, and requires special laboratory equipment and chemicals (culture media, solutions) and one has to learn the laboratory techniques. Now, in India, there are specially made ready-made kits available to carry out this procedure, which has the added advantage that they are cost-effective, do not require storage of expensive laboratory chemicals, better-modified media is supplied, and trypsin inhibition is not required; however, the procedure is same.^{3,15-18,22,24,37}

AUTOLOGOUS CULTURED MELANOCYTES

Advantages

In this technique, large areas can be treated at 1 time with a small skin sample resulting in excellent repigmentation with good color match, cosmesis, and uniform texture as melanocytes are directly transferred/transplanted. Vitiliginous areas of any size, shape, and at any place can be treated except fingertips, toe tips, palms, and soles.^{3,15,19,20,22}

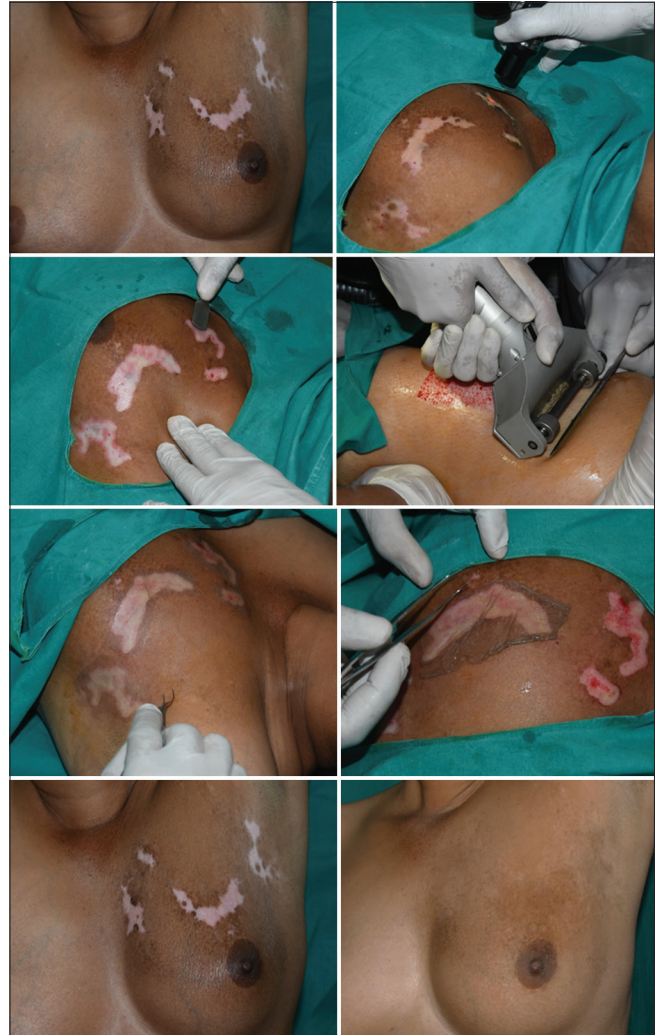

Figure 7: Ultra-thin skin grafting for segmental vitiligo.

Disadvantages

It requires a longer time interval, an expensive procedure, and requires state of art laboratory setup, there are concerns regarding the mutagenicity of certain ingredients of the culture media, it is a two-stage procedure that is not yet commercially available in India.^{3,15,19,20,22}

AUTOLOGOUS EPIDERMAL CELL TRANSFER TECHNIQUE (JODHPUR TECHNIQUE)

Advantages

It is a simple, safe, and inexpensive office-based procedure that can be carried out with minimal complications and gives excellent re-pigmentation and good color match. It is found to be useful in treating perilesional halo.

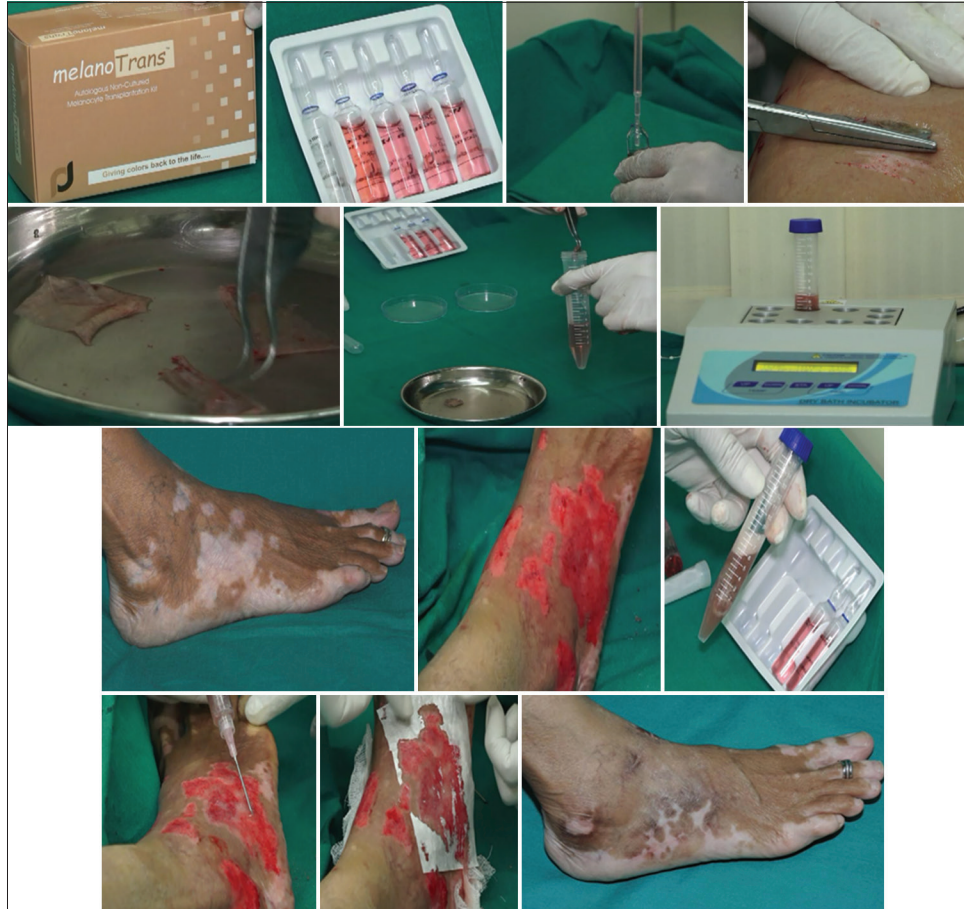

Figure 8: Preparation of Autologous non-cultured melanocytes-keratinocytes cell suspension.

Disadvantages

It has its limitations such as the slow spread of pigment, needing to be combined with phototherapy, achromic/hypochromic skip areas being left behind, it is difficult to treat large lesions and lesions over lips, fingertips, toe tips, palms, and soles.^{21,22,38}

Despite the limitations, complications, and disadvantages of various techniques, there are certain advantages of each of these techniques mentioned. Njoo *et al.*³⁹ in one meta-analysis reported that 87% of the patients achieved more than 75% repigmentation with SBT, which was similar to split thickness grafting (87%), but better than mini grafting (68%) and grafting of non-cultured epidermal suspensions (31%). In UTSG, the success rate of re-pigmentation reported varied from 95% to 99%.^{3,10,11,22,23,40} Total re-pigmentation was reported with TW in 46 (88.5%) out of 52 hairy sites.⁵ In a study with NCMKCs, segmental and focal vitiligo showed the best results in all the cases followed by generalized vitiligo.^{17,37} In another study on epidermal grafting, it was reported that segmental and focal vitiligo responded better (91% achieving >75% re-pigmentation) than generalized vitiligo (53%, *P*

< 0.001). However, there was no significant difference in repigmentation rates at different body sites.⁴¹ Most of the techniques have reported better results in focal and segmental vitiligo (75–95%) than in generalized vitiligo. Younger (20–30 years) and darker-complexioned patients have better results. Comparatively, acral areas, malleoli, knees, and elbows are less responsive to surgery. Smaller patches respond better. Post-vitiligo surgery PUVA, PUVASOL, NBUVB, and excimer laser/lamp phototherapy accelerate repigmentation and increase the success rate (90–95%).^{3,11,21-23,40}

FACTORS DECIDING TYPE OF VITILIGO SURGERY

Patient selection

- a. This is the most important criterion that a patient's vitiligo should be stable before planning for any vitiligo surgery. Stable vitiligo is a term coined for such cases, wherein the disease is inactive along with no eruption of fresh lesions, no progression of pre-existing lesions, and no sign of Koebner's phenomenon for the past 1 year.²⁶ Koebner's phenomenon

may occur in the form of recurrence of vitiligo at the donor or recipient site in the form of the appearance of new lesions in unstable patients or if the disease has become reactive after stability. Hence, proper selection of patients is important to either minimize or avoid these complications.^{2,3,22,24} It is advisable to do a test grafting using 3–5 mini-punch grafts and observe for its positive response to confirm the stability before treating patients with large lesions with any of the opted/selected surgical modalities. Cyanoacrylate glue can be used to fix the graft in all difficult (periorbital, genital, concha, umbilicus, areola, and underarms) places for surgery that can avoid difficult dressing.⁴²⁻⁴⁶

- b. In patients with unrealistic expectations, it is better to avoid surgery. Proper patient counseling and information regarding expected results, complications, and cost of the procedure should be discussed with the patient and further documented to avoid medico-legal complications.
- c. The axillary area can be used as an incubator to reduce the cost of the procedure.⁴⁷

Cosmetic priority

For exposed cosmetically important areas such as the scalp, face including eyebrows and eyelashes, part of the neck, fingers, hands, and forearm, one has to choose the modality that gives the best cosmetic results depending on the size of the area involved [Table 1]. For areas that are not exposed, most of the modalities are useful and the choice should be given to the patient.

Time bound priority

Some patients require fast results in certain emergencies such as impending marriage, job interviews, or medical examinations, leaving very little time at the disposal of the dermatologist. Such patients can be treated by either T or STSG which give fast results as discussed earlier.

Location of the lesion

Most of the techniques can be carried out to re-pigment vitiliginous lesions located over various parts of the body. However, some technique/techniques are found to be useful for specific body parts [Table 1].^{3,5,6,8,9-18,22-26}

Size of the lesion

This is one of the important factors, which decides the modality to be followed:

- a. Small-sized patches (1–4 cm): SBT, MPG, STSG, UTSG, and hair follicular grafts (FUT, FUE, or body hair transplantation [BHT]) will give good results. T works equally well in dark individuals preferably if the patch is located on the lip nipple or genitals.
- b. Medium-to-large sized patch: Noncultured epidermal cell suspension (NCECS), UTSG, STSG, Jodhpur technique, and serial MPG done over multiple sittings are the modalities of choice.

Size of punch

The smaller the size of the punch, the better the result. Small sizes of punch (1.0 and 1.5 mm) can be accepted well in all difficult sites of surgery.⁴⁸

Depth of the punch

The depth of the donor should be less than the depth of the punch removed from the recipient site to prevent cobblestoning.⁴⁸

Pattern of the shape of the vitiligo lesion

- a. Round or oval – UTSG, NCECS, STSG, MPG, and Jodhpur technique; depending on the size, location of the lesion, and other factors.
- b. Geographical amoeboid with narrow tentacles – MPG, Jodhpur technique, TW (needling), and miniature

Table 1: Site and treatment of choice.

Site	Treatment of choice
1. Lips and eyelids	SBT, STSG, and UTSG
2. Hairy areas with 25–50% black hairs	TW.
3. Scalp, beard, mustache, eyebrows, and eyelashes	Eyelash Transplant, BHT Single hair FUT, and FUE
4. Tips of fingers, toes, palms, and soles	MPG
5. Face and neck	Autologous NCMKCS, STSG, and UTSG
6. Angle of mouth	MPG-Tattooing in dark patients and UTSG
7. Trunks and limbs	Autologous NCMKCS, MPG Jodhpur technique STSG, and UTSG
8. Genitals	
Vulva	Tattooing
Penis and scrotum	Tattooing UTSG, and MPG

SBT: Suction blister technique, STSG: Split thickness skin grafting, UTSG: Ultrathin split-thickness skin grafting, TW: Therapeutic wounding, FUT: Follicular unit transplant, FUE: Follicular unit extraction, MPG: Miniature punch grafting, NCMKCS: Non-cultured melanocytes – keratinocytes cell suspension, BHT: Body hair transplantation

punch grafts can be inserted between the existing pigmented island

- c. Small remnants – TW (needling [with or without 5-FU cream], TCA, and phenol)
- d. The semi-circular – peri-lesional halo commonly seen after STSG can be successfully re-pigmented by re-grafting with UTSG, STSG, autologous cultured melanocytes, and Jodhpur technique
- e. Small achromic fissures – skip areas or peri graft halo areas around MPG. In all such cases, re-pigmentation can be stimulated by PUVA, PUVASOL, NBUBV, excimer laser/lamp phototherapy, or topical steroid/tacrolimus creams.

Degree of existing hypo/depigmentation in the vitiliginous area

All the residual islands of hypopigmentation should be dermabraded or laser ablated before carrying out any suitable procedure as leaving these islands of hypopigmentation in between will result in poor cosmetic outcomes as the resultant color will not match. In MPG also it is advisable to remove these islands and not to graft on them as when these grafts get taken up, there is no spread of pigment in these hypopigmented areas, whereas in achromic areas with MPG, there is a good spread of pigment with complete repigmentation.

Existing color of hair in vitiligo area

- a. If 25–50% of hair is black, then TW will induce good repigmentation in small, medium, or even large-sized vitiliginous areas
- b. For lesions on the scalp with white hair or if there is leukotrichia of eyebrows or eyelashes then FUT, FUE, or BHT or eyelash transplant will achieve good cosmesis
- c. It is observed that vitiligo surgery done by most of the techniques will induce re-pigmentation in 30–60% of existing white hair in the lesion during re-pigmentation of the achromic areas and continue to respond over the next 6 months–2 years.

Set up

- a. Office setup: Most of the procedures can be carried out in an office set up under local anesthesia (LA) or tumescent LA for lesions of any size either in single or multiple serial sessions. Even if patches are large and require short general anesthesia (IV ketamine), they can be managed in an office setup with an operation theater facility
- b. Hospital setup: This is required if regular general anesthesia is required as when lesions are large (extremity) or when it is large and located over sensitive areas (face and genital area) and when immobilization is required (major joints).

Technical support

- a. Tissue culture laboratories are needed for melanocyte culture grafting
- b. Costly devices, such as laboratory equipment (centrifuge, incubator, and chemicals – for traditional method) NCMKCS
- c. CO₂ laser and power dermatome (Zimmer) for UTSG
- d. Ultraviolet light units (PUVA/NBUBV) or excimer laser/lamp (308 nm) facility for accelerating re-pigmentation after vitiligo surgery
- e. Same as trypsin inhibitor, Dulbecco's modified eagle medium (DMEM) medium can also be optional to use in the process of melanocyte transplant.⁴¹

Surgical expertise

This is another significant and probably the single most important criterion in selecting the procedure. Some techniques such as MPG or SBT are simple and easy to learn, whereas certain surgical expertise is required to obtain uniformly thin split-thickness grafts for the STSG technique. Similarly, the UTSG technique not only one to obtain ultrathin (0.005/0.1 mm) skin graft but also must acquire the skill to ablate the vitiliginous recipient site using CO₂ laser with proper freehand technique to cause dermo-epidermal split (bubbling effect). For retaining grafts over genital areas, one may need expertise to take fine stay sutures to secure the grafts. As discussed so far, similar cosmetic results can be achieved using various modalities and dermatosurgeons may prefer to choose the modality that they are best trained in. A few dermatosurgeons have acquired good skills in multiple techniques. Their long-term experience and expertise will help them in deciding the right surgical method. Some methods may be tedious, time-consuming, and delicate with long learning curves such as FUT, FUE, BTH, and eyelash transplantation, and will require experience, expertise, and vigil. Hence, one must select a method in which one is most comfortable.

CONCLUSION

Summarizing, one can say that various surgical techniques are useful to treat stable vitiligo; however, proper selection of the technique will play a major role in achieving good therapeutic results. Each technique has its advantages and disadvantages. Some may be simple to carry out, while some may cause more side effects. Sometimes, one may have to modify and adapt a few technical variations. Sometimes, more than one technique may have to be carried out in a given patient, such as SBT for lips, MPG for tips, or UTSG or SBT on lips with T at the angles of the mouth. All these permutations and combinations will thus enable the dermatosurgeon to achieve better cosmetic results.

Authors' contributions

Sushil Savant and Satish Savant contributed to data collection, analysis and interpretation, and drafting of the article. Sushil Savant contributed to critical revision of the article and final approval of the version to be published.

Ethical approval

Institutional Review Board approval is not required.

Declaration of patient consent

The authors certify that they have obtained all appropriate patient consent.

Financial support and sponsorship

Nil.

Conflicts of interest

There are no conflicts of interest.

Use of artificial intelligence (AI)-assisted technology for manuscript preparation

The authors confirm that there was no use of artificial intelligence (AI)-assisted technology for assisting in the writing or editing of the manuscript and no images were manipulated using AI.

REFERENCES

- Frączek A, Kasprończyc-Furmańczyk M, Placek W, Owczarczyk-Saczonek A. Surgical treatment of vitiligo. *Int J Environ Res Public Health* 2022;19:4812.
- Parsad D, Gupta S, IADVL Dermatosurgery Task Force. Standard guidelines of care for vitiligo surgery. *Indian J Dermatol Venereol Leprol* 2008;74:S37-45.
- Savant SS. Surgical therapy of vitiligo: Current status. *Indian J Dermatol Venereol Leprol* 2005;71:307-10.
- Kerure AS, Marwah M, Wagh ND, Udare S. Micropigmentation. *Indian Dermatol Online J* 2023;14:605-10.
- Savant SS. Therapeutic spot and regional dermabrasion in stable vitiligo. *Indian J Dermatol Venereol Leprol* 1996;62:139-45.
- Savant SS, Shenoy S. Chemical peeling with phenol: For the treatment of stable vitiligo and alopecia areata. *Indian J Dermatol Venereol Leprol* 1999;65:93-8.
- Savant SS. Autologous miniature punch skin grafting in stable vitiligo. *Indian J Dermatol Venereol Leprol* 1992;58:310-5.
- Mukhtar M. A novel technique for getting mini thin Thiersch's skin grafts for tiny vitiligo lesions. *CosmoDerma* 2022;2:106.
- Kar BR, Raj C. Suction blister epidermal grafting for vitiligo involving angles of lip: Experience of 112 patients. *J Cutan Aesthet Surg* 2018;11:13-9.
- Falabella R. Vitiligo and the melanocyte reservoir. *Indian J Dermatol* 2009;54:313-8.
- Savant SS Jr., Savant SS. A comprehensive surgical *in vivo* study of autologous melanocyte transplant/transfer through ultrathin skin grafting over CO₂ ablated lesions supplemented with excimer lamp (308 nm) therapy in stable vitiligo. *Indian J Dermatol Venereol Leprol* 2024;90:150-7.
- Kumaresan M. Single-hair follicular unit transplant for stable vitiligo. *J Cutan Aesthet Surg* 2011;4:41-3.
- Sacchidanand S, Thakur P, Purohit V, Sujaya SN. Follicular unit extraction as a therapeutic option for vitiligo. *J Cutan Aesthet Surg* 2013;6:229-31.
- Chatterjee M, Neema S, Vasudevan B, Dabbas D. Eyelash transplantation for the treatment of vitiligo associated eyelash leucotrichia. *J Cutan Aesthet Surg* 2016;9:97-100.
- Olsson MJ, Juhlin L. Long-term follow-up of leucoderma patients treated with transplants of autologous cultured melanocytes, ultrathin epidermal sheets and basal cell layer suspension. *Br J Dermatol* 2002;147:893-904.
- Gupta S, Relhan V, Garg VK, Sahoo B. Autologous noncultured melanocyte-keratinocyte transplantation in stable vitiligo: A randomized comparative study of recipient site preparation by two techniques. *Indian J Dermatol Venereol Leprol* 2019;85:32-8.
- Bassiouny D, Esmat S. Autologous non-cultured melanocyte-keratinocyte transplantation in the treatment of vitiligo: Patient selection and perspectives. *Clin Cosmet Investig Dermatol* 2018;11:521-40.
- Shah AN, Marfatia RK, Saikia SS. A study of non-cultured extracted hair follicle outer root sheath cell suspension for transplantation in vitiligo. *Int J Trichol* 2016;8:67-72.
- Zokaei S, Farhud DD, Keykhaei M, Zarif Yeganeh M, Rahimi H, Moravvej H. Cultured epidermal melanocyte transplantation in vitiligo: A review article. *Iran J Public Health* 2019;48:388-99.
- Ghosh D, Kuchroo P, Viswanathan C, Sachan S, Shah B, Bhatt D, *et al.* Efficacy and safety of autologous cultured melanocytes delivered on poly (DL-lactic acid) film: A prospective, open-label, randomized, multicenter study. *Dermatol Surg* 2012;38:1981-90.
- Kachhawa D, Kalla G. Keratinocyte-Melanocyte graft technique followed by PUVA therapy for stable vitiligo. *Indian J Dermatol Venereol Leprol* 2008;74:622-4.
- Savant SS, editor. *Vitiligo surgery: Which? where? why? textbook of dermatosurgery and cosmetology principles and practice*. 3rd ed., Vol. 48. Mumbai, India: Bhalani Publishing House; 2018. p. 623-7.
- Majid I, Imran S. Ultrathin split-thickness skin grafting followed by narrowband UVB therapy for stable vitiligo: An effective and cosmetically satisfying treatment option. *Indian J Dermatol Venereol Leprol* 2012;78:159-64.
- Khunger N, Kathuria SD, Ramesh V. Tissue grafts in vitiligo surgery-past, present and future. *Indian J Dermatol* 2009;54:150-8.
- Chhabra S, Chahar YS, Singh A. Comparative study of micro-needling combined with topical 5-fluorouracil versus Microneedling alone in treatment of localized stable vitiligo. *I. J Dermatol* 2021;66:574.
- Gupta DK, Devendra S. Microskin grafting for stable vitiligo of

- the penis and vulva: Near total uniform pigmentation. *J Cutan Med Surg* 2015;19:477-83.
27. Hirobe T, Enami H. Excellent color-matched repigmentation of human vitiligo can be obtained by mini-punch grafting using a machine in combination with ultraviolet therapy. *Dermatol Sin* 2018;36:203-6.
 28. Ragab M, El Zagh O, Farid C. Transverse needling after autologous mini-punch grafts improves repigmentation in stable non-segmental vitiligo. *Clin Cosmet Investig Dermatol* 2021;14:827-35.
 29. Angeletti F, Kaufmann R. Suction blister epidermal graft (SBEG)-An easy way to apply this method. *J Dtsch Dermatol Ges* 2019;17:468-71.
 30. Anbar TS, Moftah NH, El-Khayyat MA, El-Fakahany HM, Abdel-Rahman AT, Saad EK. Syringes versus Chinese cups in harvesting suction-induced blister graft: A randomized split-body study. *Int J Dermatol* 2018;57:1249-52.
 31. Gupta S, Shroff S, Gupta S. Modified technique of suction blistering for epidermal grafting in vitiligo. *Int J Dermatol* 1999;38:306-9.
 32. Smith OJ, Edmondson SJ, Bystrzonowski N, Hachach-Haram N, Kanapathy M, Richards T, *et al.* The CelluTome epidermal graft-harvesting system: A patient-reported outcome measure and cost evaluation study. *Int Wound J* 2017;14:555-60.
 33. Hachach-Haram N, Bystrzonowski N, Kanapathy M, Smith O, Harding K, Mosahebi A, *et al.* A prospective, multicentre study on the use of epidermal grafts to optimise outpatient wound management. *Int Wound J* 2017;14:241-9.
 34. Janowska A, Dini V, Panduri S, Macchia M, Oranges T, Romanelli M. Epidermal skin grafting in vitiligo: A pilot study. *Int Wound J* 2016;13:47-51.
 35. Iwanowski T, Szlázak P, Rustowska A, Sokołowska-Wojdyło M. Efficacy of suction blister epidermal grafting with concomitant phototherapy in vitiligo treatment. *Postepy Dermatol Allergol* 2018;35:592-8.
 36. Hann SK, Im S, Bong HW, Park YK. Treatment of stable vitiligo with autologous epidermal grafting and PUVA. *J Am Acad Dermatol* 1995;32:943-8.
 37. Mulekar SV. Long term follow up study of segmental and focal vitiligo treated by autologous non-cultured melanocyte-keratinocyte cell transplantation. *Arch Dermatol* 2004;140:1211-5.
 38. Sonthalia S, Kachhawa D. Jodhpur technique. In: *Stat Pearls*. Treasure Island, FL: Stat Pearls Publishing; 2023. Available from: <https://www.ncbi.nlm.nih.gov/books/NBK549891> [Last accessed on 2024 May 05].
 39. Njoo MD, Westerhof W, Bos JD, Bossuyt MM. A systematic review of autologous transplantation methods in vitiligo. *Arch Dermatol* 1998;134:1543-5.
 40. Savant SS, editor. Ultra-Thin skin grafting (UTSG) (melanocyte transplant/transfer). In: *Textbook of dermatosurgery and cosmetology principles and practice*. 3rd ed., Vol. 45. Mumbai: Bhalani Publishing House; 2018. p. 585-95.
 41. Majid I. Grafting in vitiligo: How to get better results and how to avoid complications. *J Cutan Aesthet Surg* 2013;6:83-9.
 42. Kattan AE, Mortada H, Alkahtani R, Bin Idris R, Gelidan AG, Alhumsi T. The use of cyanoacrylate glue for skin grafts stabilisation: A retrospective multicenter study. *Int Wound J* 2023;20:79-84.
 43. Habib A, Mehanna A, Medra A. Cyanoacrylate: A handy tissue glue in maxillofacial surgery: Our experience in Alexandria, Egypt. *J Maxillofac Oral Surg* 2013;12:243-7.
 44. Alovisi M, Erovigni F, Bianchi L, Longhi B, Scotti N, Pasqualini D, *et al.* Surgical wound repair with innovative hemostatic glue: Clinical case report. *Appl Sci* 2023;13:8979.
 45. Curings P, Vincent PL, Viard R, Gir P, Comparin JP, Voulliaume D. The advantages in using cyanoacrylate glue over skin staples as a method of skin graft fixation in the pediatric burns population. *Ann Chir Plast Esthet* 2018;63:323-9.
 46. Losi P, Burchielli S, Spiller D, Finotti V, Kull S, Briganti E, *et al.* Cyanoacrylate surgical glue as an alternative to suture threads for mesh fixation in hernia repair. *J Surg Res* 2010;163:e53-8.
 47. Bhatia S, Rajput L, Gupta S. Axillary incubator for cell-based therapies in vitiligo. *J Am Acad Dermatol* 2021;85:e279-80.
 48. Agarwal US. Chapter 4: Punch grafting. In: *Dermatologic surgery made easy*. New Delhi, India: Jaypee Digital Explore Health Sciences; 2006.

How to cite this article: Savant S S. Jr., Savant S. Potential execution of vitiligo surgery by the most conceivable technique – which, where, and why? *J Cutan Aesthet Surg*. 2024;17:282-91.doi: 10.25259/jcas_128_23