

Autologous Smashed Follicular Dermal Graft with Epidermal Cell Suspension in Chronic Nonhealing Leg Ulcers

Umashankar Nagaraju, Pranami Kashyap, Leena Raveendra

Department of Dermatology, Venereology and Leprology, RajaRajeswari Medical College and Hospital, Bengaluru, Karnataka, India

Abstract

Wound healing is a multifaceted process. Restoration of the epithelium may occur either by migration of activated epithelial keratinocytes from the adjoining epithelium or by centrifugal migration of putative stem cells found in the bulge region of the hair follicle. Dermal collagen and glycosaminoglycans also play a key role in laying down the scaffold for vascular in-growth and population of the matrix with host fibroblasts. Despite the availability of a wide range of treatment modalities, chronic nonhealing leg ulcers remain a therapeutic challenge and cause significant patient morbidity. Hence, there is a further need to develop novel techniques which would be effective, safe, easily available, and affordable for the patient.

Keywords: Chronic leg ulcer, epidermal cell suspension, smashed follicular dermal graft, wound healing

INTRODUCTION

Chronic leg ulcers are chronic wounds of the leg that show no tendency to heal after 6 weeks despite appropriate treatment, thereby causing significant patient morbidity.^[1] Wound healing is a multifaceted process involving clot formation, cell migration and proliferation, extra cellular matrix synthesis and deposition, contraction, and finally dermal and epidermal reconstitution.^[2]

Hence, we took up 12 cases of chronic nonhealing leg ulcers for a novel procedure combining smashed follicular dermal grafts with autologous epidermal cell suspension, which contributes to wound healing by being a source of follicular stem cells, epidermal keratinocytes, and dermal collagen.

TECHNIQUE

After acquiring approval from the Institutional Ethics Committee and informed written consent from each subject, complete evaluation with relevant basic investigations were carried out to find out the primary cause of ulcer. The procedure was performed on only healthy leg ulcers under local anesthesia in an outpatient setting.

Equipments needed

The following are the list of the equipments used in the study: graft-harvesting dermatome, angular graft holding forceps, biopsy punches (3.5 mm), incubator, centrifuge, centrifuge tubes, prilocaine cream, compression bandage, paraffin gauze, petri dishes, 2-mL disposable syringe and sterile glass side, Reagents-Trypsin EDTA, and Dulbecco's modified Eagle's medium.

Steps of the procedure

Step 1: Preparation of epidermal cell suspension

The anterolateral aspect of thigh was taken as the donor site and anaesthetized using topical 2% lidocaine and prilocaine cream. An ultra-split thickness epidermal graft was harvested from the donor site with a ratio of donor-to-recipient area of 1:4, using graft-harvesting dermatome [Figure 1]. The graft was then trypsinized with the epidermis facing upward in a petri dish [Figure 2]

Address for correspondence: Dr. Pranami Kashyap,
Department of Dermatology, Venereology and Leprology,
RajaRajeswari Medical College and Hospital, Mysore Road,
Bengaluru 560074, Karnataka, India.
E-mail: pranks14kash@gmail.com

This is an open access journal, and articles are distributed under the terms of the Creative Commons Attribution-NonCommercial-ShareAlike 4.0 License, which allows others to remix, tweak, and build upon the work non-commercially, as long as appropriate credit is given and the new creations are licensed under the identical terms.

For reprints contact: reprints@medknow.com

How to cite this article: Nagaraju U, Kashyap P, Raveendra L. Autologous smashed follicular dermal graft with epidermal cell suspension in chronic nonhealing leg ulcers. J Cutan Aesthet Surg 2020;13:38-42.

Access this article online

Quick Response Code:



Website:
www.jcasonline.com

DOI:
10.4103/JCAS.JCAS_105_19

and incubated at 37°C for 50 min, following which it was recovered and transferred to Dulbecco's Modified Eagle's medium in another petri dish. Using graft-holding forceps, the graft was gently agitated to separate the epidermal components from the dermis [Figure 3]. Then the cell suspension was centrifuged at 3000rpm for 10 min. The cellular sediment obtained [Figure 4] was aspirated into a 2-mL syringe for application.

Step2: Preparation of smashed follicular dermal grafts

Dermal grafts were harvested using a 3.5-mm punch, spaced at least 5mm from each other, making sure each graft consisted of a hair follicle [Figure 5]. Two grafts per cm² of ulcer area were taken. The grafts were placed on a glass slide [Figure 6] and minced with a pair of scissors into a semisolid paste, and aspirated into the same syringe containing ECS. The donor area was closed with paraffin gauze dressing, which was opened after 7 days.

Step3: Application of dermal graft and ECS to wound bed

The final suspension consisting of smashed follicular dermal graft with ECS was applied evenly over the ulcer bed [Figure 7]. The ulcer was covered with paraffin gauze and elastic bandage.

The subject was put on antibiotics for 5 days. The dressing was removed on day 7 post-procedure.

Follow-up

The subjects were subsequently followed up with regular paraffin gauze dressing up to 8 weeks or until the ulcer

healed, whichever was earlier. Ulcer area, volume, and photographic records with a high-resolution 20-megapixel digital camera were recorded weekly [Figure 8A–C and 9A–C].

In our experience of this technique, 41.6% of the ulcers healed by 4 weeks post-procedure, and 100% ulcers had healed completely by the 8th week. At the end of 4 weeks, mean percentage of improvement in ulcer area

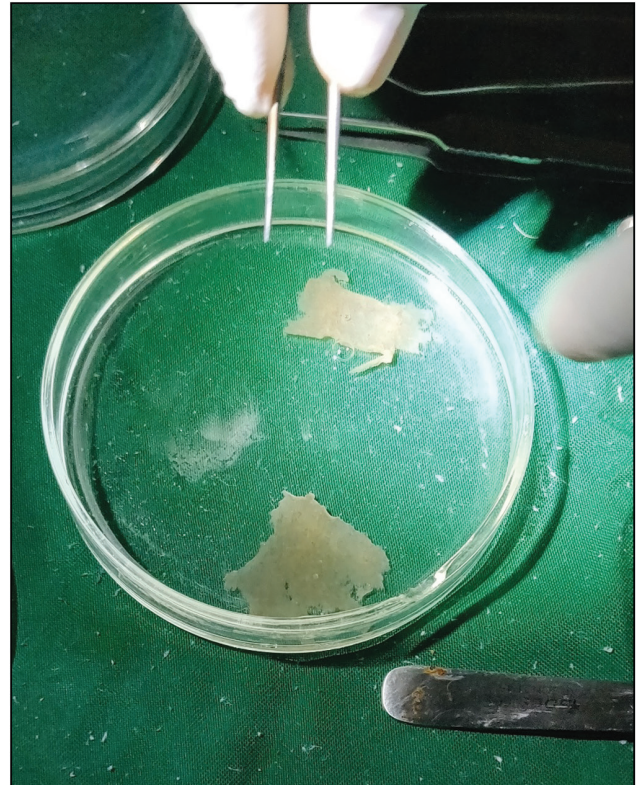


Figure 2: Graft trypsinized in a petridish

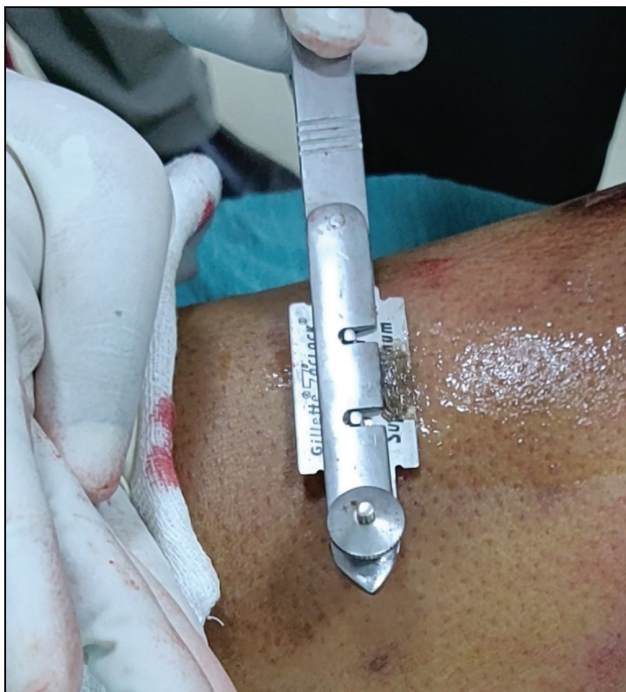

Figure 1: Ultra-split thickness epidermal graft harvested from donor area using graft-harvesting dermatome

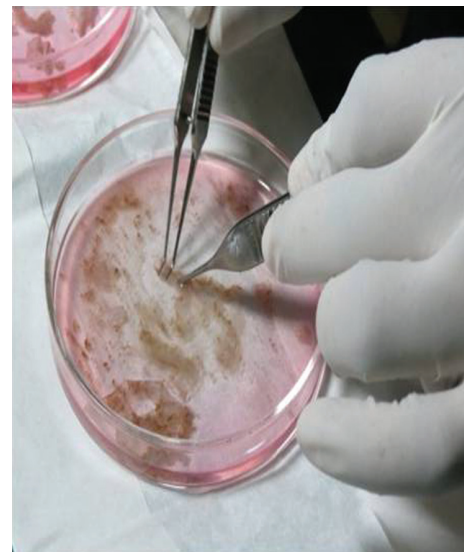

Figure 3: Separation of epidermal component from dermis by gentle agitation in DMEM



Figure 4: Cellular sediment after centrifugation at 3000 rpm for 10 min

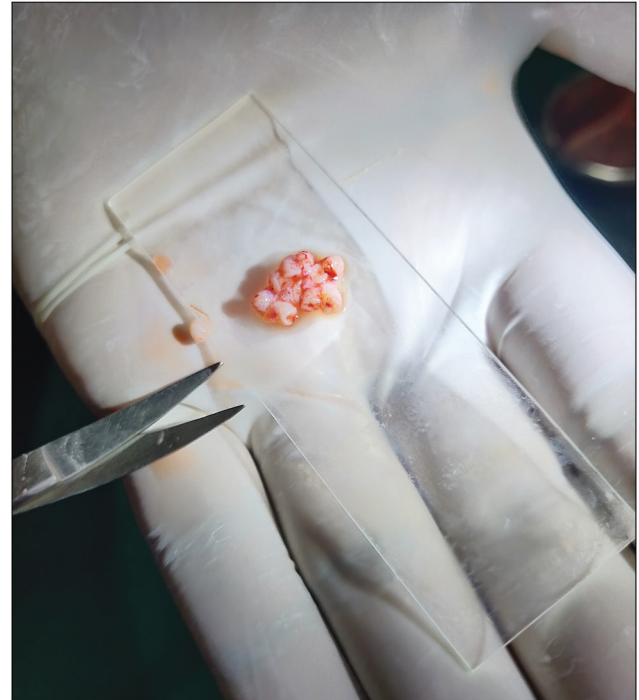


Figure 6: Follicular dermal grafts placed on a glass slide and minced into a semisolid paste

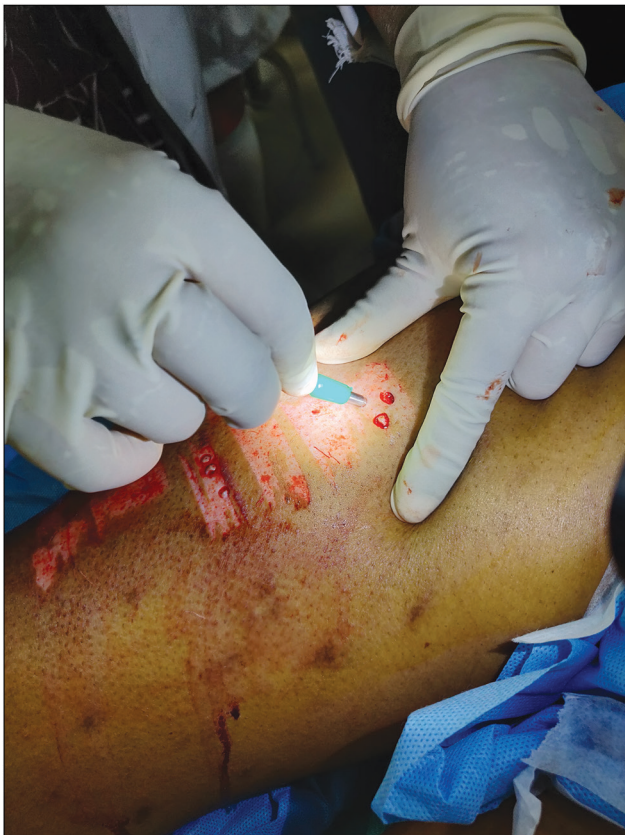

Figure 5: Follicular dermal grafts harvested using a 3.5-mm punch from the donor area

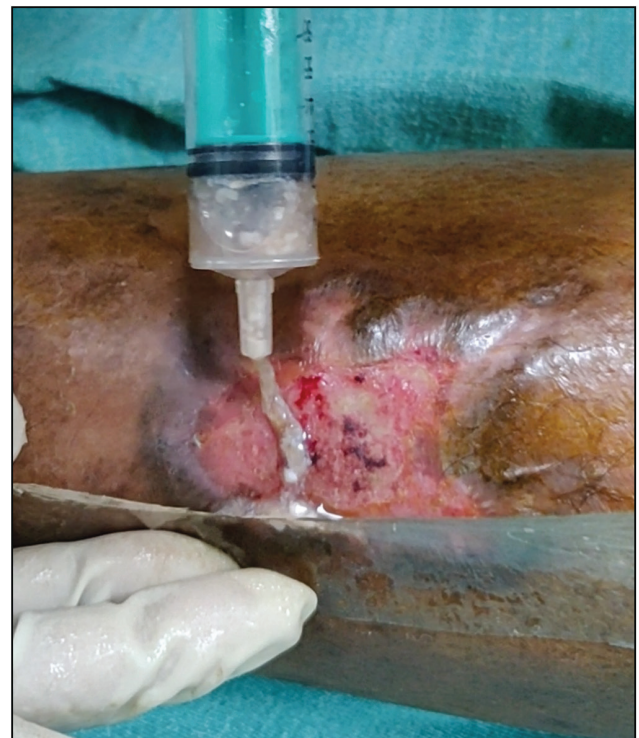

Figure 7: Application of the suspension evenly over the ulcer bed

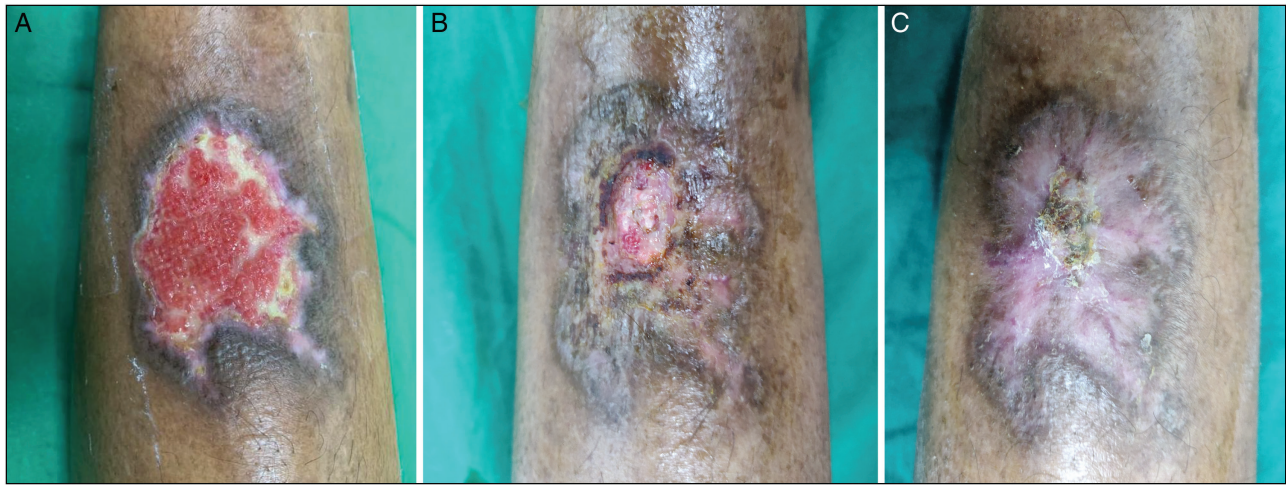

Figure 8: A healing traumatic ulcer: (A) at baseline, (B) on day 7 post-procedure, and (C) at week 4 post-procedure

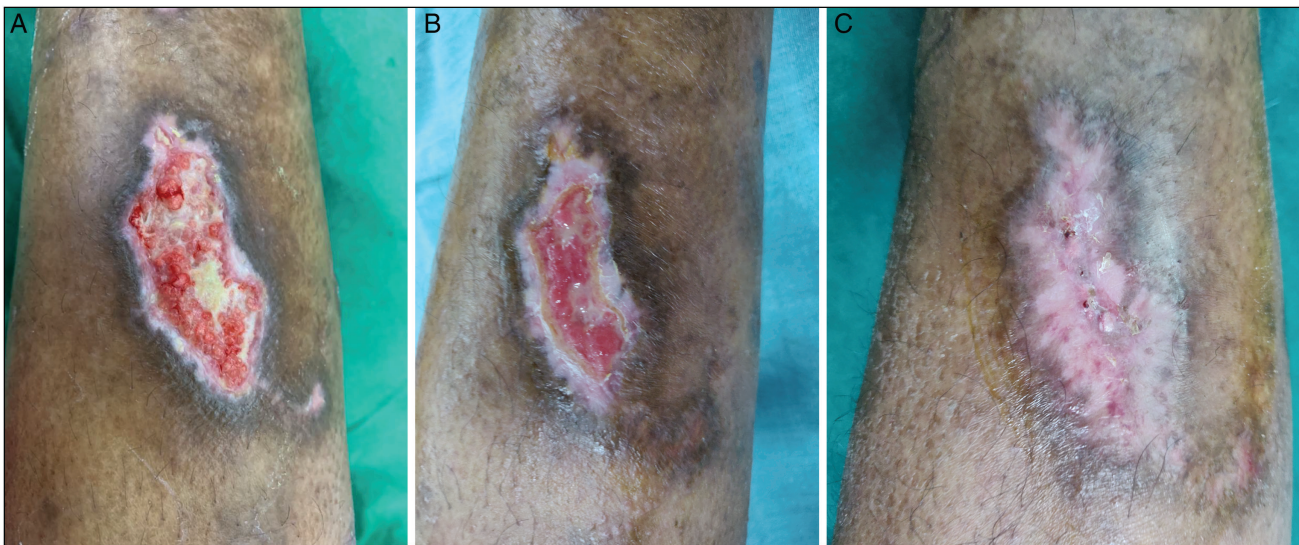

Figure 9: Another healing ulcer: (A) at baseline, (B) on day 7 post-procedure, and (C) at week 4 post-procedure

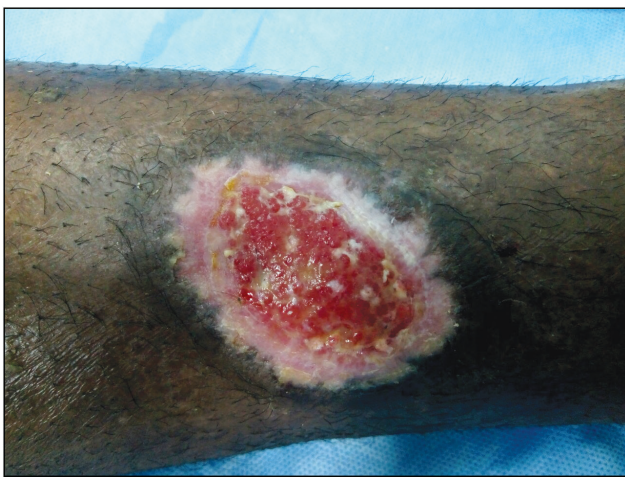

Figure 10: A diabetic ulcer healing with few yellowish pin-head-sized dome-shaped colonies of cells

completely [Figure 10]. Hypertrophic granulation tissue was seen in two of the ulcers, which subsided spontaneously within a week with regular normal

saline dressing. The donor site in all cases showed complete healing by 7 days post-procedure with mild pigmentation. No other adverse effect because of the procedure was noted in any case.

DISCUSSION

Various studies using pure epidermal sheet grafting, cultured keratinocyte grafting, and engineered skin products have emphasized the pivotal role of keratinocytes in wound healing.^[3] Our study was based on the scientific fact that if used in ulcers, ECS may promote migration or multiplication of acceptor keratinocytes and formation of extracellular matrix proteins. A previous study assessing the effectiveness of autologous non-cultured epidermal cell suspension in 15 cases of nonhealing ulcers found a success rate of 60% by 20 weeks post-procedure with 1 case of failure of therapy.^[4]

Collagen and hair follicular stem cells found in dermal follicular grafts have been shown to initiate fibroblast formation and endothelial migration, as well as capillary

sprouting, respectively, when implanted into ulcer tissue.^[5,6] Budamakuntla *et al.*^[7] evaluated the use of autologous scalp hair follicular unit grafts in chronic ulcers and found a mean percentage improvement in ulcer area and volume of 48.8% and 71.98%, respectively, at 18 weeks post-procedure.

In a prior study, Nagaraju *et al.*^[8] used autologous smashed dermal graft in acne scars and reported favorable results with neocollagenesis. The modification to use autologous follicular dermal grafts in our study was based on the fact that it would also make the follicular stem cells available for faster wound healing. However, this is the first study to our knowledge using autologous smashed follicular dermal graft with ECS in nonhealing ulcer.

There are many beneficial effects of combining autologous ECS and smashed dermal follicular grafts. The ratio of donor-to-recipient skin area required is significantly reduced compared to conventional skin grafts. There is no requirement of absolute immobilization for the patient. The smashed dermal graft is also soft and easily moldable, and thus it can be tailored to cover any ulcer irrespective of its shape and size. Finally, this method is cost-effective and safe with only minimal scarring of donor area resulting in good cosmetic appearance.

CONCLUSION

This modified technique of combining autologous smashed follicular dermal graft with epidermal cell suspension can be an effective, simple, time-saving, and affordable modality of treatment for chronic nonhealing leg ulcers.

Financial support and sponsorship

Nil.

Conflicts of interest

There are no conflicts of interest.

REFERENCES

1. Reichenberg J, Davis M. Venous ulcers. *Semin Cutan Med Surg* 2005;24:216-26.
2. Brown JB, McDowell F. Epithelial healing and the transplantation of skin. *Ann Surg* 1942;115:1166-81.
3. Yamaguchi Y, Kubo T, Tarutani M, Sano S, Asada H, Kakibuchi M, *et al.* Epithelial-mesenchymal interactions in wounds: treatment of palmoplantar wounds by nonpalmoplantar pure epidermal sheet grafts. *Arch Dermatol* 2001;137:621-8.
4. Shukla VK, Tiwary SK, Barnwal S, Gulati AK, Pandey SS. Effect of autologous epidermal cell suspension transplantation in chronic nonhealing wounds: a pilot study. *Can J Surg* 2010;53:6-10.
5. Lough DM, Yang M, Blum A, Reichensperger JD, Cosenza NM, Wetter N, *et al.* Transplantation of the LGR6+ epithelial stem cell into full-thickness cutaneous wounds results in enhanced healing, nascent hair follicle development, and augmentation of angiogenic analytes. *Plast Reconstr Surg* 2014;133:579-90.
6. Mian M, Beghè F, Mian E. Collagen as a pharmacological approach in wound healing. *Int J Tissue React* 1992;14:1-9.
7. Budamakuntla L, Loganathan E, Sarvajnamurthy SA, Nataraj HV. Follicular unit grafting in chronic nonhealing leg ulcers: a clinical study. *J Cutan Aesthet Surg* 2017;10:200-6.
8. Nagaraju U, Chikkaiah MK, Raju BP, Agarwal P. Autologous smashed dermal graft with epidermal re-closure: modified technique for acne scars. *J Cutan Aesthet Surg* 2016;9:258-62.