

Congenital Fibrosarcoma of the Chest Wall: Report of a Case

Congenital fibrosarcoma (CFS) is a rare soft tissue tumour that usually occurs before the age of 1, and involves the distal extremities. The literature regarding the precise diagnosis and treatment of these tumours is limited. We present and discuss a case of CFS which ended fatally due to lung metastasis after 2 years.

KEYWORDS: Chest walls, children, congenital fibrosarcoma, tumours

INTRODUCTION

Chest wall tumours are rare among infants, and only 1.8% of solid tumours in children occur in the chest. Very few of them are congenital fibrosarcoma (CFS).^[1] CFS is the soft tissue sarcoma (STS) of which only 60 cases are documented as congenital.^[2,3] Thus, because of rarity of cases and lack of clinical experience, diagnosis and treatment are challenging. CFS is known for its properties of extensive local invasion, but rare distant metastasis. Distal extremities are the usual location of involvement.^[1,4,5] The chest wall has been mentioned as the location for CFS only rarely.^[1] Prognosis of CFS of the chest wall is poorer when compared to CFS of distal extremities.^[1,6] Here, we report a case of a large CFS of the chest wall.

CASE REPORT

A full-term male infant born by normal vaginal delivery was referred to our department from the nursery attached to the obstetric department of our hospital, with a large mass arising from the left lateral surface of the chest wall. His birth weight was 3250 g and the Apgar score at 1 and 5 min was 8 and 9, respectively. On examination, a 10 × 10 cm solid, lobulated, non-tender

mass was found arising from the region of the left lateral chest wall lateral to the left areola and below the axilla [Figure 1]. It was not fixed to the chest wall and was mobile in all directions.

A complete blood picture was significant only for leucocytosis (18,400cells/mm³). The chest radiograph did not show any bone deformity. The ultrasonogram (USG) showed it to be a hypoechoic solid mass. USG of the abdomen was normal. A wide local excision was done under general anaesthesia. An incision was given around the tumour taking adequate margins. A plane was easily developed between the tumour and the chest wall by blunt and sharp dissection. An area of skin directly covering the tumour was removed along with it. A mini-vacuum drain was left in the area and the wound closed in a single layer with Nylon 3-0 suture. Grossly, the tumour was well circumscribed, with the cut section showing multiple areas of haemorrhages and necroses [Figure 2]. Microscopically, it revealed bundles of connective tissue and fibroblast cells in fascicles [Figure 3] with mitotically active tumour cells that also showed nuclear pleomorphism. The margins of resection were free of tumour. The tumour was positive for vimentin and actin, and negative for S-100. A diagnosis of CFS of low-grade malignancy was confirmed on histopathology.

The immediate post-operative period was uneventful. From the age of 6 months to 2 years, the child had multiple episodes of upper respiratory infections. He succumbed to multiple lung metastases after 2 years.

DISCUSSION

CFS is a rare soft tissue tumour that accounts for 9.5% of

Access this article online	
Quick Response Code: 	Website: www.jcasonline.com
	DOI: 10.4103/0974-2077.74497

Shilpi Singh Gupta, Onkar Singh, Shashi Shankar Sharma¹, Raj Kumar Mathur

Department of Surgery and ¹Division of Pediatric Surgery, MGM Medical College and MY Hospital, Indore, Madhya Pradesh, India

Address for correspondence:

Dr. Shilpi Singh Gupta, VPO Sangowal, Nakodar, Jalandhar – 144 041, Punjab, India. E-mail: drguptashilpi@gmail.com

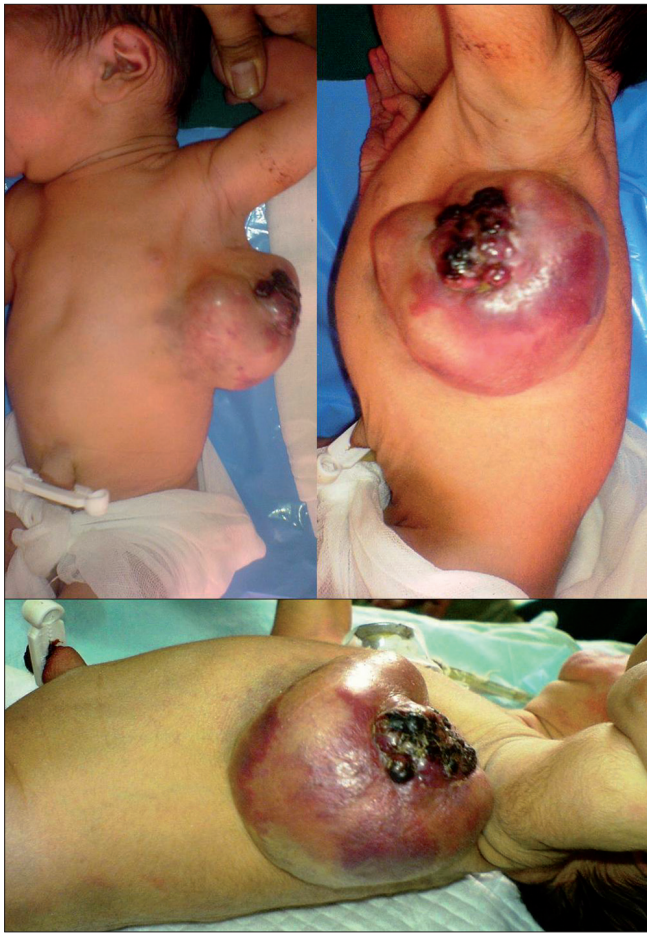

Figure 1: Different views of a large lobulated (about 10 × 10 cm) mass located in the left lateral chest wall region (lateral to the left areola and just below the axila), in a full-term male newborn

all congenital lesions and 3% of childhood tumours.^[7-9] In children, under the age of 15, CFS is responsible for 40% of STS. Its prevalence in children aged under 5 and of perinatal period is >50% and >33%, respectively.^[8] Thus, actually, it is the most common STS among children under 1 year of age.^[10] CFS is a tumour with a limited biological activity. The phenotype, survival rate and recurrence rate of CFS are not fully known due to small number of truly congenital cases on record and thus very few published series.^[11] During last 40 years, there have been only two major published series. Chung and Enzinger^[4] recorded 53 cases with 20 congenital tumours. Soule and Pritchard^[5] performed a review of 110 cases with 36% incidence of CFS. The most frequent tumours of the chest wall are the malignant small round cell tumours (Ewing's sarcoma/primitive neuroectodermal tumour [PNET] family) followed by rhabdomyosarcoma, osteosarcoma, chondrosarcoma and a spectrum of other sarcomas.^[12] Over last 40 years, only about 60 cases of CFS have been documented to be congenital.^[2,3] The chest wall tumours are rare occurrences in infants,^[12] and the chest wall as the site of origin for CFS has been very rarely mentioned.^[1]

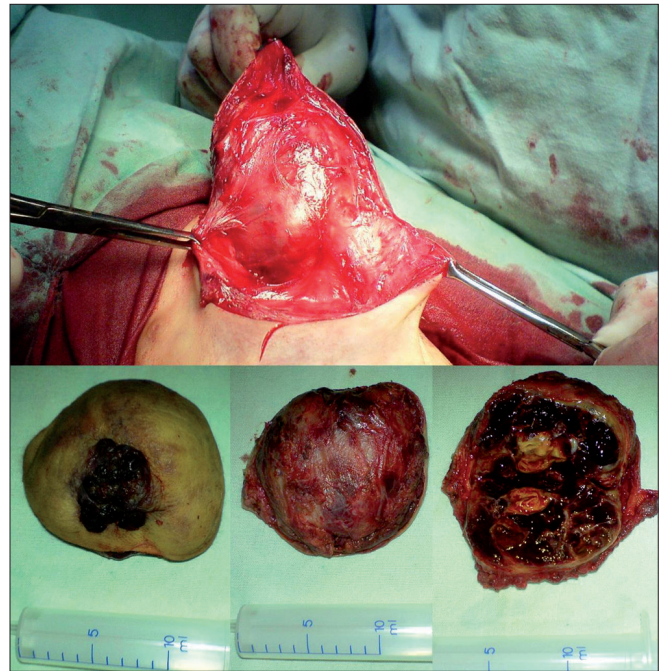


Figure 2: Intraoperative photographs (showing no gross deep invasion of the chest wall), and photographs of the removed specimen including the cut section showing multiple areas of haemorrhages and necroses

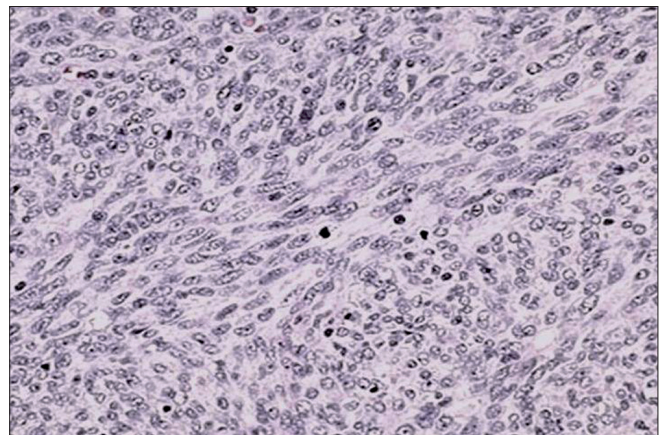


Figure 3: Histopathological slide showing bundles of connective tissue and fibroblast cells in fascicles

The most common location of occurrence is the extremities (71%), especially lower.^[4,6-8] CFS may also be located in the trunk, head and neck, retroperitoneum and mesentery.^[4,13] Head and neck involvement is particularly commoner in older children. Other rare sites of origin include mouth, intestine, lung, abdominal wall and thigh.^[1-3,14,15] It has also been diagnosed during pregnancy and in a fetus.^[2,16]

Pathologically, CFS is a spindle cell tumour, with cells arranged in bundles or fascicles (c/f with a herring bone pattern in adult fibrosarcoma).^[15] There is a high degree of cellularity, rapid growth and extensive local invasion

found.^[14,17,18] Multinucleated giant cells are rare and the cellular activity changes from one area to another. Tumour cells are diffusely positive for vimentin, and may show focal positivity for actin but are negative for S100, desmin and myoglobin.^[15] Compared with adult fibrosarcoma, CFS has slower growth rate and better prognosis.^[15,17] Metastases are rare and occur mostly in the lungs, bones and sometimes in lymph nodes.^[1,8,10,14,17,18] Local recurrence is rather a commoner phenomenon and occurs in 20–40% of cases.^[4,8,14,17,18] CFS of the axial sites and extremities has a similar tumour recurrence rate, but former has higher metastases and mortality rates (26% vs. 10%).^[14] The rate of distant metastases depends on tumour location, and is 8% for CFS of the extremities with a mortality of 5%, compared with 26% metastasis and mortality rates of CFS of the axial location.^[6] The 5-year survival is between 84% and 93%.^[1]

Radiographically, the most common finding is the presence of a soft tissue mass that has grown rapidly. The bone may show curvature, cortical thickening and/or destruction. A computerized tomography (CT) scan shows tumour extension and bone involvement.^[7] Magnetic resonance imaging (MRI) shows soft tissues and neurovascular involvement. Nuclear scintigraphy ^{99m}Tc methylendiphosphonate can show an increased activity in the underlying bone when bony metastases are suspected.^[7]

The differential diagnosis includes soft tissue sarcomas like spindle cell rhabdomyosarcoma, synovial sarcoma and infantile hemangiopericytoma, and the cellular form of childhood fibromatosis must be ruled out, as these tumours show more invasive behaviour.^[10] The microscopic appearance of these neoplasms is similar, but the uniformity of tumour cells, the pattern of growth, distribution in bundles, and immunohistochemistry allow the diagnosis of CFS.^[9,19]

CFS is a low-grade neoplasm^[10] with a benign pattern^[14,16] which has a good prognosis following treatment.^[17] Wide surgical excision (WSE) is the initial treatment, and usually sufficient for chest wall lesions.^[1,5] WSE provides good results when the surgical margins are free of tumour. For CFS of the extremities, the treatment option that provides best results is the total surgical excision (TSE), which is mostly effective. But, rarely amputation may also be required as a part of curative treatment.^[8,10] However, amputation should be reserved for cases that are resistant to chemotherapy, and in whom the involvement of neurovascular structures by the tumour makes limb salvage and removal of the tumour impossible.^[20] Chemotherapy including vincristine (Oncovin), doxorubicin (adriamycin) and cyclophosphamide (Cytosan) VAC is used when the lesion is unresectable, before surgery to shrink the

tumour and allow limb-sparing surgery, and after incomplete surgery.^[7,21,22] Besides, the cases in which surgical excision had not been curative, chemotherapy had shown response. Chemotherapy may also improve the results of WSE,^[23] and it has been seen that it avoids amputation.^[20] Recently, Demir *et al.*^[24] were able to successfully treat a newborn with CFS of the right foot that had destroyed all tarsals, metatarsals and phalangeal bones, with only VAC-based chemotherapy. Spontaneous regression has also been reported in some neonatal and pediatric cases of CFS. Madden *et al.*^[22] reported the case of a 2-week-old male neonate with CFS of the forearm that regressed by the age of 7 months without any treatment. Miura *et al.*^[3] more recently described another similar case of an infant with CFS of hand which spontaneously resolved.^[3]

CONCLUSION

CFS is rare, soft tissue, locally aggressive tumour, which presents a diagnostic and therapeutic challenge. While CFS on extremities may have favourable prognosis after complete resection, CFS on rarer axial sites like chest wall carry poorer prognosis.

REFERENCES

1. Parra Gordo ML, Soletto Roncero MJ, Terriza Rueda MD, Marcuello Olona P, Mariño Espuelas JM, Castaño Pascual A. Congenital fibrosarcoma of the chest wall. *An Pediatr (Barc)* 2004;61:565-7.
2. Lam PM, Leung TM, Ng PC, Vlantis AC, Wong W, Lau TK. Congenital cervical fibrosarcoma with hydrops Fetalis. *Acta Obstet Gynecol Scand* 2004;83:773-6.
3. Miura K, Han G, Sano M, Tsutsui Y. Regression of congenital fibrosarcoma to hemangiomatous remnant with histological and genetic findings. *Pathol Int* 2002;52:612-8.
4. Chung EB, Enzinger FM. Infantile fibrosarcoma. *Cancer* 1976;38:729-39.
5. Soule EH, Pritchard DJ. Fibrosarcoma in infants and children: A review of 110 cases. *Cancer* 1977;40:1711-21.
6. Blocker S, Koenig J, Ternberg J. Congenital fibrosarcoma. *J Pediatr Surg* 1987;22:665-70.
7. Vinnicombe SJ, Hall CM. Infantile fibrosarcoma: Radiological and clinical features. *Skeletal Radiol* 1994;23:337-41.
8. Arceci RJ, Weinstein HJ. Neoplasia. In: MacDonald MG, Mullett MD, Seshia MM, editors. *Avery's Neonatology pathophysiology and Management of the Newborn*. 6th ed. Philadelphia: Lippincott Williams and Wilkins; 2005. p. 1455-6.
9. Enzinger FM, Weiss SW. *Soft tissue tumours*. St Louis: Mosby; 1995. p. 231-91.
10. Arndt CA. Soft Tissue sarcoma. In: Behrman RE, Kliegman RM, Jenson HB, editors. *Nelson Textbook of Paediatrics*. 17th ed. Philadelphia: Saunders; 2004. p. 1714-7.
11. Kothari KC, Pandey M, Wadhwa MK, Patel DD. Congenital infantile fibrosarcoma. *Eur J Surg Oncol* 1999;25:94-6.
12. Shamberger RC, Grier HE. Chest wall tumours in infants and children. *Semin Pediatr Surg* 1994;3:267-76.
13. McCarville MB, Kaste SC, Pappo AS. Soft-tissue malignancies in infancy. *AJR Am J Roentgenol* 1999;173:973-7.
14. Okcu MF, Hicks J, Merchant TE. Non-rhabdomyosarcomatous Soft Tissue Sarcomas. In: Pizzo PA, Poplack DG, editors. *Principles and*

- practice of pediatric oncology. 5th ed. Philadelphia: Lippincott Williams and Wilkins; 2006. p. 1055-6.
15. Weiss SW. Congenital and Infantile fibrosarcoma. In: Enzinger FM, Weiss SW, editors. Soft tissue tumours. 4th ed. Missouri: Mosby Elsevier; 2001. p. 377-9.
 16. Kodet R, Stejskal J, Pilat D. Congenital-infantile fibrosarcoma: A clinicopathological study of five patients entered on the prague children's tumour registry. *Pathol Res Pract* 1996;192:845-50.
 17. Luchtman-Jones L, Schwartz AL, Wilson DB. Hematopoietic Problems in the fetus and Neonate. In: Martin RJ, Fanaroff AA, Walsh MC, editors. Fanaroff and Martin's Neonatal Perinatal Medicine: Disease of the fetus and Infant. 8th ed. Philadelphia: Mosby Elsevier; 2006. p. 1343-6.
 18. Rosai J, Ackerman LV. Surgical Pathology. 9th ed. Newyork: Mosby Elsevier; 2004. p. 2253.
 19. Tröbs RB, Meier T, Bennek J, Heinrich S, Willnow U. Fibrosarcoma in infants and children: A retrospective analysis- overdiagnosis in earlier years. *Pediatr Surg Int* 1999;15:123-8.
 20. Kurkchubasche AG, Halvorson EG, Forman EN, Terek RM, Ferguson WS. The role of preoperative chemotherapy in the treatment of infantile fibrosarcoma. *J Pediatr Surg* 2000;35:880-3.
 21. Yalçın B, Leblebicioglu G, Güler E, Gedikoglu G, Kutluk MT. Congenital infantile fibrosarcoma of the thigh in a newborn. *Tumouri* 2001;87:436-8.
 22. Madden NP, Spicer RD, Allibone EB, Lewis JJ. Spontaneous regression of neonatal fibrosarcoma. *Br J Cancer Suppl.* 1992;18:S72-5.
 23. Pousti TJ, Upton J, Loh M, Grier H. Congenital fibrosarcoma of the upper extremity. *Plast Reconstr Surg* 1998;102:1158-62.
 24. Demir HA, Akyuz C, Varan A, Ergen FB, Buyukpamukcu M. Right foot congenital infantile fibrosarcoma treated with chemotherapy alone. *Pediatr Blood Cancer* 2010;54:618-20.

Source of Support: Nil, **Conflict of Interest:** None declared.