

“An Uncanny Kin of the Ingrown Toenail”: Harpoon Nail and the Surgical Challenge in Its Management

Ramesh Sandhiya, Raghavendra Rao

Department of Dermatology, Venereology, and Leprosy, Kasturba Medical College, Manipal Academy of Higher Education, Manipal, Karnataka, India

Abstract

Ingrown toenails result from the painful conflict between the nail plate and the surrounding soft tissues. Ingrowing may be precipitated by improper nail cutting in most instances, and occlusive footwear and trauma, in others. The most common type of ingrown nail is the distal lateral variant. We report a relatively unique and rare case of ingrown nail—the harpoon nail, wherein the distal lateral spur arising from improper and incomplete trimming of the nail, pierced through the distolateral wall until it appeared over the tip of the toe. It is a cause of great morbidity to the patient and this report envisages the need for the correct surgical approach.

Keywords: Harpoon nail, ingrowing toenail, sodium hydroxide

INTRODUCTION

Ingrown toenail (onychocryptosis) is a pathological condition, which most commonly affects the great toenail and damages the nail fold. On the basis of the site of pathology, it is classified into proximal, distal, and lateral types.^[1] The lateral ingrowing toenail is the most common type of ingrown toenail, which is primarily caused by improper nail cutting.^[2] The irregular lateral nail edge or nail spur pierces and gets embedded in the surrounding soft tissue in a notched manner causing lateral and distal bulging with hypertrophy of the nail fold. This may be complicated by secondary bacterial colonization leading to infection. This problem is further aggravated by occlusive footwear, wherein the tip of the toe is constantly compressed against the nail plate. This is a painful condition and causes discomfort due to repeated attacks of acute inflammation and secondary infection.

The staging of lateral ingrown nails is carried out based on clinical findings of erythema, infection, swelling, oozing, and hypertrophy of lateral nail fold, granulation tissue, and pain. The Heifetz severity staging is most widely used. Stage I is characterized by slight erythema and swelling of the nail grooves in the nail bed. Stage II is characterized by the presence of an acute infection and suppuration. Stage III includes chronic infection, formation of

granulation tissue in the nail grooves, and hypertrophy of the surrounding tissues. Hereby, we describe a unique and rare variant of distal lateral ingrowing toenail—the harpoon nail.

CASE REPORT

A 49-year-old woman presented with a 5-month history of painful swelling and occasional pus discharge from the tip of the right great toe. To alleviate the pain and swelling, she had at once blindly clipped her nail at the distal end, underneath the swollen nail fold. Examination revealed a tender enlarged lateral nail fold with the nail plate at the medial end showing a pointed spur at the distolateral end. There was dimpling at the tip corresponding to the direction of the spur [Figure 1A]. No active discharge or granulation tissue was observed. A provisional diagnosis of ingrowing toenail (Heifetz stage 1) was considered.

She was surgically managed with lateral plate avulsion followed by chemical cauterization of the lateral horn

Address for correspondence: Dr. Raghavendra Rao,
Department of Dermatology, Venereology, and Leprosy,
Kasturba Medical College, Manipal Academy of Higher Education,
Manipal 576104, Karnataka, India.
E-mail: jennyrao1@yahoo.com

Access this article online

Quick Response Code:



Website:
www.jcasonline.com

DOI:
10.4103/JCAS.JCAS_99_19

This is an open access journal, and articles are distributed under the terms of the Creative Commons Attribution-NonCommercial-ShareAlike 4.0 License, which allows others to remix, tweak, and build upon the work non-commercially, as long as appropriate credit is given and the new creations are licensed under the identical terms.

For reprints contact: reprints@medknow.com

How to cite this article: Sandhiya R, Rao R. “An uncanny kin of the ingrown toenail”: Harpoon nail and the surgical challenge in its management. *J Cutan Aesthet Surg* 2020;13:142-4.

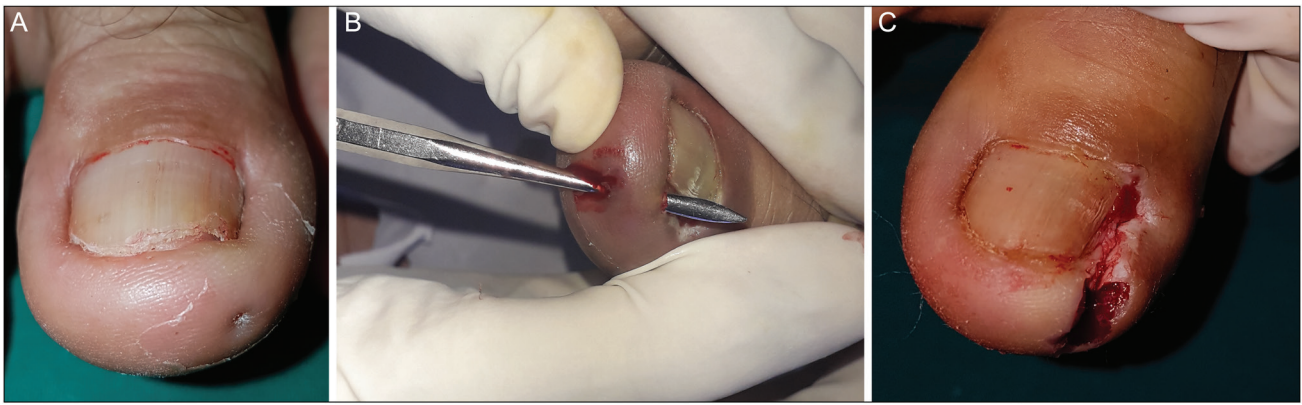


Figure 1: (A) Right great toenail showing the spicule at the distolateral end with the dimple at the tip of the toe. (B) Probing of the dimple leading to the direction of the fistula, where the tip of the probe emerges at the nail bed laterally. (C) Post excision and deroofing of the fistulous tract

of the matrix with 10% sodium hydroxide for 1 min. The fistulous tract was deroofed and completely excised [Figure 1B and C]. The wound healed well following surgery. Follow-up at 4 weeks after surgery was uneventful with complete epithelialization of the wound [Figure 2].

DISCUSSION

The term “harpoon nail” was first coined by Bertrand Richert in 2014.^[1] It is a unique variant of the distal lateral ingrowing nail. It results from a vicious cycle of pain, swelling, and wrong technique of nail clipping. As a result, a spicule is formed, which continues to grow along with the rest of the nail plate. Ultimately, it harpoons through the distolateral wall of the lateral nail groove until it emerges through the tip of the great toe.^[3] This results in the formation of a fistulous tract, which in acute stage manifests with erythematous, edematous swelling with oozing and crusting. The fistulous tract corresponds to the emergence of the spicule through the epidermis in the lateral and distal wall.^[4] The acute form, if left untreated, progresses to the chronic form, where the inflammation resolves and the epithelialization of the fistulous tract takes place. Our patient had presented to us in the chronic stage. The damage caused by that tiny spicule is analogous to the harpoon. The harpoon is an instrument to hunt the marine animals; it has a distal sharp end with a relatively broad base. It was designed to cause maximum damage to the animals, such that the animals get immobilized in pain after being hit by the harpoon. Figure 3 shows the analogy between the nail spicule and the harpoon and the similar pattern in morbidity caused by both.

Surgical treatment is the mainstay of treatment of harpoon nail. It consists of deroofing the canal followed by avulsing the lateral strip of nail plate and chemical destruction of the exposed matrix, as carried out in our

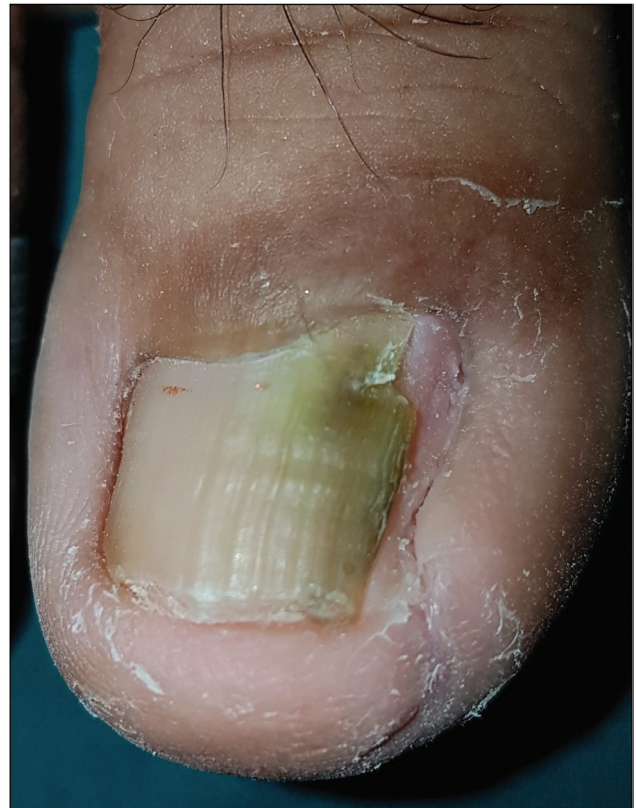

Figure 2: Completely healed wound at 4 weeks post surgery

patient. Follow-up was uneventful with complete healing. Epithelialization of wound occurred within 4 weeks. We used 10% sodium hydroxide as it is equally efficacious as phenol and its recovery time is shorter when compared to phenol.^[5,6]

Other treatment options include a wedge resection of the lateral fold along with the lateral strip and offending spur, the Winograd technique, Vandenbos procedure, or super

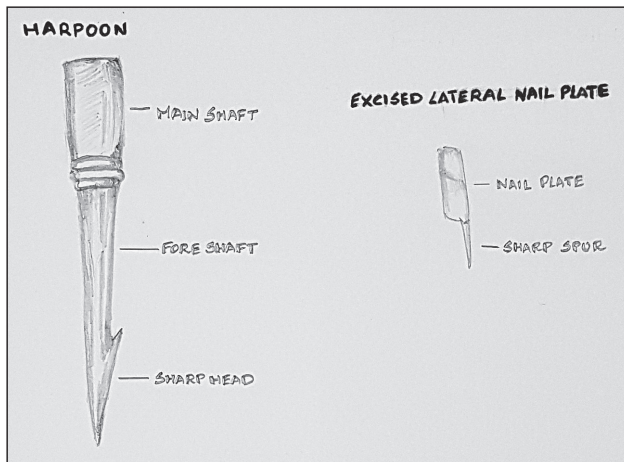


Figure 3: Analogy between the “harpoon” and the excised nail plate with the offending sharp spicule

U that debulks all the periungual soft tissues and exposes the spicule.^[1,4] The Vandembos procedure is, however, associated with prolonged postoperative morbidity and healing time.

Declaration of patient consent

The authors certify that they have obtained all appropriate patient consent forms. In the form the patient(s) has/have given his/her/their consent for his/her/their images and other clinical information to be reported in the journal.

The patients understand that their names and initials will not be published and due efforts will be made to conceal their identity, but anonymity cannot be guaranteed.

Financial support and sponsorship

Nil.

Conflicts of interest

There are no conflicts of interest.

REFERENCES

1. Richert B, Chiacchio ND, Caucanas M, Chiacchio NGD. Definition—Pathogenesis risk factors—classification—scoring. In: Betrand R, editor. Management of ingrowing nails. 1st ed. Basel, Switzerland: Springer International Publishing; 2016. pp. 35-58.
2. Savant SS. Nail surgery. In: Savant SS, editor. Textbook of dermatosurgery and cosmetology. 2nd ed. Mumbai, India: ASCAD; 2005. pp. 238.
3. Haneke E. Controversies in the treatment of ingrown nails. *Dermatol Res Pract* 2012;2012:1-12.
4. Richert B, Caucanas M, Di Chiacchio N. Surgical approach to harpoon nail: a new variant of ingrowing toenail. *Dermatol Surg* 2014;40:700-1.
5. Bostanci S, Kocyigit P, Gürgey E. Comparison of phenol and sodium hydroxide chemical matricectomies for the treatment of ingrowing toenails. *Dermatol Surg* 2007;33:680-5.
6. Kocyigit P, Bostanci S, Ozdemir E, Gürgey E. Sodium hydroxide chemical matricectomy for the treatment of ingrown toenails: comparison of three different application periods. *Dermatol Surg* 2005;31:744-7; discussion 747.