

Successful Treatment of Recalcitrant Bowen's Disease of the Lower Back Using a Bimodal Approach

Dear Editor,

Bowen's disease (BD) is basically squamous cell carcinoma *in situ*, which if not adequately managed may develop into invasive carcinoma. Multiple therapeutic options are available for managing BD. The treatment option chosen depends on the availability, patient preference, clinical circumstance, and the expertise of the clinician with respect to that particular modality of treatment instituted. It has also been seen that a patient not responding to a particular form of treatment may respond fairly well to another form of treatment, and a combination of two or more treatment modalities in such cases may complement one other, thus facilitating a quicker resolution and allowing better patient compliance.

My patient was a 61-year-old gentleman who presented with a discolored, firm, nontender plaque of size 8 × 7 cm over the lower back [Figure 1] since the past 8 months. It was a tiny lesion to begin with, that had gradually progressed to attain the current status. Associated symptoms of tingling and burning were present over the lesion. Previous treatment included topical usage of 5% imiquimod cream for a period of 16 weeks with no significant improvement. An incisional biopsy from the lesion revealed complete epidermal dysplasia, with keratinocytes demonstrating nuclear atypia and the classic wind-blown appearance [Figures 2 and 3], which confirmed the diagnosis of BD. After counseling the patient with regard to the available treatment modalities and obtaining an informed consent, the lesional site was

ablated utilizing carbon dioxide (CO₂) laser at 10-Hz frequency in the super-pulsed mode, including 5-mm margins of the surrounding normal skin till pinpoint bleeding spots were obtained [Figure 4]. A review after 6 weeks demonstrated good reepithelialization of the lesion [Figure 5]. However, a smoldering pain still persisted at the lesional site. A rebiopsy from the lased site demonstrated the presence of a few atypical cells in and around the adnexa. Taking this into consideration, 5-fluorouracil (5-FU) was instilled into the lesion, after dividing it into four quadrants with 2 mL of 5-FU being injected into each quadrant. The patient was regularly followed up at monthly intervals. Surprisingly, after intralesional instillation of 5-FU, there was complete disappearance of pain, which the patient had earlier complained about. With each review, the lesion demonstrated improvement in color and texture, gradually blending with the surrounding skin [Figures 6-8]. A biopsy performed after 12 months showed no evidence of BD. The patient was reassured.

CO₂ laser has been a very effective treatment modality for treating cutaneous premalignant conditions. However, its beneficial effects are limited to the epidermis and superficial dermis.^[1] With laser injury penetrating deeper, unacceptable cosmesis is unavoidable.^[2] Therefore, to counteract this, intralesional instillation of cytotoxic agents could prove beneficial. 5-FU has been employed as an intralesional agent in managing

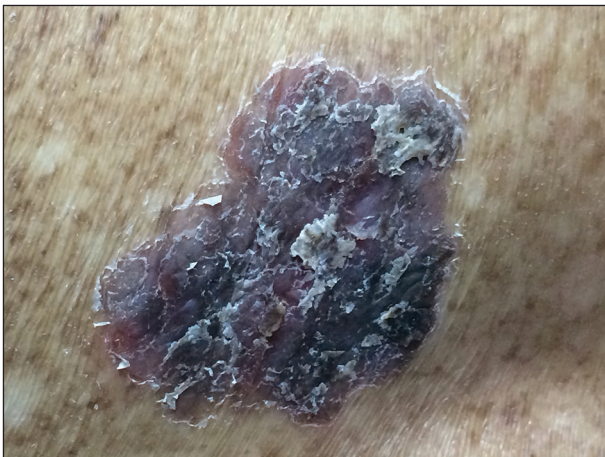


Figure 1: A hyperpigmented, well-defined scaly plaque of size 8 × 7 cm over the lower back

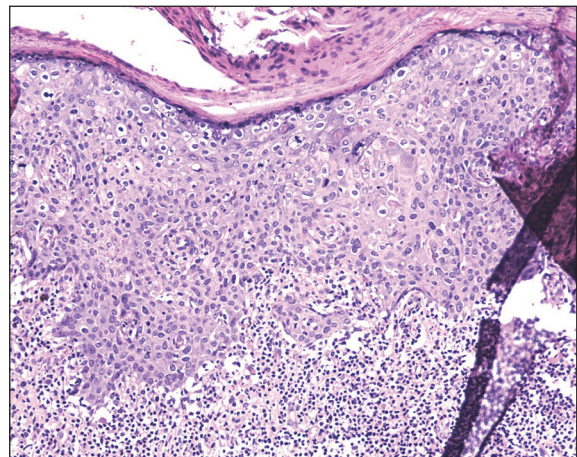


Figure 2: Section of the skin showing epidermal disarray of keratinocytes, which demonstrate the characteristic wind-blown appearance [hematoxylin and eosin (H&E) ×10]

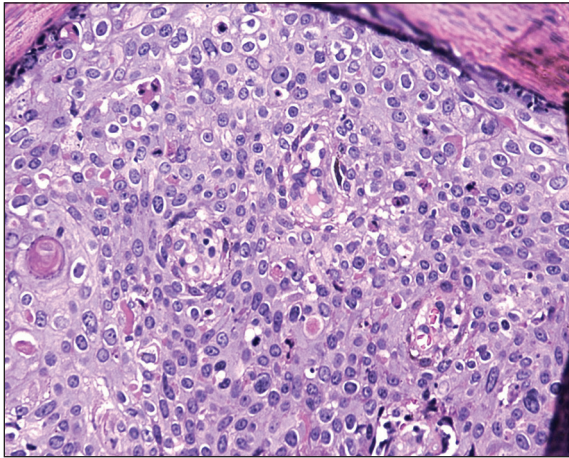


Figure 3: Section of the skin highlighting the nuclear atypia in the keratinocytes (H&E $\times 20$)

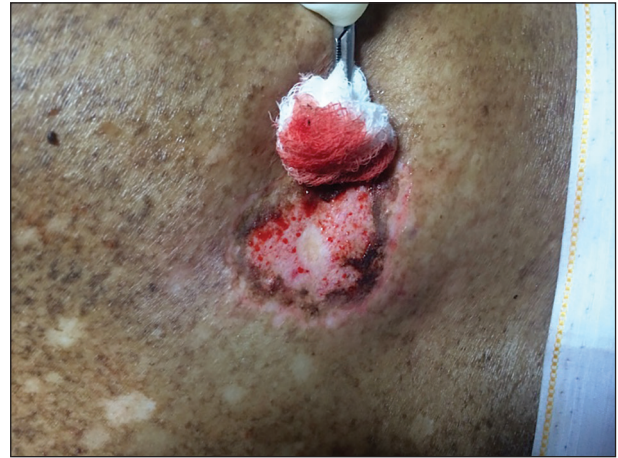

Figure 4: Pinpoint hemorrhages indicating the end point of CO₂ laser treatment

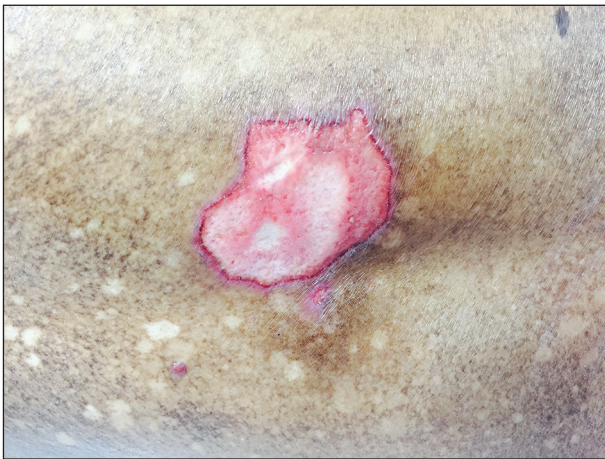

Figure 5: Lesion 6 weeks after CO₂ laser ablation

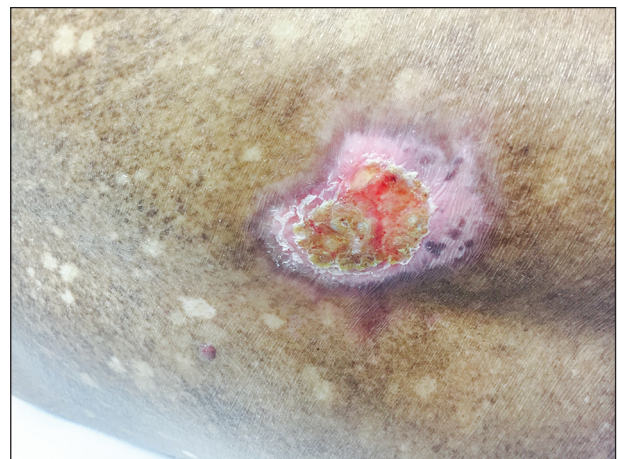

Figure 6: Re-epithelialization of the lesion with central crusting seen after 1 month of intralesional 5-fluorouracil (5-FU) instillation

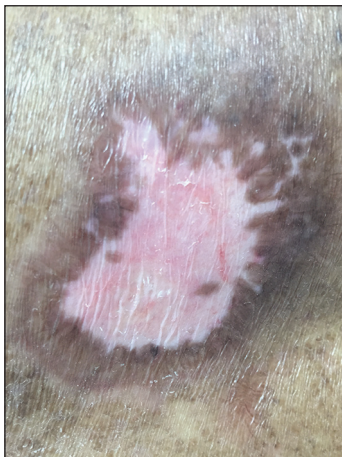


Figure 7: Condition of the patient 5.5 months after the first visit. It is to be noted here that there was complete healing of the skin with areas of dyspigmentation in that area

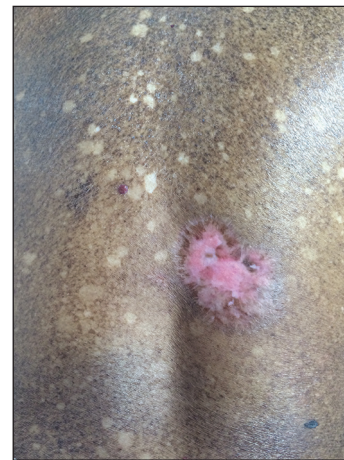

Figure 8: Status of the lesion after 1 year of follow up

cutaneous neoplasms. 5-FU is a pyrimidine antagonist specifically targeting thymidylate synthetase, and disrupting DNA synthesis in mitotically active cells.^[3] In

these patients 5-FU is injected every week for a period of 6-8 weeks. The major disadvantage of this schedule is the unpractical nature of the procedure in lesions $>5 \times$

5 cm in size and the painful quality of the procedure.^[4,5] In such cases, it would be prudent to combine two treatment modalities, thus facilitating a good therapeutic outcome. In this case, the superficial pathology was dealt with CO₂ laser and the deeper remnant with 5-FU, one session of each, thus avoiding multiple painful sessions of intralesional 5-FU. The author feels that in dealing with larger lesions of Bowen's disease, this combination approach would be useful as immediately post CO₂ laser ablation, the patient is able to decipher visible changes in his/her lesion thereby heralding a better adherence to therapy, avoidance of multiple painful sessions of 5-FU injections, and above all a better therapeutic outcome.

Acknowledgement

I would like to thank Dr. Poornima ARC and Dr. Sindhu, residents of the Department of Dermatology, Sri Ramachandra University, Chennai, Tamil Nadu, India for helping me in clinical photography.

Financial support and sponsorship

Nil.

Conflicts of interest

There are no conflicts of interest.

Aditya Kumar Bubna

Department of Dermatology,
Sri Ramachandra University, Chennai, Tamil Nadu, India.
E-mail: zimbabwa21@gmail.com

REFERENCES

1. Fader DJ, Lowe L. Concomitant use of a high-energy pulsed CO₂ laser and a long-pulsed (810 nm) diode laser for squamous cell carcinoma *in situ*. *Dermatol Surg* 2002;28:97-100.
2. Olbricht SM, Stern RS, Tang SV, Noe JM, Arndt KA. Complications of cutaneous laser surgery. A survey. *Arch Dermatol* 1987;123:345-9.
3. Longley DB, Harkin DP, Johnston PG. 5-Fluorouracil: Mechanisms of action and clinical strategies. *Nat Rev Cancer* 2003;3:330-8.
4. Morse LG, Kendrick C, Hooper D, Ward H, Parry E. Treatment of squamous cell carcinoma with intralesional 5-fluorouracil. *Dermatol Surg* 2003;29:1150-3.
5. Miller BH, Shavin JS, Coggnetta A, Taylor JR, Salasche S, Korey A, *et al*. Nonsurgical treatment of basal cell carcinomas with intralesional 5-Fluorouracil/epinephrine injectable gel. *J Am Acad Dermatol* 1997;36:72-7.

This is an open access article distributed under the terms of the Creative Commons Attribution-NonCommercial-ShareAlike 3.0 License, which allows others to remix, tweak, and build upon the work non-commercially, as long as the author is credited and the new creations are licensed under the identical terms.

Access this article online

Quick Response Code:



Website:
www.jcasonline.com

DOI:
10.4103/0974-2077.172208

How to cite this article: Bubna AK. Successful treatment of recalcitrant Bowen's disease of the lower back using a bimodal approach. *J Cutan Aesthet Surg* 2015;8:245-7.