

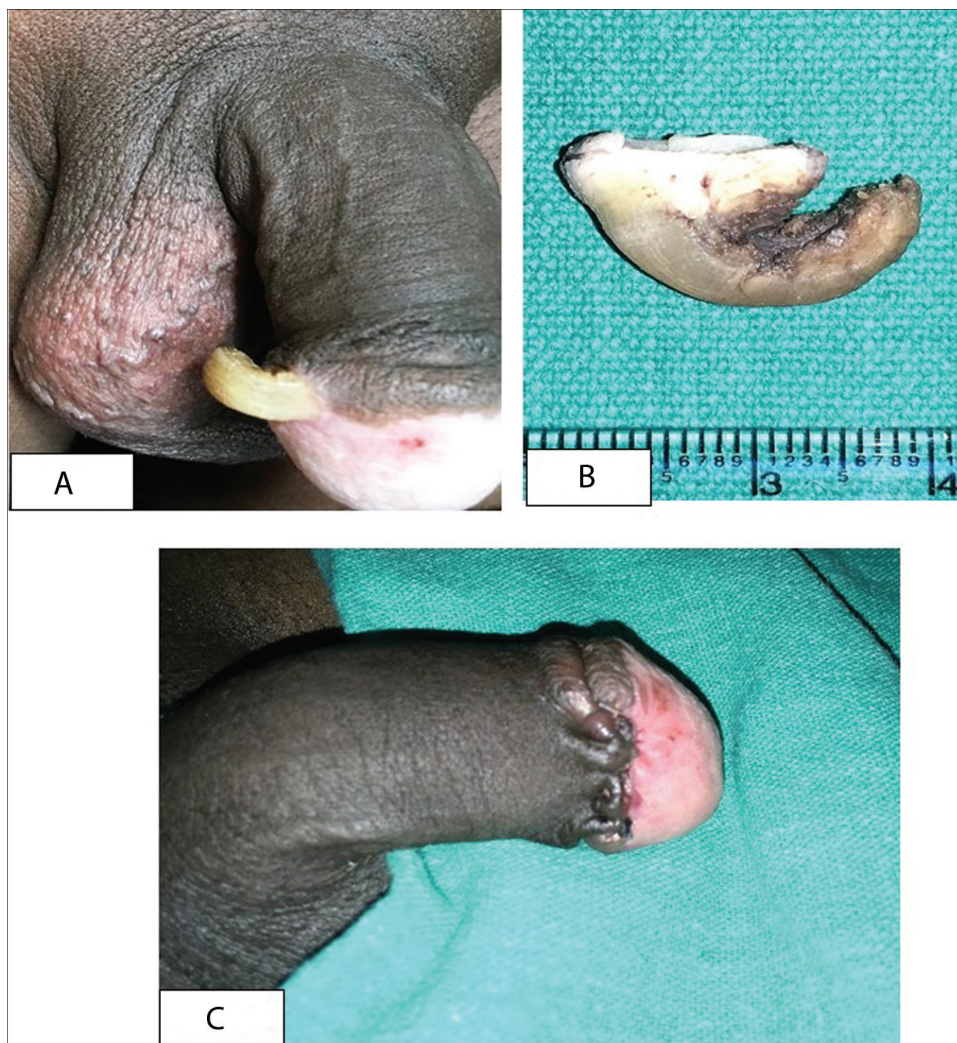
## Cutaneous Horn Over Penis: A Rare Case Report

To the editor

Cutaneous horn is also known as cornu cutaneum, and less commonly as cornu cutaneum of Rokitansky, after the German pathologist Baron Carl von Rokitansky.<sup>[1]</sup> Morphologically, it is described as a hard, conical, dense, and hyperkeratotic protrusion, resembling horn of an animal.<sup>[2]</sup> The incidence of penile cutaneous horn has been particularly low since the first case was reported as early as 1854. Its occurrence on penis is rare with near about 150 reported cases in English literature till date.<sup>[3]</sup>

A 50-year-old male presented with a painless growth over the glans penis for 8 months. Patient had undergone circumcision for phimosis 1 year back and subsequently

identified a yellow lesion projecting from right aspect of glans penis. Examination of the patient revealed a  $2.5 \times 1.0 \times 0.5$  cm curved conical projection over glans penis [Figure 1A]. It was nontender, rough, and hard to touch. There was no induration over glans, and there was no inguinal lymphadenopathy. Routine investigations were normal, including VDRL and HIV tests. The clinical diagnosis was penile cutaneous horn. Surgical excision of the growth with a rim of normal tissue around the base was performed and primary closure was achieved [Figure 1B, C]. Histological examination of the growth revealed marked hyperkeratosis, irregular acanthosis, and papillomatosis of the epidermis. There were no foci of dysplasia or carcinoma. There was no recurrence after 1 year of follow-up.



**Figure 1:** (A) Conical projection over glans penis. (B) Excised penile cutaneous horn. (C) Postoperative picture of penis

Cutaneous horns are seen commonly on sun-exposed areas. Penile cutaneous horn is very rare.<sup>[3]</sup> It is a clinical diagnosis in which horn-like projection composed of compacted keratin is seen above the surface of the skin. Most of the reported cases are in males after 50 years.<sup>[4]</sup> They present as elongated, keratinous, white or yellowish projections arising from the glans penis. Their size ranges from a few millimeters to centimeters.<sup>[4]</sup> They are usually asymptomatic and nontender.<sup>[4]</sup>

Apart from human papillomavirus (HPV) infection, etiology can be classified into benign (warts, seborrheic keratitis, molluscum contagiosum, and inverted follicular keratosis), premalignant (Bowen's disease and solar keratosis), and malignant (basal cell carcinoma, squamous cell carcinoma, and Kaposi sarcoma). Phimosis, chronic irritation, and surgical trauma predispose to penile horn.<sup>[4,5]</sup> A malignant lesion has been reported at the base of cutaneous horn in up to 16–20% of lesions. Squamous cell carcinoma is the most common type of malignancy.<sup>[5]</sup> Histopathology helps in deciding the definitive treatment.

Magnetic resonance imaging (MRI) is useful to diagnose the status of infiltration in preoperative period.<sup>[3]</sup>

Surgical excision with careful histological examination is the preferred mode of treatment. The base of the penile lesion needs to be carefully examined to rule out any associated malignancy.<sup>[5]</sup> Partial penectomy with or without regional lymph node dissection is done in malignant cases.<sup>[5]</sup> Other methods include laser therapy and administration of keratolytic agents.<sup>[3]</sup>

Penile horn is a morphological curiosity. A representative biopsy with careful histopathology examination helps in the appropriate management of penile cutaneous horn.

### Declaration of patient consent

The authors certify that they have obtained all appropriate patient consent forms. In the form the patient(s) has/have given his/her/their consent for his/her/their images and other clinical information to be reported in the journal. The patients understand that their names and initials will not be published and due efforts will be made to conceal their identity, but anonymity cannot be guaranteed.

### Financial support and sponsorship

Nil.

### Conflicts of interest

There are no conflicts of interest.

Prathamesh Chandrapattan, Suma Devaraj<sup>2</sup>, Tim Houghton, Amitabh Jena, Rashmi Patnayak<sup>1</sup>

Departments of Surgical Oncology and

<sup>1</sup>Pathology, IMS & SUM Hospital, Bhubaneswar,

<sup>2</sup>Department of Paediatrics, Indira Gandhi Institute of Child Health, Bangalore, Karnataka, India.

**Address for correspondence:** Amitabh Jena,

Department of Surgical Oncology, IMS & SUM Hospital, Bhubaneswar, Odisha, India.

E-mail: dramitabh2004@yahoo.co.in

### REFERENCES

1. Durkee S. Human horn (cornu cutaneum of Rokitansky). *Boston Med Surg J* 1866;74:9-11.
2. Bondeson J. Everard home, john hunter, and cutaneous horns: A historical review. *Am J Dermatopathol* 2001;23:362-9.
3. Pal D, Pal DK. Penile cutaneous horn. *Urol Ann* 2020;12:80-2.
4. Karthikeyan K. Penile cutaneous horn: An enigma-newer insights and perspectives. *Indian J Sex Transm Dis AIDS* 2015;36:26-9.
5. Wang Y, Tu MQ, Li XJ, Fu Q, Shi GW. Penile cutaneous horn: A rare case report and review of the literature. *Asian J Androl* 2018;20:407-8.

This is an open access journal, and articles are distributed under the terms of the Creative Commons Attribution-NonCommercial-ShareAlike 4.0 License, which allows others to remix, tweak, and build upon the work non-commercially, as long as appropriate credit is given and the new creations are licensed under the identical terms.

For reprints contact: reprints@medknow.com

Access this article online	
Quick Response Code:	Website: www.jcasonline.com
	DOI: 10.4103/JCAS.JCAS_99_20

**How to cite this article:** Chandrapattan P, Devaraj S, Houghton T, Jena A, Patnayak R. Cutaneous horn over penis: A rare case report. *J Cutan Aesthet Surg* 2021;14:454-5.