

Upper Forehead Skin Reconstruction with H-Flap

Introduction: There are several options for forehead defect's reconstructions, including different local flaps, regional flaps, free flaps and skin grafts. We used double opposing rectangular advancement flaps (H-flap) in the upper forehead defects. **Materials and Methods:** This is a prospective case series study that has done in Plastic surgery ward. Of the 10 patients, six were women and four were men, their median age was 61 years (range 50-79 years). Mean follow-up of patients were 15 months and there was no recurrence during this time. We reconstructed forehead after excision of tumours in the same operation. **Results:** Aesthetic results of H-flap in all cases were great with patient satisfaction according to questionnaire sheets. **Conclusion:** This local flap is a reliable and safe way for upper forehead defects up to 6 cm lengths. Long-term follow up showed inconspicuous scars and good texture and colour match of the reconstructed forehead. We recommend this flap for upper forehead reconstruction in defects between 4 cm and 6 cm. Directions of incisions are parallel to resting skin tension line and length to width of flap considered 2:1 with excision of burrow triangle from both side. We used silicon sheet post operatively for 3 months for better aesthetic results.

KEYWORDS: Defects, forehead reconstructions, H-flap, tumours

INTRODUCTION

There are several options for forehead defects reconstructions: Reconstructive options range from healing by secondary intention to primary closure, skin grafts, local flaps, regional flap or any combination of these techniques.^[1] We used double opposing rectangular advancement flaps in the upper forehead defects and found this local flap is related with high patient satisfaction and low complication. Soft tissue reconstruction of the forehead and temple challenges facial plastic surgeons to balance aesthetic goals with functional concerns. Understanding the muscular and neurovascular anatomy is essential to achieve these ends.^[1]

MATERIALS AND METHODS

In this survey, we included 10 cases of upper forehead

carcinoma including six basal cell carcinoma and four squamous cell carcinoma without bone involvement or cervical lymphadenopathy. This flap can be done under local or general anaesthesia in older patients who have skin malignancy in this part of face.

After excision of tumours with safe margins (5-8 mm) according to pathologic frozen section confirmation, defects were reconstructed with H-flap. H-flap involves developing two horizontal rectangular flaps of similar size and shapes that synchronously advance into the skin defects; directions of incisions are parallel to resting skin tension line and length to width of flap considered 2:1. In addition with simultaneous repair of defects with this flap, donor site morbidity for graft harvesting is omitted. This local flap is reliable and safe way for upper forehead defects up to 6 cm lengths. Criteria for choosing this flap for forehead reconstruction were: Tumours in upper middle or lateral portion of the forehead, defect size between 4 cm and 6 cm, no bone involvement, vertical scar in upper forehead and or patients with history of radio dermatitis in the forehead weren't suitable for this flap. This is a prospective case series study that has done in plastic surgery ward of our hospital between May 2010 and January 2012. The 10 patients, were studied that

Access this article online	
Quick Response Code:	Website: www.jcasonline.com
	DOI: 10.4103/0974-2077.118415

Ali Ebrahimi, Nasrin NejadSarvari¹

Departement of Plastic Surgery and Trauma Research Center, Baqiyatallah University of Medical Sciences, ¹Imam Khomeini Hospital, Tehran University of Medical Sciences, Tehran, Iran

Address for correspondence:

Dr. Ali Ebrahimi, Departement of Plastic Surgery and Trauma Research Center, Baqiyatallah University of Medical Sciences, Tehran, Iran. E-mail: ae_49341@yahoo.com

Table 1: Characteristics of ten patients with forehead skin tumours that were reconstructed wide H-Flap

Age	Sex	Type of tumour	Surgical margin (mm)	Location of tumour	Morbidity	Size of tumour cm
50	F	Bcc	6	Middle	-	2.3
53	F	ScC	8	Lateral	-	1.5
60	F	Bcc	5	Middle	-	2
55	F	Bcc	8	Lateral	-	2.5
60	M	ScC	8	Middle	-	3
70	M	Bcc	6	Middle	-	2
66	M	Bcc	8	Lateral	-	2.5
69	F	ScC	8	Middle	-	3
79	M	ScC	8	Middle	-	2.2
75	F	Bcc	5	Lateral	-	1.8

Bcc: Basal cell carcinoma, ScC: Squamous cell carcinoma

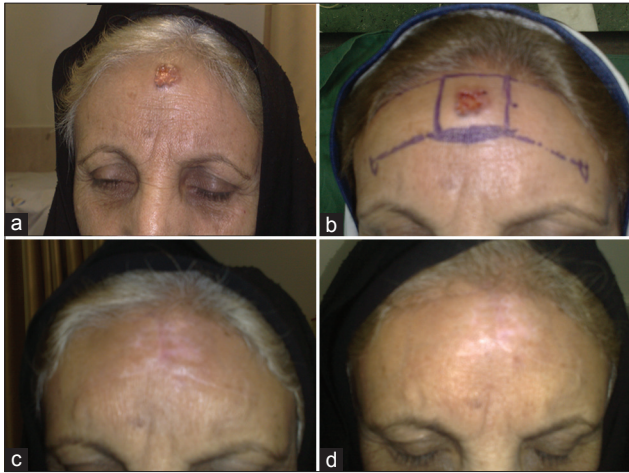


Figure 1: A 60-year-old woman with upper middle forehead basal cell carcinoma, (a) Before operation; (b) Designing of H-flap; (c) 3 month post operation; (d) 1 year post operation

demographic characteristic were shown in Table 1. Their median age was sixty-one years (range 50-79 years). We reconstructed forehead after excision of tumours in the same operation [Figure 1]. The median size of the defects was 4-6 cm, and all defects were rectangular shape. Informed consent and medical ethic approval were taken before operation.

Designing of this flap was parallel to resting skin tension line and upper borders of incisions were near hair line that causes disappearance of scar in future, from both side burrow triangles were excised for elimination of dog ears and better aesthetic results [Figure 1]. Releasing of flaps were done in supraperiosteal under sedation analgesia and subcutaneous injection of 1/200,000 epinephrine, we must release advancement flap at least 1.5 times the defect length in each side for tension-free repair.

RESULTS

We illustrate two opposing rectangular advancement flaps (H-flap) in upper forehead reconstructions. This flap has acceptable aesthetic results.

Ten upper forehead tumours were excised and rectangular defects were reconstructed with H-Flap [Figure 1]. There was no early morbidity including infection, ischaemia and necrosis of flaps [Table 1]. Long term aesthetic results of this flap in all cases were great with patient satisfaction according to questionnaire sheets are good and showed inconspicuous scars and good texture and colour match [Figure 1] of the reconstructed forehead. Scar lines were hidden under scalp hairs. Mean follow-up of patients were 15 months, and there were no recurrence during this time. This flap has limitation in radio dermatitis skins; also, we did not use this flap in lower forehead defects. For better result, burrow triangles must be removed from end of rectangles in both sides and silicon sheet was used on surgical scars for three months for better aesthetic results.

DISCUSSION

The approach to scalp and forehead reconstruction starts with a careful examination of the patient and the potential defect. This includes assessment of the location and size of the defect, with radiologic assessment of the depth and extension of defects.^[2]

This article outlines our approach to upper forehead reconstruction; this flap is a random based bilateral advancement flap. Because of laxity of skin in the older patients, we can coverage up to 6 cm defects with this flap. The simplest possible method of reconstruction should be considered in all patients while ensuring adequate reason of the lesion and a good functional result.^[3]

Primary closure is usually achieved with undermining of the remaining forehead.^[4] The relaxed skin tension lines (RSTLS) of forehead allow for a variety of closures ranging from simple primary ellipses to more complex advancement flaps.^[5] H-Flap is suitable for rectangular defects of upper forehead and long-term aesthetic results are good. Other methods for reconstruction include z-plasty, Rhomboid flap, worthin flap and skin grafts. Forehead defects that are shaped such that the long axis is perpendicular to the RSTLS or located in a region where tissue mobility more easily permits a vertical closure, can present a challenge for the reconstructive surgeon, the z-plasty is a favourable option in many of these situations.^[6] Several options exist for glabellar and inferior forehead defects; consideration was given to four possible reconstructions: A full thickness skin graft, superiorly and inferiorly based island pedicle flaps, superiorly and inferiorly based advancement flaps and inferior based rhombic flap.^[7] Reconstruction of the forehead and temple region passes special aesthetic challenges for maintaining eyebrow symmetry and hairline. The preservation of motor and sensory function

is also important.^[8] H-flap is an aesthetic flap for upper forehead defects in central or lateral parts of Forehead because direction of bilateral advancement is parallel to RSTLs and another advantage is upper border of flap is situated in hair line and not simply visible. This flap in the forehead is easily performed under local or general anaesthesia with high patients' satisfaction and low morbidity. We have found that the term H-flap provides a readily communicated alternate to double opposing rectangular advancement flaps.^[9] We recommend this flap for upper forehead reconstruction in defects between 4 cm and 6 cm. Directions of incisions are parallel to resting skin tension line and length to width of flap considered 2:1 with excision of burrow triangle from both side. We used silicon sheet post operatively for 3 months for better aesthetic results.

REFERENCES

1. Hicks DL, Watson D. Soft tissue reconstruction of the forehead and temple. *Facial Plast Surg Clin North Am* 2005;13:243-51.
2. TerKonda RP, Sykes JM. Concepts in scalp and forehead reconstruction. *Otolaryngol Clin North Am* 1997;30:519-39.
3. Beasley NJ, Gilbert RW, Gullane PJ, Brown DH, Irish JC, Neligan PC. Scalp and forehead reconstruction using free revascularized tissue transfer. *Arch Facial Plast Surg* 2004;6:16-20.
4. Minor LB, Panje WR. Malignant neoplasms of the scalp. Etiology, resection, and reconstruction. *Otolaryngol Clin North Am* 1993;26:279-93.
5. Tromovitch TA, Stegman SJ, Glogau RG. Flaps and grafts in dermatologic surgery 1989: Year Book Medical; p. 37-40.
6. Pomaranski MR, Krull EA, Balle MR. Use of the Z-plasty technique for forehead defects. *Dermatol Surg* 2005;31:1720-3.
7. Desai RS, Donnelly HB. Repair of a glabellar and inferior forehead defect. *Dermatol Surg* 2006;32:112-4.
8. Grigg R. Forehead and temple reconstruction. *Otolaryngol Clin North Am* 2001;34:583-600.
9. Rose V, Overstall S, Moloney DM, Powell BW. The H-flap: A useful flap for forehead reconstruction. *Br J Plast Surg* 2001;54:705-7.

How to cite this article: Ebrahimi A, Nejad sarvari N. Upper forehead skin reconstruction with H-flap. *J Cutan Aesthet Surg* 2013;6:152-4.

Source of Support: Nil. **Conflict of Interest:** None declared.

New features on the journal's website

Optimized content for mobile and hand-held devices

HTML pages have been optimized of mobile and other hand-held devices (such as iPad, Kindle, iPod) for faster browsing speed.

Click on **[Mobile Full text]** from Table of Contents page.

This is simple HTML version for faster download on mobiles (if viewed on desktop, it will be automatically redirected to full HTML version)

E-Pub for hand-held devices

EPUB is an open e-book standard recommended by The International Digital Publishing Forum which is designed for reflowable content i.e. the text display can be optimized for a particular display device.


Click on **[EPub]** from Table of Contents page.

There are various e-Pub readers such as for Windows: Digital Editions, OS X: Calibre/Bookworm, iPhone/iPod Touch/iPad: Stanza, and Linux: Calibre/Bookworm.

E-Book for desktop

One can also see the entire issue as printed here in a 'flip book' version on desktops.

Links are available from Current Issue as well as Archives pages.

Click on  View as eBook