

A Randomised, Open-label, Comparative Study of Tranexamic Acid Microinjections and Tranexamic Acid with Microneedling in Patients with Melasma

Background: Melasma is a common cause of facial hyperpigmentation with significant cosmetic deformity. Although several treatment modalities are available, none is satisfactory. **Aim:** To compare the therapeutic efficacy and safety of tranexamic acid (TA) microinjections versus tranexamic acid with microneedling in melasma. **Materials and Methods:** This is a prospective, randomised, open-label study with a sample size of 60; 30 in each treatment arms. Thirty patients were administered with localised microinjections of TA in one arm, and other 30 with TA with microneedling. The procedure was done at monthly intervals (0, 4 and 8 weeks) and followed up for three consecutive months. Clinical images were taken at each visit including modified Melasma Area Severity Index MASI scoring, patient global assessment and physician global assessment to assess the clinical response. **Results:** In the microinjection group, there was 35.72% improvement in the MASI score compared to 44.41% in the microneedling group, at the end of third follow-up visit. Six patients (26.09%) in the microinjections group, as compared to 12 patients (41.38%) in the microneedling group, showed more than 50% improvement. However, there were no major adverse events observed in both the treatment groups. **Conclusions:** On the basis of these results, TA can be used as potentially a new, effective, safe and promising therapeutic agent in melasma. The medication is easily available and affordable. Better therapeutic response to treatment in the microneedling group could be attributed to the deeper and uniform delivery of the medication through microchannels created by microneedling.

KEYWORDS: Melasma, microinjections, microneedling, tranexamic acid

INTRODUCTION

Melasma is a common cosmetic problem among Asians. It is an acquired pigmentary disorder characterised by more or less symmetrically distributed, medium- to dark-brown macules with well-defined geographic borders, affecting sun-exposed areas particularly forehead, cheeks, temples and upper lip.^[1]

The precise cause of melasma remains unknown. Multiple etiological factors implicated such as exposure to ultraviolet radiation, pregnancy, contraceptive pills, hormone replacement therapy, cosmetics, phototoxic and anti-seizure medications.^[1] In addition to the UV light itself, photo-induced hormones, growth factors, and chemical mediators of inflammation, which influence the function of melanocytes directly or indirectly, might contribute to the UV-induced pigmentation.^[2]

Different treatment modalities such as topical depigmenting agents,^[3,4] chemical peels,^[5] dermabrasion and laser therapies^[6] have been utilised in different studies with varying, not so satisfactory outcomes.

Access this article online	
Quick Response Code: 	Website: www.jcasonline.com
	DOI: 10.4103/0974-2077.118403

Leelavathy Budamakuntla, Eswari Loganathan, Deepak Hurkudli Suresh, Sharavana Shanmugam, Shwetha Suryanarayan, Aparna Dongare, Lakshmi Dammaningala Venkataramiah, Namitha Prabhu

Department of Dermatology, Bowring and Lady Curzon Hospital and Research Institute Bangalore Medical College and Research Institute, Bangalore, Karnataka, India

Address for correspondence:

Dr. Leelavathy Budamakuntla, No. 21, Sri Mookambika, 4th Cross, 1st Stage (Opposite IDIOM), Michael Playa, Indiranagar, Bangalore - 560 038, Karnataka, India.
E-mail: drleelaskincare@rediffmail.com

The results of recent clinical trials using localised intradermal microinjections of tranexamic acid (TA)^[7] and transepidermal delivery of TA using microneedling^[8] in the treatment of melasma are promising. In this study, we compare intradermal microinjections to microneedling in transepidermal delivery of TA in melasma patients.

MATERIALS AND METHODS

A prospective, randomised, open-label study was conducted with a sample size of 60, thirty each in each of the treatment arms, for 1 year from March 2010 to March 2011, after approval from the Ethical Committee of the Institutional Review Board (IRB).

Adult males and females between 18 and 50 years of age with moderate-to-severe bilaterally symmetrical distribution of melasma were included in the study after obtaining written informed consent. Pregnant/lactating females, patients on hormone replacement therapy or oral contraceptives, history of bleeding disorders, concomitant use of anticoagulants, any known drug allergy especially to the study drug, associated medical illnesses, and history of any other depigmenting treatment in the past 1 month were excluded from the study.

After obtaining detailed personal and medical history, Wood’s lamp examination was performed to classify the type of melasma. A modified MASI scoring system was used to assess the severity of melasma [Figure 1].

Tranexamic acid is available as 5 mL ampoule containing 500 mg of the drug. About 4 mg of TA is drawn in a

100 U/mL insulin syringe (about 4 units) and diluted with normal saline up to 1 mL (up to 100 U) to get a concentration of 4 mg/mL of TA.

After gentle cleansing, topical EMLA cream was applied over the area to be treated for about 45 to 60 min. The subjects in Arm 1 were treated with multiple microinjections of TA (4 mg/mL) intradermally into the melasma lesions at 1 cm intervals, depending on the extent of involvement, to a maximum of 8 mg to the entire affected area, using a 100 U/mL insulin syringe with a 4-mm mesoneedle.

The microneedles used had a width of 2 cm, studded with 192 fine needles of medical-graded stainless steel. The needle length was 1.5 mm and diameter 0.25 mm. According to the pressure applied, the needles penetrate the skin from 0.1 to 1.3 mm.

For the subjects in Arm 2, the skin was stretched and microneedling was carried out in vertical, horizontal, and both diagonal directions for about four to five times. Tranexamic acid, 0.5 to 1 ml (4 mg/mL), was applied over this area, and the procedure was repeated four to five times in the above-said directions. Ice packs were applied over the treated areas. The subjects were instructed to follow strict photo-protective measures.

The procedures were done three times at monthly intervals (0, 4 and 8 weeks) and followed up for further 3 months at monthly intervals. To assess the clinical response, clinical photographs were taken at the

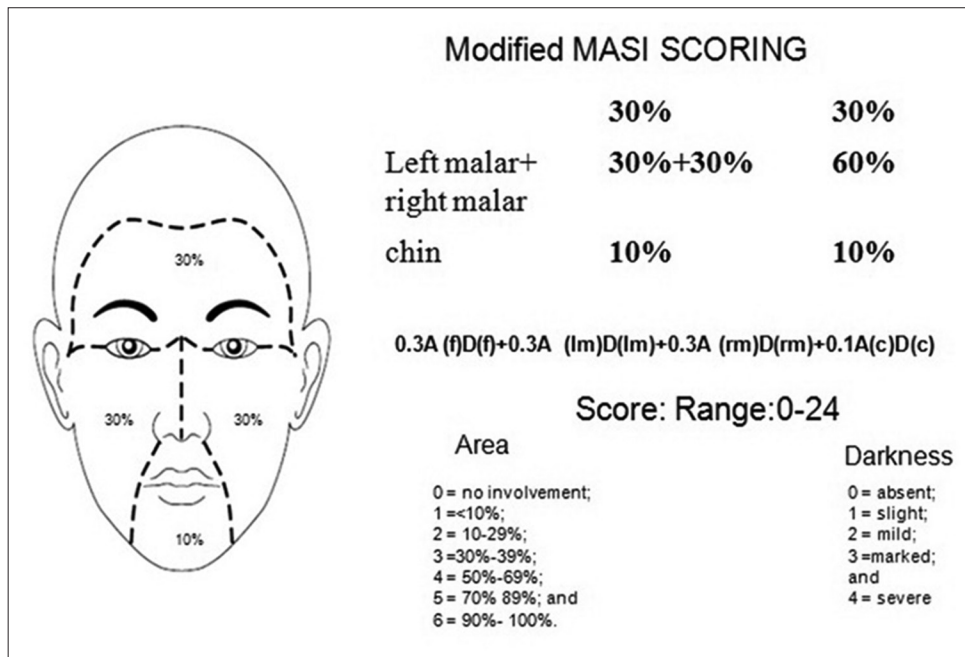


Figure 1: Modified MASI scoring

beginning of the therapy and then serially. MASI scoring, physician global assessment (PGA), and patient global assessment (PtGA) were performed at monthly intervals and any adverse events and complications were recorded.

The response to treatment in each patient was graded at the end of the study: No response, no improvement; mild response, <25% improvement; moderate response, 25% to < 50% improvement; good response, 50% to < 75% improvement; very good response, >75% improvement. Each case was followed up for 3 months to look for further improvement/relapse, if any.

The Kruskal–Wallis (nonparametric ANOVA) test was used to compare the means of MASI scores at each visit and follow up after treatment in each group. The unpaired *t*-test with Welch correction was used to compare means of MASI scores between the microinjections and microneedling group.

RESULTS

Out of 60 patients in the study, 41 (68.33%) patients belonged to the age group 30–50 years and the number of females (54) was more compared to males (6) in both the

treatment arms [Table 1]. All patients had Fitzpatrick skin type of 4 or 5 [Table 2]. Most patients had a centrofacial or malar pattern of distribution of melasma [Table 2]. Forty-six (80%) patients had mixed type of melasma, 5 (8.33%) had epidermal type and 7 (11.67%) had dermal type [Table 2]. Sun exposure was a risk factor in about 37 (61.67%) patients. Twenty-one (70%) patients had a history of melasma in their family. None of them were on any phototoxic drugs. Seven (11.67%) in the microinjection group and 8 (13.33%) in the microneedling group had undertaken treatment for melasma in the form of chemical peels, skin-lightening agents and some native medicines in the past. Two patients (3.33%) in the microinjection group and 3 (5%) in the microneedling group had concomitant dermatological disease such as Dermatitis papulosa nigra, freckles and palmoplantar psoriasis. Fifteen patients in the microinjection group and 16 in the microneedling group were using moisturisers. Eight (26.67%) patients dropped out from the study, 7 (23.34%) in the microinjection group and only 1 (3.33%) in the microneedling group, for unknown reasons.

The total MASI score in the microinjection group reduced from 159.3 (MASIb) at the first visit to 113.7 (MASI2) at the third visit, to 102.4 (MASI5) at the end of third follow-up. In the microneedling group, the total MASI score was 264.1 (MASIb) at the first visit, which reduced to 156.9 (MASI2) at the third visit and 146.8 (MASI5) at the end of third follow-up.

The mean MASI scores of all the visits and follow-ups in both the treatment arms are shown in Table 3. In the microinjection group, the mean MASI score at the base line was 6.93 ± 2.16 (MASIb) and at the end of third follow-up (MASI5) was 4.45 ± 1.69, which is 35.72% improvement with *P* < 0.01. In the microneedling group, the mean MASI score at the baseline was 9.11 ± 4.09 (MASIb) and at the end of third follow-up (MASI5) was 5.06 ± 2.14, which is 44.41% improvement with *P* < 0.001 [Figure 2]. There was no significant difference in the means of the MASI scores between the microinjection and microneedling group with the two-tailed *P* = 0.299.

Six (26.09%) patients in the microinjection group showed more than 50% improvement and 12 (41.38%) patients in the microneedling group showed more than 50%

Table 1: Age and sex distribution

Age	Microinjections (%)		Microneedling		Total
	Female	Male	Female (%)	Male	
18-29	4 (13.33)	1 (3.33)	1 (3.33)	1 (3.33%)	7 (11.67%)
30-39	12 (40.00)	0	5 (16.67)	0	17 (28.33%)
40-49	8 (26.67)	1 (3.33)	12 (40.00)	3 (10.00)	24 (40.00%)
50-60	4 (13.33)	0	8 (26.67)	0	12 (20.00%)
Total	28 (93.33)	2 (6.66)	26 (86.67)	4 (13.33%)	60

Table 2: Fitzpatrick skin type and patterns of melasma

	Microinjections (%)	Microneedling (%)	Total (%)
Fitzpatrick skin type			
Type 4	19 (63.33)	17 (56.67)	17 (56.67)
Type 5	11 (36.67)	13 (43.33)	13 (43.33)
Type of melasma			
Centrofacial	15 (50.00)	16 (53.33)	31 (51.67)
Malar	15 (50.00)	13 (43.33)	28 (46.67)
Mandibular	0	1 (3.33)	1 (1.67)
Pattern of melasma			
Epidermal	3 (10.00)	2 (6.67)	5 (8.33)
Dermal	4 (13.33)	3 (10.00)	7 (11.67)
Mixed	23 (76.67)	25 (83.33)	48 (80.0)

Table 3: Mean MASI scores, percentage improvement, and *P* value of both the groups

	MASIb	MASI 1 (4 weeks)	MASI 2 (8 weeks)	MASI 3 (12 weeks)	MASI 4 (16 weeks)	MASI 5 (20 weeks)
Microinjections	6.93±2.16	5.65±1.68	4.94±1.73	4.76±1.76	4.56±1.76	4.45±1.69
Percentage improvement		18.39	28.63	31.32	34.21	35.72
<i>P</i> value		>0.05	<0.05	<0.05	<0.01	<0.01
Microneedling	9.11±4.09	6.15±2.52	5.41±2.41	5.21±2.05	5.06±2.14	5.06±2.14
Percentage improvement		32.45	40.59	42.71	44.41	44.41
<i>P</i> value		>0.05	<0.001	<0.001	<0.001	<0.001

MASI: Melasma area severity index

improvement. Of these, two (6.90%) patients showed >75% improvement [Table 4]. Total PtGA and total PGA scores are shown in [Figure 3].

Clinical improvement is seen in the comparative photographs [Figures 4 and 5].

No serious side effects apart from mild discomfort, burning sensation and erythema were observed, which lasted for 1 or 2 days in most patients [Table 5].

Table 4: Percentage improvement of MASI scores in both the groups

Response (%)	Microinjections		Microneedling	
<25	6	26.09%	7	24.14%
25-50	11	47.82%	10	34.48%
50-75	6	26.09%	10	34.48%
75-100	0	0	2	6.90%

MASI: Melasma area severity index

Table 5: Adverse events

Adverse events	Microneedling	Microinjection
Itching	3	1
Burning	2	1
Erythema	4	4
Total	9	6

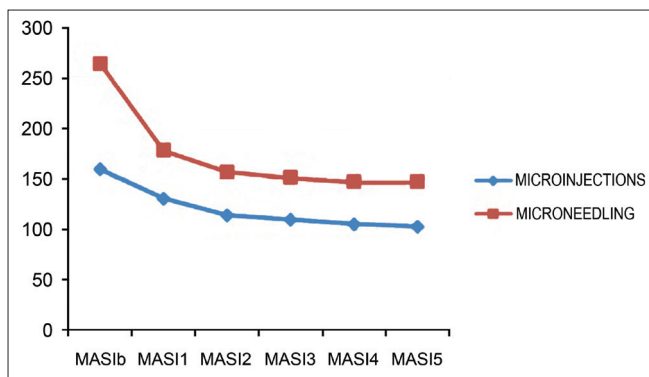


Figure 2: Comparative graph depicting the decline in MASI score in both groups

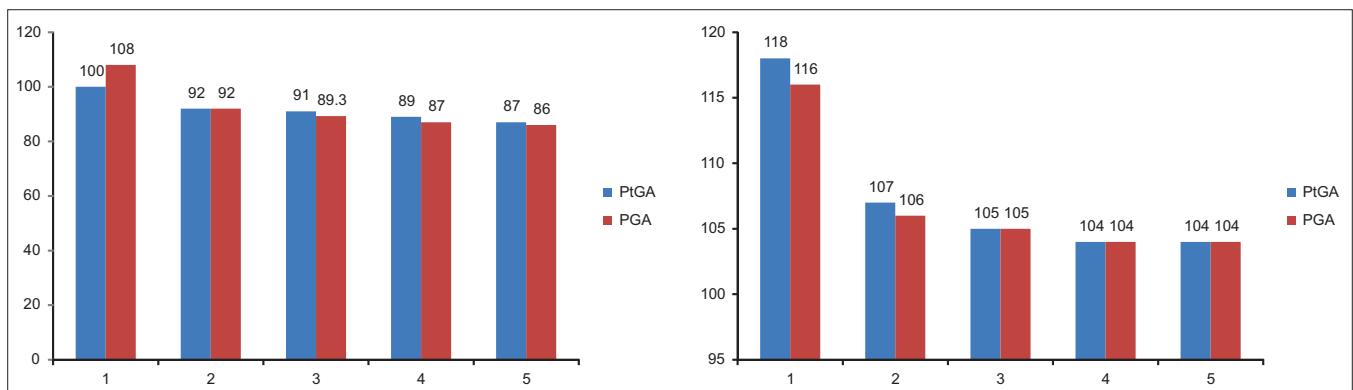


Figure 3: Total PGA and PtGA scores at different visits in the microinjection and microneedling groups

DISCUSSION

Tranexamic acid is mainly used for its antihemorrhagic and antifibrinolytic properties. Recent studies have revealed that topical *trans*-4-(aminomethyl) cyclohexanecarboxylic acid (*trans*-AMCHA, TA), a plasmin inhibitor, prevents UV-induced pigmentation in guinea pigs. Topical *trans*-AMCHA inhibits UV-induced plasmin activity in keratinocytes by preventing the binding of plasminogen to the keratinocytes, which ultimately results in decreased free arachidonic acid and a diminished ability to produce prostaglandins, which in turn decrease melanocyte tyrosinase activity.^[8] Human keratinocytes secrete the urokinase-type plasminogen activator, which increases the activity of melanocytes *in vitro*. The blockade of this effect may be due to the mechanism by which TA reduces hyperpigmentation in melasma patients.^[9] By injecting TA intradermally, it may be possible to treat the dermal-type melasma in addition to the mixed type.

Microneedle technology offers a minimally invasive and painless route of drug delivery.^[10] This technology involves the creation of channels in the skin with micron-sized dimensions, thereby enabling the delivery of a broad range of therapeutic molecules including proteins which would not otherwise cross intact skin.

Localised microinjections, the so-called “mesotherapy,” were introduced in France by Pistor.^[11] Mesotherapy is a widely used technique in medicine. This technique consists of intradermal or subcutaneous microinjections of 0.05 to 0.1 mL of highly diluted drug mixtures or a single drug, at the sites of body having medical or aesthetic problems. All intravenously injectable compounds may be used, except for alcoholic and oily solvents. It is aimed at applying an adequate amount of medication directly at the problematic area and avoiding oral medications. Furthermore, direct injection to the involved sites allows lower dosage of drugs to be used.

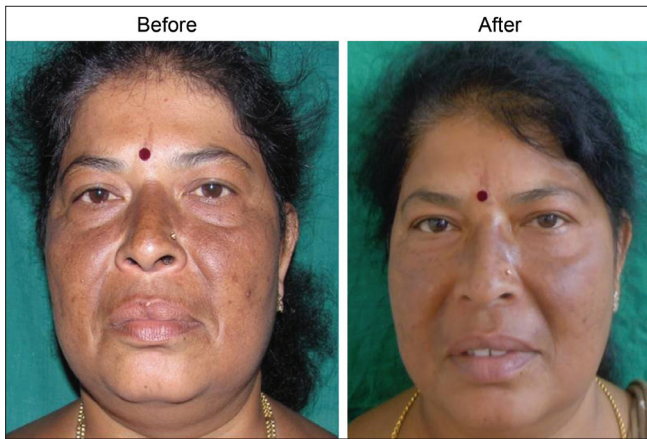

Figure 4: Treatment with microneedling: before and after

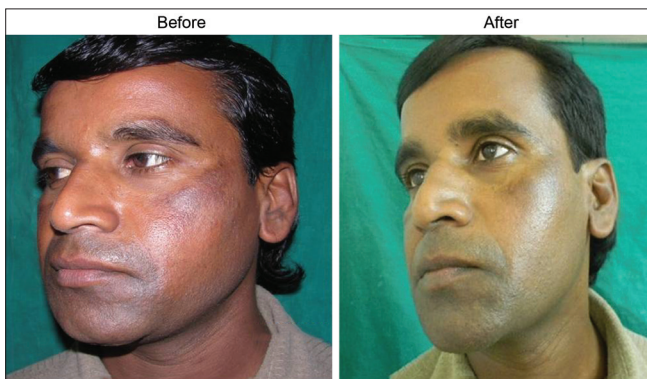

Figure 5: Treatment with microinjections: before and after

The microneedling device is a simple, handheld instrument consisting of a handle with a cylinder studded all around with fine, stainless steel needles of 0.5 to 2 mm in length. To achieve therapeutic benefits, this needle-studded cylinder is rolled on the skin in multiple directions to create microchannels. Hence, the technique is named “microneedling”.^[12] It is currently used in the cosmetic industry to treat several skin conditions such as pigmentation problems, wrinkles, acne and post-burn scars, and also in facial rejuvenation as a part of collagen induction therapy.^[13]

In this study, we have used localised microinjections (mesotherapy) and microneedling to deliver the study drug TA. We compared both these modes of drug delivery, the safety and efficacy in the treatment of melasma. The MASI scores, PtGA, and PGA showed a significant decreasing trend from the baseline to the fourth, eighth, and twelfth week of treatment with TA in both the treatment arms. The scores showed better improvement in patients treated with microneedling than with microinjections though the difference was

not statistically significant. This can be attributed to the fact that microneedling delivers the medication more evenly and deeper into the skin. All scores remained almost the same during the next 3 months of follow-up.

CONCLUSION

On the basis of the findings, TA can be used as potentially a safe, effective, and promising therapeutic agent for the treatment of melasma. The medication is easily available and affordable. It is an office-based procedure with relatively quick results, no significant side effects, and almost no downtime.

REFERENCES

1. Grimes PE. Melasma: Etiologic and therapeutic considerations. *Arch Dermatol* 1995;131:1453-7.
2. Morelli JG, Norris DA. Influence of inflammatory mediator and cytokines in human melanocyte function. *J Invest Dermatol* 1993;100:191S-5.
3. Gupta AK, Gover MD, Nouri K, Taylor S. The treatment of melasma: A review of clinical trials. *J Am Acad Dermatol* 2006;55:1048-65.
4. Bentley-Phillips B, Bayles MA. Cutaneous reactions to topical application of hydroquinone. Results of a 6-year investigation. *S Afr Med J* 1975;49:1391-5.
5. Hurley ME, Guervara IL, Gonzales RM, Pandya AG. Efficacy of glycolic acid peels in the treatment of melasma. *Arch Dermatol* 2002;138:1578-82.
6. Li YH, Chen JZ, Wei HC, Wu Y, Liu M, Xu YY, *et al.* Efficacy and safety of intense pulsed light in treatment of melasma in Chinese patients. *Dermatol Surg* 2008;34:693-700.
7. Lee JH, Park JG, Lim SH, Kim JY, Ahn KY, Kim MY, *et al.* Localized intradermal microinjection of tranexamic acid for treatment of melasma in Asian Patients: A Preliminary Clinical Trial. *Dermatol Surg* 2006;32:626-31.
8. Maeda K, Naganuma M. Topical trans-4- aminomethylcyclohexanecarboxylic acid prevents ultraviolet radiation induced pigmentation. *J Photochem Photobiol* 1998;47:130-41.
9. Zhang XY, Yang XH, Yang H, Yang YP. Study of inhibitory effect of acidum tranexamicum on melanin synthesis. *Chin J Dermatovenerol Int Tradit West Med* 2003;2:227-9.
10. Kaushik S, Hord AH, Denson DD, McAllister DV, Smitra S, Allen MG, *et al.* Lack of pain associated with microfabricated microneedles. *Anesth Analg* 2001;92:502-4.
11. Pistor M. *Un defi therapeutique: la mesotherapie*. 3rd ed. Paris: Maloine; 1979. p. 1-50.
12. Kalluri H, Kolli CS, Banga AK. Characterization of microchannels created by metal microneedles: Formation and closure. *AAPS J* 2011;13:473-81.
13. Majid I. Microneedling therapy in atrophic facial scars: An objective assessment. *J Cutan Aesthet Surg* 2009;2:26-30.

How to cite this article: Budamakuntla L, Loganathan E, Suresh DH, Shanmugam S, Suryanarayan S, Dongare A, *et al.* A randomised, open-label, comparative study of tranexamic acid microinjections and tranexamic acid with microneedling in patients with melasma. *J Cutan Aesthet Surg* 2013;6:139-43.

Source of Support: Loreal Research Grant. **Conflict of Interest:** None declared.