

A Study of Donor Area in Follicular Unit Hair Transplantation

Background: The advent of follicular unit transplantation (FUT) has given a natural appearance in the recipient area in the past two decades, but has left behind an unsightly scar in the donor area. A study of donor area and techniques to make it cosmetically acceptable is lacking. **Aim:** The aim of this study was to evaluate the donor area after follicular unit hair transplantation and to show a few techniques to make the donor scar aesthetically pleasing. **Materials and Methods:** The donor area was examined for scar width and patient satisfaction scores of donor area in 30 consecutive patients from March 2012 to February 2013 retrospectively after a minimum of 3 months after the procedure. Complications such as effluvium along suture line, wound infection, dehiscence, necrosis, folliculitis, keloids and wide scars were also noted. **Results:** Scar width increased with increase in width of the donor strip. Patient satisfaction scores declined with larger strip widths. The most common complication seen was folliculitis-like lesions. Double trichophytic closure yielded the most aesthetically acceptable scar. **Conclusion:** FUT produces a linear scar in the donor area, which can be a significant concern in patients wishing to cut their hair short. Restricting the width of the donor strip and trichophytic closure has greatly improved the appearance of the scar.

KEYWORDS: Hair transplantation, scar, trichophytic closure

INTRODUCTION

Follicular unit hair transplantation involves excision of a strip of hair from the occipital area, dissecting into individual follicular units and implanting in the recipient area. The major disadvantage is a production of a linear disfiguring scar in the donor area. This led to the practice of newer techniques like follicular unit extraction (FUE). FUE does not produce a linear scar, but is associated with tedious extraction causing fatigue to the operating surgeon, less perifollicular tissue giving support to the graft^[1,2] and higher transection rates during extraction of the grafts. Hence, the need of the hour is to use follicular unit transplantation (FUT), which gives a better yield in terms of quality and number of grafts, but with aesthetically thin scar.

Aim and objectives

Our aim was to evaluate the donor area to analyse the relationship between strip width and scar width, patient satisfaction scores with different techniques of closure and complications in the donor area post-hair transplantation.

MATERIALS AND METHODS

FUT was done by taking a strip from occiput in a trapezoid fashion^[3] after assessment of scalp laxity. The wound was closed with 3-0 polyglactin 910 (vicryl rapide) suture material using continuous non-trichophytic, single trichophytic and double trichophytic closure techniques^[4] [Figure 1]. In trichophytic closure, a thin shallow strip of 1-2 mm that does not cause damage to the bulge area of the follicles and the sebaceous gland is cut from the edge of the wound and closed. Surgical stapler was applied over the sutured area for reinforcement and was removed after 1 week.^[5]

The donor area was analysed in 30 consecutive patients from March 2012 to February 2013 who underwent FUT in our institute. Any adverse events in the donor area were also noted. Scar in the donor area was analysed using

Access this article online	
Quick Response Code: 	Website: www.jcasonline.com
	DOI: 10.4103/0974-2077.123408

Balakrishnan Nirmal, Savitha Somiah, Sarvajnamurthy A Sacchidanand

Department of Dermatology, Venereology and Leprosy, Bangalore Medical College and Research Institute, Bengaluru, Karnataka, India

Address for correspondence:

Dr. Sacchidanand. S, Department of Dermatology, Venereology and Leprosy, Bangalore Medical College and Research Institute, Bengaluru, Karnataka, India.

E-mail: sacchi1260@yahoo.com

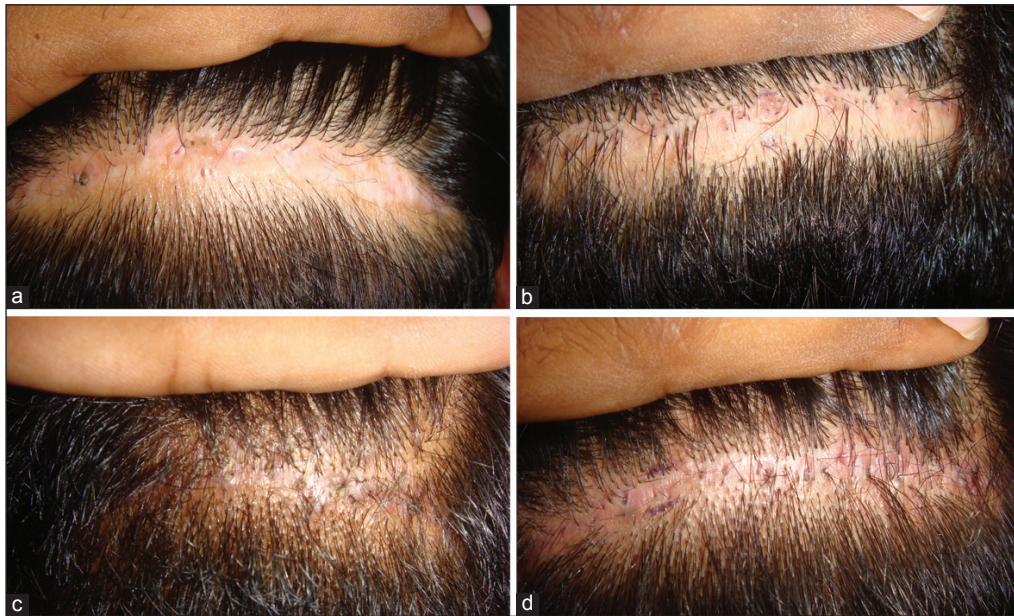


Figure 1: Trichophytic closures: (a) non-trichophytic, (b) single upper trichophytic, (c) single lower trichophytic (d) double trichophytic

Heine Delta® 20 dermatoscope for width and appearance 3 months after FUT. Scar width was recorded in 3 points—centre, midpoint of right limb, midpoint of left limb of the scar and average scar width in millimetres was recorded. Patient satisfaction was scored in a visual analogue scale of 1 to 10 at this time. The results were statistically analysed using statistical package for the social sciences (SPSS) version 11.0 (SPSS, Inc., Chicago, IL).

RESULTS

A total of 30 male patients with age range of 25 to 49 years participated in this study. The strip width in the donor area varied from 10 to 15 mm [Table 1]. After harvesting the strip, the wound was closed using four different techniques viz. Non-trichophytic, single upper trichophytic (SU), single lower trichophytic (SL) and double trichophytic. Maximum closures were done using a single trichophytic closure based on the lower edge of the wound constituting 56.67% [Table 2].

Comparison of scar width with strip width

Spearman’s rank correlation was used to compare the width of the donor scar with the strip width. [Figure 2] The scar width was found to increase in a linear positive fashion ($r = 0.744$) significantly with width of the strip taken ($P < 0.001$).

Comparison of patient satisfaction with strip width

Spearman’s rank correlation when used to compare patient satisfaction with strip width [Figure 3] showed their satisfaction to decrease ($r = -0.534$) significantly with increased width of the strip taken ($P = 0.002$).

Table 1: Donor strip width in comparison with scar width and patient satisfaction VAS score

Strip width (in mm)	No. of patients	Scar width (in mm)	VAS (1-10)
15	4	7, 9, 9, 9	1, 2, 5, 8
14	7	5, 5, 6, 7, 7, 7, 10	3, 5, 7, 7, 7, 7, 8
13	6	5, 6, 9, 9, 10, 10	5, 5, 5, 5, 6, 8
12	6	3, 3, 3, 3, 4, 5	6, 6, 7, 7, 8, 9
11	1	4	8
10	6	3, 3, 3, 4, 4, 4	5, 7, 8, 8, 8, 9

VAS: Visual analogue scale

Table 2: Type of closure and median VAS score

Type	No. of patients	Median VAS (interquartile range)
Non-trichophytic (N)	3	5.0 (1-8)
Single upper trichophytic (SU)	6	6.0 (4.3-7.3)
Single lower trichophytic (SL)	17	6.0 (5-7.5)
Double trichophytic (D)	4	8.5 (7.25-9)

VAS: Visual analogue scale

Comparison of patient satisfaction with different types of closure

Mann-Whitney U test was used to compare the patient satisfaction score in each of the 4 types of closure [Figure 4] done in the study period. The median interquartile range of the patient satisfaction scores were found to increase from non-trichophytic (Score = 5), single upper (6), single lower (6) to double trichophytic closure (8.5). We did a comparison between single trichophytic closure done on the upper edge SU with that done on the lower edge SL showed a slightly higher interquartile range of patient satisfaction scores

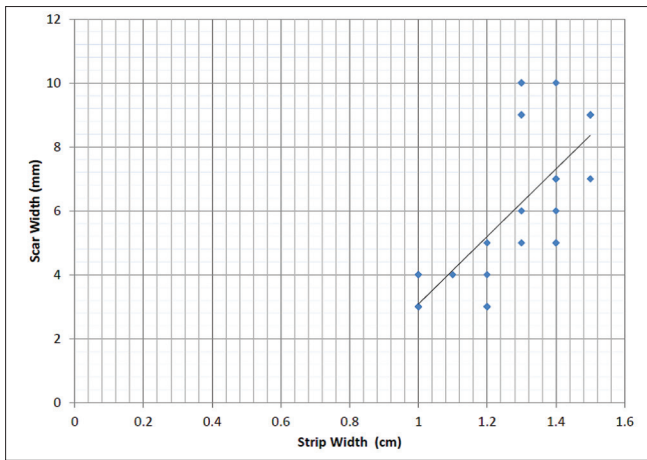


Figure 2: Graph showing comparison of scar width with strip width

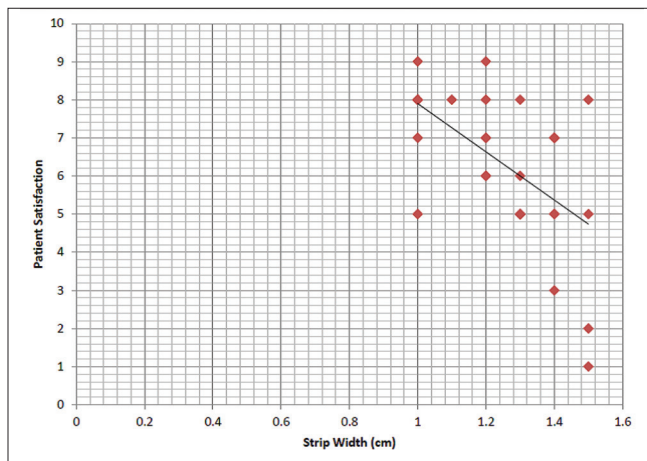


Figure 3: Graph showing comparison of patient satisfaction with strip width

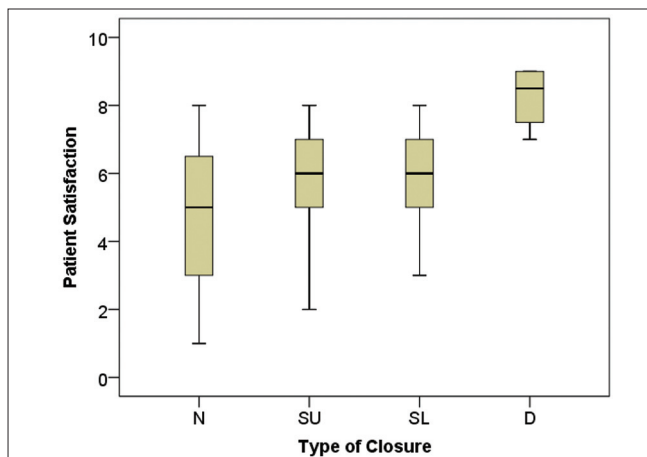


Figure 4: Inter quartile range of patient satisfaction scores with different types of closure N-Non-trichophytic, SU-Single Upper, SL-Single Lower, D-Double trichophytic

in the SL group, but was not statistically significant ($P = 0.614$). The range was 4.3 to 7.3, 5 to 7.5 in SU and SL respectively. Comparison between other groups was

not done due the relatively less number of patients in the other two groups.

Complications

Folliculitis like lesions over the donor area were observed as the most common complication event post FUT accounting for 53.33% of the patients. Hypertrophic scar was seen in two patients followed by effluvium along suture line seen in one patient. Wound dehiscence, was also seen in only one patient when the strip width was 1.5 cm. None of our patients had wound infection or necrosis.

DISCUSSION

Despite being an extremely common entity, androgenetic alopecia^[6] can cause significant psychosocial impairment of quality-of-life of the affected individuals.^[7] Medical treatment of AGA has advanced with better understanding of the biochemistry and physiology of hair growth and hair loss, but currently there are only two pharmacologic treatments approved by the united states. Food and drug administration to treat male pattern baldness namely minoxidil^[8] and finasteride. Optimal aesthetic results can be achieved by combining medical therapy with surgical transplantation of follicular unit grafts.^[9] The technique of surgical hair transplantation evolved from the unnatural “doll look” with Orentreich’s 4.0 mm punch graft method in the 90s to the current FUT.^[10] There was a gradual transformation from 10 to 20 hair plugs to the natural 1 to 4 hair follicular units.^[11] The switch led to complaints from patients about residual linear scarring at the donor area of the patient’s scalp. To overcome this problem of donor scar, FUE^[12] was devised by Rassmann and Bernstein in 2002. The transection rates were higher and the quality of grafts was inferior compared with FUT.^[13] This necessitated using FUT^[14] with techniques to improve the appearance of donor scar.^[15-17]

Our study clearly showed that the scar width in the donor area increased with the width of strip taken. Patient satisfaction scores also decreased with increase in strip width. Higher satisfaction scores were seen when the strip width was kept less than 1.3 cm. It is imperative to align the patient in this regard before the procedure of FUT. If more yields are require the patient’s bald area and strip width more than 1.3 cm is warranted, trichophytic closure gave better cosmesis of donor scar.

Trichophytic closure [Figure 5] is a type of closure where a small ledge of tissue comprising of the epidermis and superficial dermis is cut with a fine scissors before wound closure.^[18,19] After healing, hair grows out through the scar giving a better cosmetic camouflage of the scar. Median interquartile range patient satisfaction scores was highest for double trichophytic followed by single and non-trichophytic closures. Most common

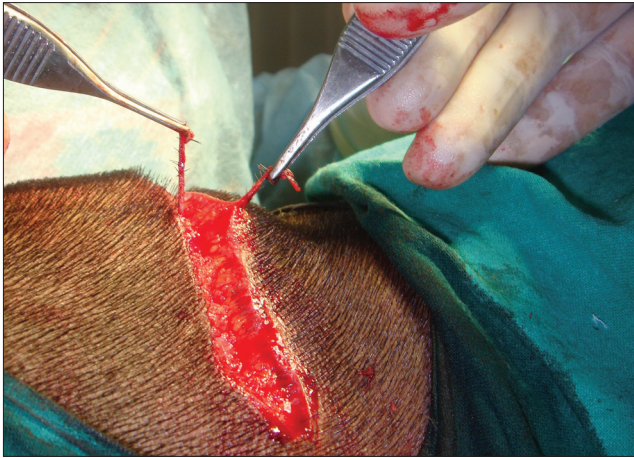

Figure 5: Trichophytic closure

complication^[20] after FUT was folliculitis-like lesions accounting for 16 out of the 30 cases. These lesions were few in number and appeared in the first few months post-transplant. Lesions were symptomatic with pain and itching only in 3 cases.

CONCLUSION

Smaller strip width is associated with smaller aesthetically pleasing scar and greater patient satisfaction in the donor area. If larger strip widths are warranted, closing under no-tension, using surgical skin staplers for reinforcement and trichophytic closure has greatly improved the appearance of strip harvest scar.

FUTURE DIRECTIONS

We recommend further prospective studies to evaluate the scar appearance with head-to head comparison of single and double trichophytic closures. The need to close the edges in a trapezoid fashion instead of the regular elliptical closure to decrease the transection rates should also be compared on a one-on-one basis.

REFERENCES

1. Beehner ML. A comparison of hair growth between follicular-unit grafts trimmed "skinny" vs. "chubby". *Dermatol Surg* 1999;25:339-40.
2. Saeger D. Chubby versus skinny grafts. *Dermatol Surg* 1997;23:757-61.
3. Seery GE. Hair transplantation: Management of donor area. *Dermatol Surg* 2002;28:136-42.
4. Yamamoto K. Double trichophytic closure with wavy two-layered closure for optimal hair transplantation scar. *Dermatol Surg* 2012;38:664-9.
5. Bernstein RM. Staples revisited. *Hair Transplant Forum Int* 2008;18:10-1.
6. Shiell RC. A review of modern surgical hair restoration techniques. *J Cutan Aesthet Surg* 2008;1:12-6.
7. Sehgal VN, Kak R, Aggarwal A, Srivastava G, Rajput P. Male pattern androgenetic alopecia in an Indian context: A perspective study. *J Eur Acad Dermatol Venereol* 2007;21:473-9.
8. Singh G. Effect of minoxidil on hair transplantation in alopecia androgenetica. *Indian J Dermatol Venereol Leprol* 1998;64:23-4.
9. Bouhanna P. Androgenetic alopecia: Combining medical and surgical treatments. *Dermatol Surg* 2003;29:1130-4.
10. Bernstein RM, Rassman WR. Follicular unit hair transplantation. *Dermatol Surg* 1997;23:771-84.
11. Harris JA. Follicular unit transplantation: Dissecting and planting techniques. *Facial Plast Surg Clin North Am* 2004;12:225-32.
12. Dua A, Dua K. Follicular unit extraction hair transplant. *J Cutan Aesthet Surg* 2010;3:76-81.
13. Sadick NS, White MP. Basic hair transplantation: 2007. *Dermatol Ther* 2007;20:436-47.
14. Rassman WR. Concern about quality. *Hair Transplant Forum Int* 1994;4:3.
15. Avram MR, Rogers NE. Hair transplantation for men. *J Cosmet Laser Ther* 2008;10:154-60.
16. Rawnsley JD. Hair restoration. *Facial Plast Surg Clin North Am* 2008;16:289-97.
17. Khanna M. Hair transplantation surgery. *Indian J Plast Surg* 2008;41:56-63.
18. Venkataram M. Changing trends in hair restoration surgery. *Indian J Dermatol Venereol Leprol* 2006;72:103-11;112, 125.
19. Patwardhan N, Mysore V, IADVL Dermatosurgery Task Force. Hair transplantation: Standard guidelines of care. *Indian J Dermatol Venereol Leprol* 2008;74 Suppl:546-53.
20. Meza DP. Complications in hair restoration surgery. *Hair Transplant Forum Int* 2000;10:5.

How to cite this article: Nirmal B, Somiah S, Sacchidanand SA. A study of donor area in follicular unit hair transplantation. *J Cutan Aesthet Surg* 2013;6:210-3.

Source of Support: Nil. **Conflict of Interest:** None declared.