

Repair of Minor True Hare Lip Using V–Y Plasty: How I Do It

Abdelrahman EM Ezzat

Department of ENT, Al-Azhar University Hospitals, Cairo, Egypt

Address for correspondence: Dr. Abdelrahman E.M. Ezzat, Department of ENT, Faculty of Medicine, Al-Azhar University Hospitals, Cairo, Egypt.

E-mail: aemei_ibrahim@yahoo.co.uk

ABSTRACT

Background: Minor true hare lip is rare central midline deficiency of the upper lip. There are multiple techniques but little consensus on the preferred surgical technique. **Materials And Methods:** A transoral approach for repair using mucosal V–Y plasty is described by employing a vertical inverted V incision. **Result:** The contour of the free labial border immediately improves with avoidance of skin scar. **Conclusions:** The midline cleft lip notch or minor true (hare lip) midline clefts can be effectively treated by mucosal lengthening using a V–Y plasty. Moreover, the ability to augment the tubercle with mucosa through a VY plasty is simple and easy.

KEYWORDS: Midline cleft lip, mucosal V–Y plasty, true hare lip

BACKGROUND

Multiple terms have been used to describe the constellations of abnormalities observed with true midline clefts (hare lip), including median cleft face syndrome^[1] and Tessier's grade 0 clefts.^[2] The incidence of midline cleft of the lip or Tessier's grade 0 cleft is reported to be about 0.43% to 0.73% of the craniofacial cleft population.^[3]

Hypertelorbitism, midline craniofacial osseous defects, hairline abnormalities and a midline upper lip cleft may be present to varying degrees in these cases.^[4] However, the mildest form including a small notch in the soft tissue of the upper lip that does not cross the vermilion border could occur.^[5]

Multiple techniques have been described to repair the median cleft lip deformity. I describe a transoral mucosal V–Y plasty and midline orbicularis oris muscle repair for midline cleft lip notch.

MATERIALS AND METHODS

Clinical presentation

A 17-year-old female presented with a notch in the

upper lip including the wet and dry mucosa crossing the vermilion border [Figure 1a]. The maxillary alveolus was notched at the midline, but no osseous cleft was present. Other pertinent facial findings included a shortened nasal length with deviation of the anterior nasal opening on the right side and normotelorism [Figure 1b]. The nasal septum and anterior nasal spine was shifted to the right side.

Surgical technique and outcome

A V–Y plasty was designed by donning a vertical inverted V incision (with the apex upward) in the mucosal side of the upper lip [Figure 2a]. Raising the mucosal flaps exposed the orbicularis oris muscle, which was separated from each other and the underlying median cleft notch between the two muscles [Figure 2b]. The orbicularis oris muscle was dissected on both sides and united in the midline using horizontal mattress sutures [Figure 2c]. Using a 5-0 Vicryl, the V-shaped mucosal flap was sutured into a position as Y shaped giving an additionally mucosal length [Figure 2d]. The extra piece of mucosa was excised. The nasal correction was done in the same site with repositioning of the lower lateral cartilage for tip repositioning, with maxillary augmentation (lengthening of the lower lateral cartilage and elevation of the nasal dorsum) with septal cartilage [Figure 3a-d]. The notch was corrected immediately and appropriate lip height and fullness were achieved with maintenance of shape for 1 year postoperatively [Figure 4a and b].

Access this article online

Quick Response Code:



Website:
www.jcasonline.com

DOI:
10.4103/0974-2077.155089

DISCUSSION

In 1937, Veau classified three varieties of median clefts: Notch of the lip, median cleft extending to the columella and a defect due to atrophy of midline facial structures.^[6] DeMyer described two groups of syndromes associated with the median cleft lip. The first is associated with orbital hypotelorism and the second with hypertelorism.^[1] In this case report, the patient described had a midline cleft of the upper lip without any deformities of philtrum and minor nasal opening shift with normotelorism.

Surgical correction of the true harelip has been described for both minor and severe defects. Weimer^[7] described the excision of a diamond-shaped piece of skin and mucosa, as well as a fibrotic band with overlap of the orbicularis oris muscle and a zigzag closure of the

mucosa. Buonocore *et al.*,^[8] described a Z-plasty designed on either side of the elongated frenulum with excision of the constriction band.

Urata and Kawamoto^[9] described a hidden intraoral incision to correct a mild deformity, which does not cross the vermilion border. Therefore, I have done an intraoral incision and I have found that the intraoral incision allows orbicularis oris muscle and provides the surgeon with the ability to augment the tubercle with mucosa through a V-Y plasty.

CONCLUSIONS

The midline cleft lip notch or minor true hare lip midline clefts can be effectively treated by mucosal lengthening using a V-Y plasty, which successfully releases the notched lip, provides mucosal length and vermilion fullness and with avoidance of skin scar. Moreover, the ability to augment the tubercle with mucosa through a VY plasty is simple and easy.

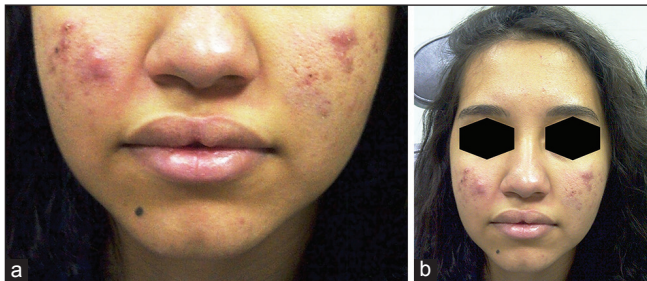


Figure 1: (a) Preoperative picture of the patient's lip. (b) Preoperative picture of the patient

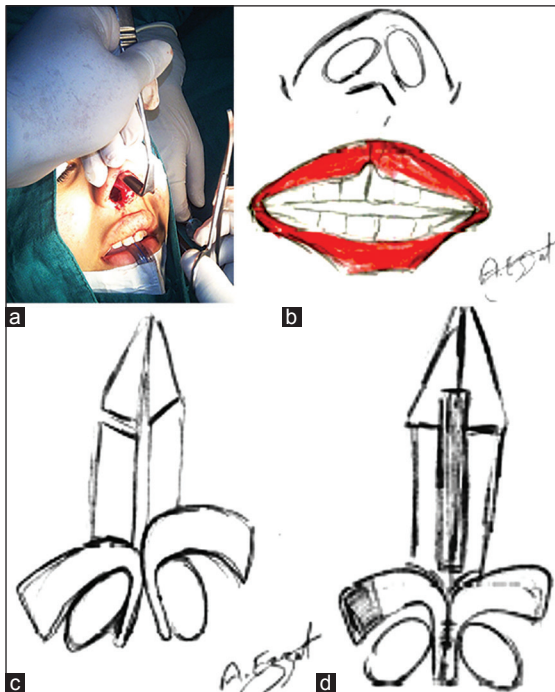


Figure 3: (a) Intraoperative image of the nasal correction. (b) Diagram of the lip and nasal deformity. (c) Intraoperative diagram of the nasal deformity. (d) Intraoperative diagram showing the correction of the nasal deformity

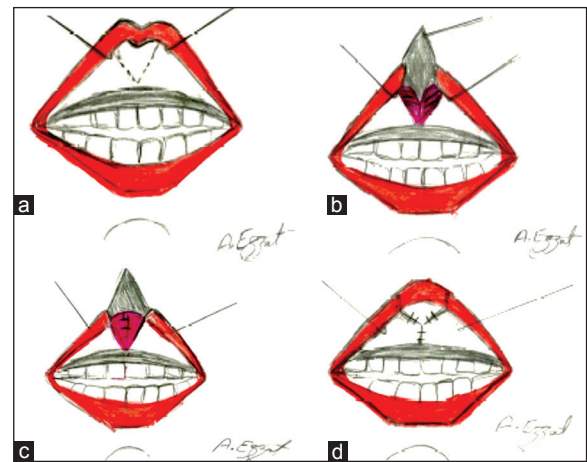


Figure 2: (a) Intraoperative diagrams showing vertical inverted V incision (with the apex upward) in the mucosal side of the upper lip. (b) Separation of the two orbicularis oris muscles from each other and the underlying median cleft notch between them. (c) The orbicularis oris muscle dissected on both sides and united in the midline using horizontal mattress sutures. (d) The V-shaped mucosal flap sutured into position as Y shaped, giving an additionally mucosal length

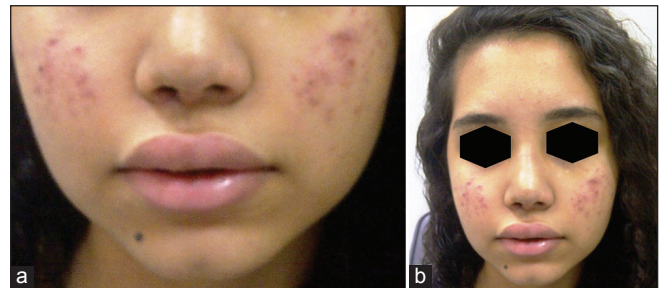


Figure 4: (a) One year postoperative picture of the patient's lip. (b) One year postoperative picture of the patient

REFERENCES

1. De Myer W, Zeman W, Palmer CD. Familial alobar holoprosencephaly (Arhinencephaly) with median cleft lip and palate. Report of patient with 46 chromosomes. *Neurology* 1963;13:913-8.
2. Tessier P. Anatomical classification of facial, cranio-facial, and latero-facial clefts. *J Maxillofac Surg* 1976;4:69-92.
3. Fogh-Andersen P. Rare clefts of the face. *Acta Chir Scand* 1965;129: 275-81.
4. Francesconi G, Fortunato G. Median dysraphia of the face. *Plast Reconstr Surg* 1969;43:481-91.
5. Boo-Chai K. The bifid nose. With a report of 3 cases of siblings. *Plast Reconstr Surg* 1965;36:626-8.
6. Veau V. Hasencharten menschlicher Keimlinge auf der Stufe 21-23 mm SSL. *Z Anat Entwicklungsgesch* 1937;108:459. Quoted from, Patel NP, Tantri MD. Median cleft of the upper lip: A rare case. *Cleft Palate Craniofac J* 2010;47:642-4.
7. Wiemer DR, Hardy SB, Spira M. Anatomical findings in median cleft of upper lip. *Plast Reconstr Surg* 1978;62:866-9.
8. Buonocore SD, Walker ME, Steinbacher DM. Repair of the median microform cleft lip using Z-plasty. *Mode Plast Surg* 2012;2:43-5.
9. Urata MM, Kawamoto HK Jr. Median clefts of the upper lip: A review and surgical management of a minor manifestation. *J Craniofac Surg* 2003;14:749-55.

How to cite this article: Ezzat AE. Repair of minor true hare lip using V-Y plasty: How i do it. *J Cutan Aesthet Surg* 2015;8:54-6.

Source of Support: Nil. **Conflict of Interest:** None declared.