

Decoding Facial Esthetics to Recreate an Esthetic Hairline: A Method Which Includes Forehead Curvature

Anil K. Garg, Seema Garg

Rejuvenate Hair Transplant Centre, Indore, India

Abstract

Context: The evidence suggests that our perception of physical beauty is based on how closely the features of one's face reflect phi (the golden ratio) in their proportions. By that extension, it must certainly be possible to use a mathematical parameter to design an anterior hairline in all faces. **Aim:** To establish a user-friendly method to design an anterior hairline in cases of male pattern alopecia. **Materials and Methods:** We need a flexible measuring tape and skin marker. A reference point A (glabella) is taken in between eyebrows. Mark point E, near the lateral canthus, 8 cm horizontal on either side from the central point A. A mid-frontal point (point B) is marked 8 cm from point A on the forehead in a mid-vertical plane. The frontotemporal points (C and C') are marked on the frontotemporal area, 8 cm in a horizontal plane from point B and 8 cm in a vertical plane from point E. The temporal peak points (D and D') are marked on the line joining the frontotemporal point C to the lateral canthus point E, slightly more than halfway toward lateral canthus, usually 5 cm from the frontotemporal point C. This line makes an anterior border of the temporal triangle. **Result:** We have conducted a study with 431 cases of male pattern alopecia. The average distance of the mid-frontal point from glabella was 7.9 cm. The patient satisfaction reported was 94.7%. **Conclusion:** Our method gives a skeletal frame of the anterior hairline with minimal criteria, with no need of visual imagination and experience of the surgeon. It automatically takes care of the curvature of the forehead and is easy to use for a novice surgeon.

Keywords: Anterior hairline (AHL), frontotemporal angle (FTA), male pattern alopecia (MPA), mid-frontal point (MFP), temporal peak (TP) point

Key message: Anterior hairline is a very important aspect of hair restoration. Our method is a very simple, easy to learn and design in cases of male pattern baldness.

INTRODUCTION

The anterior hairline (AHL) separates the face from the scalp.^[1] Its location and design varies with facial structures. The significance of designing an esthetic AHL in hair transplant cannot be stressed enough. The designed hairline should look natural and should be acceptable to the patient.^[1] Evidence suggests that our perception of physical beauty is based on how closely the features of one's face reflect phi (the golden ratio)^[2] in their proportions. This means that all faces perceived to be beautiful, each different from the other, are united in their adherence to the golden ratio. By that extension, it must certainly be possible to use a mathematical parameter to design AHL on all faces. We all know Leonardo da Vinci's^[3] concept of facial dimensions, that is, the rule of one-third. Esthetics of a face is a definite proportion of

one's structure to another, and somewhere mathematics lies behind the esthetics.

The proposed method translates this idea into practical use. On studying several matured male faces with esthetic hairlines, we observed two patterns.

1. All matured male hairlines^[4] show a mid-frontal mound with either side of frontotemporal deepened bald area called frontotemporal angle (FTA) and two temporal peaks (TPs) in the temple area. In an attempt to decode this pattern, a face with an esthetic hairline was chosen and its AHL was marked. Then using animation software,

Address for correspondence: Dr. Anil Kumar Garg,
Rejuvenate Hair Transplant Centre, 2/1 RS Bhandari Marg, Indore, India.
E-mail: anilgarg61@yahoo.com

Access this article online

Quick Response Code:



Website:
www.jcasonline.com

DOI:
10.4103/JCAS.JCAS_51_17

This is an open access article distributed under the terms of the Creative Commons Attribution-NonCommercial-ShareAlike 3.0 License, which allows others to remix, tweak, and build upon the work non-commercially, as long as the author is credited and the new creations are licensed under the identical terms.

For reprints contact: reprints@medknow.com

How to cite this article: Garg AK, Garg S. Decoding facial esthetics to recreate an esthetic hairline: A method which includes forehead curvature. *J Cutan Aesthet Surg* 2017;10:195-9.

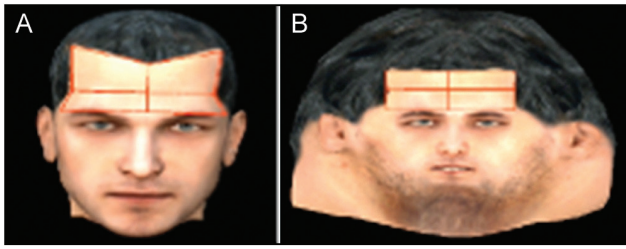


Figure 1: (A) Three-dimensional image of anterior hairline (AHL) on face, (B) two-dimensional image of AHL of face

the three-dimensional (3D) image was converted to a flat two-dimensional (2D) image (without changing distances and maintaining the facial proportion). It was observed that the angulated male hairline pattern was translated into a rectangle [Figure 1A and B].

2. A face having a broader forehead has a shallow FTA, whereas a curved forehead has a deeper FTA. Hence, it can be said that the curvature of one's face/forehead is reflected in one's hairline.

An explanation for this can be found in the following concept:

When a string of specific length is used to mark two points, first on a flat surface and then on a curved surface, the distance in the space between the two points will be more in the case of a flat surface. The curved surface will bring the two points closer in space. This distance lag is proportional to the curvature. The greater the curvature, more the distance lag; hence, a curved forehead will have deeper TPs, whereas a flat forehead will have shallow TPs.

Considering these two observations, we came up with a method to design an AHL in patients with male pattern baldness.

The method is flexible and takes into consideration the grade of baldness and patient's personal requirements. The surgeon's artistic mind can also be incorporated in this method. The result is an esthetic AHL that looks natural and appeals to the patient's satisfaction.

Aim

To establish a user-friendly method to design an AHL in cases of male pattern alopecia.

MATERIALS AND METHODS

Instruments needed are as [Figure 3] follows: A. Flexible measuring tape and B. Skin marker.

1. Reference point A at glabella is taken in between eyebrows.
2. Mark points E and E' on either side near lateral canthus, at 8 cm from point A in the horizontal plane.
3. Mid-frontal point (MFP) B is marked 8 cm (or ± 1 cm depending on the grade of baldness) from glabella (point A) in the mid-vertical plane.

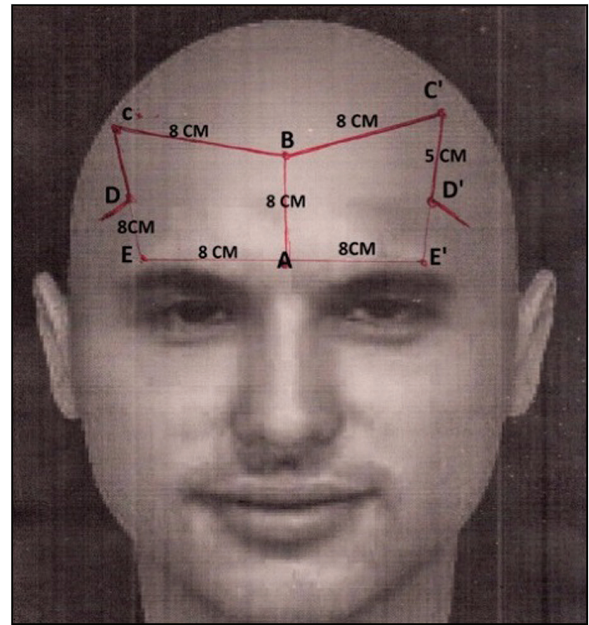


Figure 2: Showing planning of hairline

4. The frontotemporal points (points C and C') are marked on the frontotemporal area at a distance of 8 cm in a horizontal plane from point B and at a distance of 8 cm in a vertical plane from lateral canthus points E and E' (depending on the grade of baldness and patient's choice, there can be a variation of 1 cm). So the frontotemporal point is the point of intersection of two lines taken at 8 cm from the MFP B and 8 cm from the lateral canthus point E.
5. The TP points (D and D') are marked in temporal area on a line joining the frontotemporal peak points (C and C') to the lateral canthus points (E and E'). This line makes an anterior border of the temporal triangle. The TP points D and D' are taken slightly more than halfway toward the lateral canthus usually 5 cm from the frontotemporal points C and C'.

If existing TP points and/or the temporal fringe are touching the line joining the frontotemporal peak to the lateral canthus points, then reconstruction of the TP point is not required.

All the above points are joined as follows:

1. Reconstruction of the AHL—points B to C on one side and B to C' on the other side. So the line joining C to B to C' is the AHL.
2. Reconstruction of the temporal triangle: join point C to point D. These are the anterior temporal lines. Repeat on the other side.

Now draw a line from point D downward posteriorly to join the remaining temporal hair of the sideburn. This completes the temporal triangle. For clarification see Figure 2. All distances are on the surface of the forehead, taken by a flexible measuring tape.

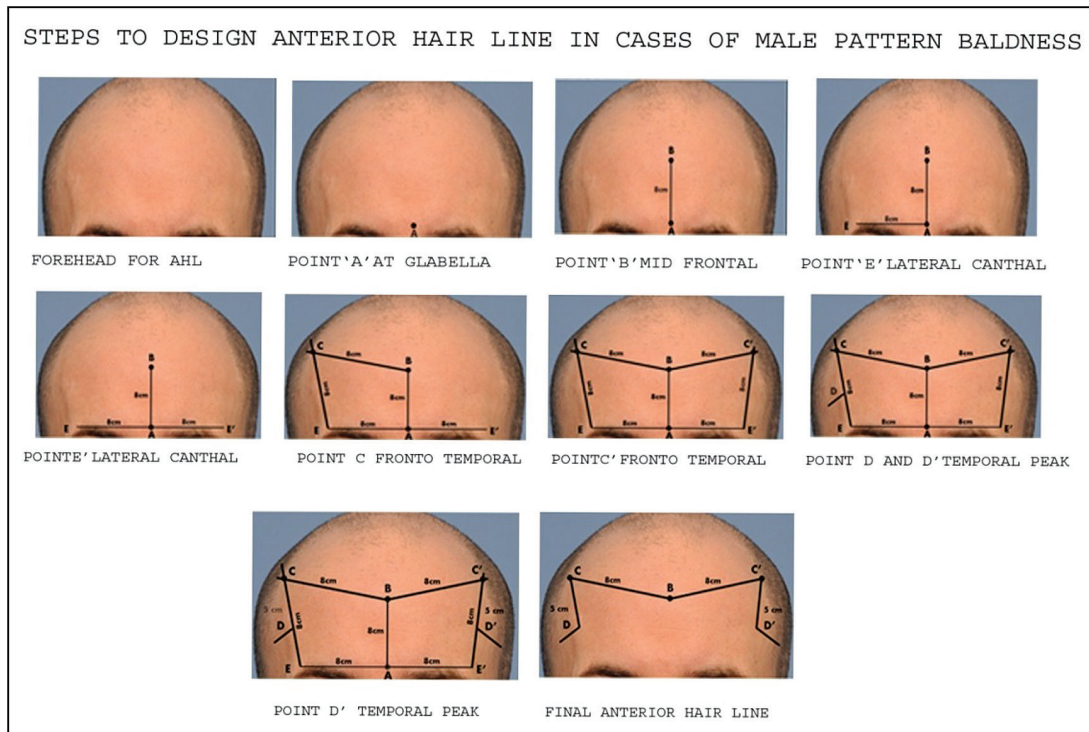


Figure 3: Steps to design hairline

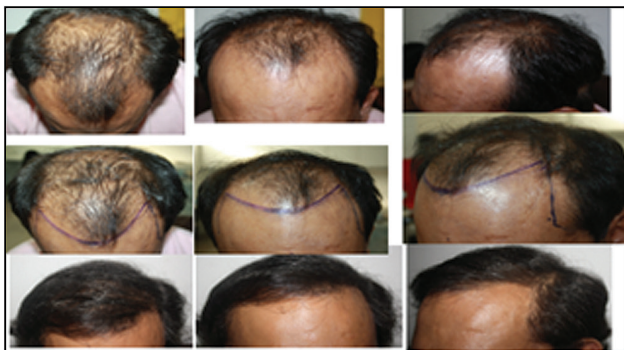

Figure 4: Patient 38 years with Norwood grade VI baldness. Hairline designed as per our method. 3015 grafts implanted

The distances are as follows: $AB = 8\text{ cm}$, $AE = 8\text{ cm}$, $BC = 8\text{ cm}$, $CE = 8\text{ cm}$, and $CD = 5\text{ cm}$

RESULTS

We have conducted a study with 431 cases of male pattern alopecia. The following are the results of this study:

1. Average distance in midline from glabella (A) to AHL point (B) was 7.9 cm.
2. Average distance from glabella (A) to lateral canthus (E) point was 8 cm.
3. Average distance from MFP (B) to frontotemporal point (C) was 7.9 cm.
4. Average distance from frontotemporal point (C) to TP (D) was 5 cm.

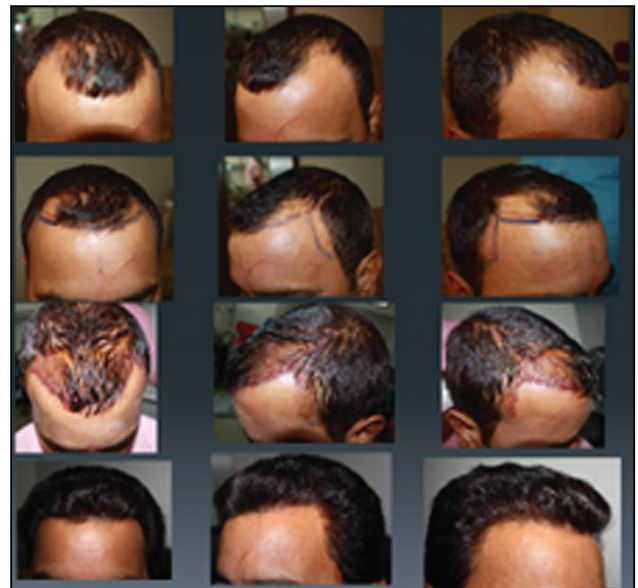

Figure 5: Patient 28 years with Norwood grade III baldness. Hairline designed as per our method. 2456 grafts implanted

A total of 408 patients (94.7%) accepted the designed AHL [example Figures 4, 5 and 6], whereas 23 patients asked for the following changes:

1. 3.7% (16 patients) asked for lowering of the hairline. In 10 cases, AHL was lowered by 0.5 to 1 cm. In six cases, widow's peak was created in midline below the MFP, which made the patient happy without lowering AHL.

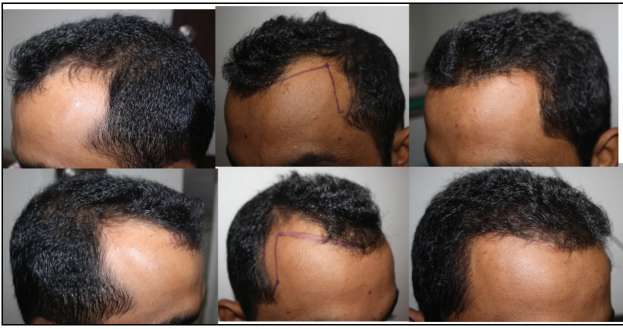

Figure 6: Patient 31 years with Norwood grade III baldness. Hairline designed as per our method. 2112 grafts implanted

2. 1.6% (7 patients) asked for the advancement of the FTA. In such cases, the distance between the MFP B and the frontotemporal point C was reduced by 0.5 to 1 cm.
3. In all the cases, the frontotemporal point C was higher than the MFP B.
4. The FTA was acute, never obtuse.
5. On follow-up, the FTA was showing its normal esthetic appearance rather than a linear figure of an acute angle, the reason being few single thin hair follicle grafts were implanted irregularly.
6. Patient satisfaction was nearly 95% on follow-up. The remaining 5% of the patients said that their hairline should have been lower as it was when they were young and the FTA should have been round.
7. In only three cases, the FTA was corrected at the time of a second hair transplant.

DISCUSSION

The AHL is the boundary of the face.^[4,5] When it recedes, it alters the proportion of the face, finally, compromising facial esthetics; this initiates the patient for its restoration. Hair loss is an ongoing process, so the reconstructed hairline should restore the present as well as future esthetics of the face.^[6-9]

Methods are available to design the AHL in male pattern baldness.^[7,10-12] To design the AHL, two things are important: One is its location and the other is natural characteristics and patterns. For this, we need to understand patterns of balding and facial esthetics.

In male pattern alopecia, there is deepening of the frontotemporal area followed by the recession of the MFP. There can also be thinning of the temporal fringe and then receding of the TP point. In further stages of baldness, there can be lowering of the parietal hump. These events take place in proportion to one another; hence, we need to reconstruct them, maintaining the same proportion in which they have receded, so that the natural characteristic is maintained.^[10,11] AHL receding is parallel to the transverse plane of the forehead, the FTA recedes in a vertical canthal line and the MFP and TP also recede in proportion. The FTA recedes more than the MFP.

There are a few established criteria for the placement of the MFP.^[4,10,11] One is a range of 7 to 11 cm from the glabella. Another is the junction of the horizontal surface of scalp and the vertical plane of the forehead. The third is one-third of the face height as the face is divided into three equal parts. The 7 to 11 cm distance decision depends on the grade of baldness and the availability of donor area and patient's preference. In a patient of grade VII baldness, maximum distance of 11 cm was not accepted by any of our patients. Although in our method, the range is 8 cm \pm 1 cm, which is a relatively much narrower range to decide. Depending upon the grade of baldness the distance AB can be kept 8 cm or less (Norwood grade III to V), or more than 8 cm (Norwood grade VI, VII). However, availability of non scalp donor hair makes it possible to keep the MFP at 8 cm even in grade VII. The option of more than 9 cm was not accepted by anyone.

An esthetic hairline looks parallel or slopes upward when viewed from the side.^[5,10,11,13,14] The apex of the FTA lies on the vertical canthal line. The created frontotemporal point should not be lower than the MFP, and should not be placed posterior to a line drawn vertically from tragus. The FTP should be located anterior to the pre-tragus line. The available method^[1,4] of locating the FTA is a line drawn from the lateral epicanthus superiorly and then posteriorly to meet the existing temporal hair. In mild to moderate degrees of hair loss, it works well, but in more severe degrees of hair loss, where the temporal hair has receded and the lateral fringe has dropped, finding this point will be very difficult because there is no temporal hair with which the lateral epicanthal line can intersect. Visualizing and recreating the "lateral hump" can help in this situation. Hence, in the existing method, designing of the FTA and AHL needs a lot of criteria and measurements.

As per our approach, a single measurement of 8 cm \pm 1 cm from two references point is sufficient to locate all important landmarks needed to design the AHL. To place the FTA, two measurements are needed. One is 8 cm in a horizontal plane from the MFP and the other is 8 cm from a point E near the lateral canthus in the vertical plane. The intersection of these two measurements is the FTA. This FTA is in the vertical canthal line, above the MFP, anterior to pre-tragus line, and the angle is acute. After the growth of transplanted hair, it gives a natural-looking angle. This also facilitates automatically how much the parietal hump has to be lifted. All the existing criteria has already been incorporated and taken well into account, there is no need to remember this separately. This we have done in more than 431 patients and realized that it is a much simpler method to follow.

The placement of the TP point is a point where the two imaginary lines intersect, that is,^[14,15] one line from the base of the nose to the mid-pupil and the other line from the MFP to the ear lobe line. Practically, it is not easy to

draw such lines.^[15] It requires imaginary visual perception and experience. In our approach, it is very convenient to locate the TP point. The TP point lies over the line joining the frontotemporal point and the lateral canthus point, usually 5 cm below the FTP. It is noteworthy that number 8 and 5 are numbers of the Fibonacci sequence and the ratio between 5 and 8 is the golden ratio phi (1.618) and both are Fibonacci numbers. These numbers and this ratio are found everywhere in nature.^[2] This was also seen when we converted 3D image of a face to a 2D image.

Marking hairline zones is the same as described by Shapiro.^[1,12] Our method makes a skeletal frame of the complete anterior border of the hair-bearing scalp separating the face. There is always flexibility for the surgeon's artistic view as well as for the patient's preference. The racial/ethnic variations in shape and size of the head are already taken into account by author's method. A flat forehead will have a flat AHL, whereas a more curved forehead will have an oval or round AHL.

Comparison of the design of the AHL and the placement of the TP point by our method was done by the existing method. The placement of the MFPs and the frontotemporal points, by both the methods, was located at a nearly same location, the difference was in the anterior location of the TP point. When Mayer's^[14] method was followed, the TP point was more anteriorly placed on the forehead, whereas in our method, the point was on an average 0.6 cm posterior to the Mayer temporal point.^[14] The Mayer's temporal point looks better on a young face with a lower AHL. Also, it requires more grafts to be used for temporal reconstruction. The difference seen is that the Mayer's method considers only the size of the face, and not the curvature of the forehead and face.

CONCLUSION

There are obvious advantages of our method, named as "Garg's method of anterior hairline design in cases of male pattern baldness." It gives a skeletal frame of the AHL with a minimum need for visual imagination and

experience for the surgeon. It automatically takes care of the curvature of the forehead. Patient's choice and surgeon's artistic criteria can very well be incorporated in our method of designing of the AHL. The internal divisions of the hairline described as a transition zone, defined zone, macro, and micro irregularities remain the same as described by Shapiro.^[1,12]

REFERENCES

1. Shapiro R. Principles of creating a natural hairline. In: Unger, editor. Hair transplantation. 5th ed. London (UK): Informa Healthcare; 2011. pp. 373-82.
2. Meisner GB. 2014, Jan 12. Facial analysis, and the beauty mask. Phi: The Golden Number. Available from: <https://www.goldennumber.net/>.
3. McCarthy JG. Introduction to plastic surgery. In: Joseph G, editor. Plastic surgery. 2nd ed. Philadelphia (PA): WB Saunders; 1990. p. 30.
4. Shapiro R. Creating a natural hairline in one session using a systemic approach and modern principles of hair line design. *Int J Cosmetic Surg Aesthetic Dermatol* 2001;3:89-99.
5. Beehner M. Where is thy crown, your Majesty? *Hair Transplant Forum Int* 1998;8:18-9.
6. Prawetz MC. Nothing is as important as planning and designing the frontal hairline. *Hair Transplant Forum Int* 1996;6:6.
7. Sajjad K, Stough D. Determination of hairline placement. In: Stough DB, editor. Hair replacement: Medical and surgical. 1st ed. New York (NY): Mosby; 1996. pp. 425-9.
8. Pomerantz M. Creating a hairline. *Hair Transplant Forum Int* 1999;9:184-6.
9. Martinick JH. Hairline placement: Getting it right the first time. *Hair Transplant Forum Int* 1999;9:65-7.
10. Rose PT, Parsley WM. Science of hairline design. In: Haber RS, editor. Procedures in cosmetic dermatology: Hair transplantations. 1st ed. Philadelphia (PA): Saunders-Elsevier; 2006. p. 55.
11. Rose PT. Consideration in establishing the hairline. *Int J Aesth Rest Surg* 1998;1:24-6.
12. Shapiro R. Principles and techniques used to create a natural hairline in surgical hair restoration. *Facial Plast Surg Clin North Am* 2004;12:201-17.
13. Norwood OT. Patient selection, hair transplant design, and hairstyle. *J Dermatol Surg Oncol* 1992;18:386-94.
14. Mayer MI, Perez-Meza D. Temporal points: Classification and surgical techniques for aesthetic results. *Hair Transplant Forum Int* 2002;12:147-58.
15. Simmons C. Five old lines and three new lines that can help when designing a male temporal hairline or when transplanting the frontotemporal apex. *Hair Transplant Forum Int* 2004;4:201-3.