

## Subungual Vascular Malformation with Unusual Presentation

Sir,

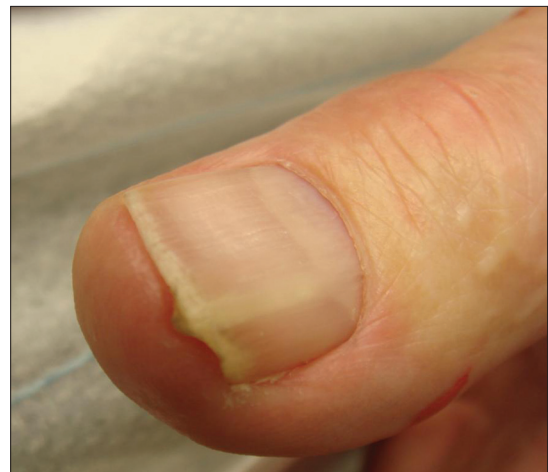The nail unit is a highly specialized structure of skin. Certain tumours and other complaints prefer this unique organ.

We observed a 71-year-old male who presented with a slowly progressive longitudinal ridge-like thickening of the nail plate of his left thumb [Figure 1]. Under pressure the lesion was a bit painful. The nail plate thickening was restricted to the ventral layer adjacent to the nail bed, whereas the visible dorsal surface was unaffected. Our primary suspicions were onychomatixoma, onychopapilloma, or glomus tumour.

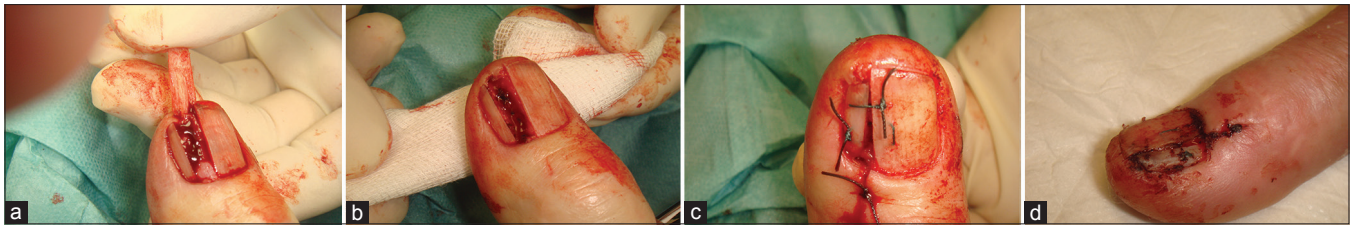
We performed nail surgery with a proximal finger block using 1% xylocaine. The plate was cut longitudinally along the ridge. Then we removed the thickened part starting from underneath the proximal nail fold by the help of a nail elevator [Figure 2a]. A soft tissue tumour was found in the lateral part of the lunula that extended to the tissue of the proximal nail fold. After incision of the proximal fold and further meticulous preparation, the tumour could be completely surgically removed leaving the proximal matrix untouched [Figures 2b and c]. The remaining nail plate was sutured in the midline as a protective shield of the wound bed [Figure 2c]. We performed antibiotic prophylaxis with 2 × 500 mg/d cefuroxim. Healing was uneventful [Figure 2d].

Histopathological investigation revealed an angiomatous malformation composed of venous and arterial vessels [Figures 3a and b]. The diagnosis of an acquired digital arterio-venous malformation (ADAVM) was made.

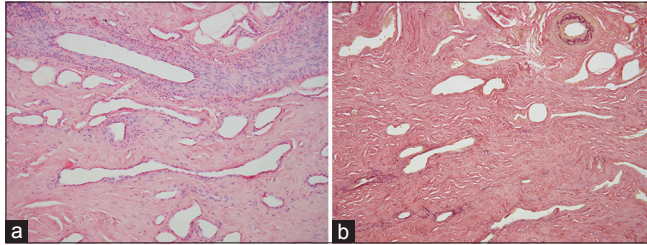
ADAVM is a rare condition occurring either as inherited or acquired type. Characteristically there is an abnormal connection between arterioles and venules of the finger fed by the digital vessels.<sup>[1,2]</sup> The most common presentation of ADAVM is small, slightly raised dark-red macules on the distal parts of fingers. The subungual



**Figure 1:** Lateral subungual longitudinal thickening of the nail plate



**Figure 2:** Surgery of the nail. (a) Partial avulsion of the nail plate. In the proximal nail bed a soft tumour is visible. (b) Complete excision of the proximal nail bed tumour. Thereafter, a longitudinal cut was made to remove the remaining part of the tumor underneath the proximal nail fold. (c) Suturing of the proximal nail fold and use of nail plate as a protective shield. (d) Two weeks later with uncomplicated healing



**Figure 3:** Histopathological findings: (a) Haematoxylin-stained tissue samples with dilated vessels. (b) Elastica-stain demonstrates elastic fibres in thickened vessel walls corresponding to arterial vessels (a and b - ×10)

occurrence has not been reported before.<sup>[1-4]</sup>

This makes our case unique. The lunula is a whitish half-moon shaped structure known for a poor vascularisation compared to other parts of the nail organ. Magnetic resonance imaging (MRI) investigations have shown a loose connective tissue with reticular and subdermal vascular networks that develop larger meshes.<sup>[5,6]</sup> This can dramatically change in case of trauma or systemic inflammation.<sup>[7,8]</sup> We suppose that trauma might have been responsible for ADAVM in our patient.

Treatment for finger tip ADAVM can be realized by neodymium: Yttrium-aluminium-garnet laser or surgery.<sup>[7,8]</sup> Surgery was preferred in our case with unusual presentation supporting histological examination.

**Uwe Wollina**

*Department of Dermatology and Allergology, Academic Teaching Hospital Dresden-Friedrichstadt, Dresden, Germany  
E-mail: uwollina@web.de*

**REFERENCES**

1. Yang CH, Ohara K. Acquired digital arteriovenous malformation: A report of three cases and study with epiluminescence microscopy. *Br J Dermatol* 2002;147:1007-11.
2. Cuesta Montero L, Soro P, Bañuls J. Acquired digital arteriovenous malformation: Clinical, dermoscopy, ultrasound and histological study. *Eur J Dermatol* 2012;22:138-9.
3. Bekhor PS, Ditchfield MR. Acquired digital arteriovenous malformation: Ultrasound imaging and response to long-pulsed neodymium: Yttrium-aluminium-garnet treatment. *J Am Acad Dermatol* 2007;56:S122-4.
4. Kadono T, Kishi A, Onishi Y, Ohara K. Acquired digital arteriovenous malformation: A report of six cases. *Br J Dermatol* 2000;142:362-5.
5. Wolfram-Gabel R, Sick H. Vascular networks of the periphery of the fingernail. *J Hand Surg Br* 1995;20:488-92.
6. Drapé JL, Wolfram-Gabel W, Idy-Peretti I, Baran R, Goettmann S, Sick H, *et al.* The lunula: A magnetic resonance imaging approach to the subnail matrix area. *J Invest Dermatol* 1996;106:1081-5.
7. Richert B, Di Chilacchio N, Haneke E. *Nail Surgery*. London, New York: Informa Healthcare; 2010.
8. Wollina U, Barta U, Uhlemann C, Oelzner P. Lupus erythematosus-associated red lunula. *J Am Acad Dermatol* 1999;41:419-21.

Access this article online	
<b>Quick Response Code:</b> 	<b>Website:</b> <a href="http://www.jcasonline.com">www.jcasonline.com</a>
	<b>DOI:</b> 10.4103/0974-2077.104921