

# Transungual Surgical Excision of Subungual Glomus Tumour

**Background:** Glomus tumours are rare vascular tumours arising subungually in fingernails. Surgical excision provides histopathologic diagnosis and rapid resolution of symptoms. **Objective:** Present study was aimed at delineating common presentations and long-term treatment outcome of this rare subungual tumour. **Patients and Methods:** The clinical features and imaging results for 10 patients with subungual glomus tumours were recorded. All were treated with transungual excision. Per-operative findings and, treatment outcomes were recorded and analysed. **Results:** Females outnumbered males with average age being  $33.3 \pm 7.55$  years. Presenting symptoms were severe pain (100%); nail-plate discoloration and onycholysis. X-ray was normal in 70%, though a magnetic resonance imaging done for five, helped visualise the lesion in three patients. The tumour involved nail bed in five cases and matrix in five, with an average size being  $6.1 \pm 2.13$  mm (range 3-11 mm). An average follow-up of 16.8 months (range 8-24 months) was largely uneventful with longitudinal ridging in two cases and recurrence in two (both attributed to a sister lesion). **Conclusion:** Subungual glomus tumours have characteristic clinical presentation. Imaging is helpful pre-operatively but has a low success rate. Transungual surgical excision is safe and effective, allowing better visualisation, easy exploration and minimal long-term complications.

**KEYWORDS:** Hildreth test, Love's sign, magnetic resonance imaging, nail plate repositioning

## INTRODUCTION

Glomus tumour is considered to be a hamartoma developing from the neuromyoarterial glomus body, which is a highly specialised arteriovenous anastomosis responsible for thermoregulation. The glomus body consists of an afferent arteriole, a tortuous arteriovenous anastomosis, a system of collecting veins and a neurovascular reticulum that regulates the flow of blood through the anastomosis.<sup>[1]</sup> Glomus bodies are present in the reticular dermis throughout the body, but are highly concentrated in the digits, palms and soles. Reflecting a similar distribution, glomus tumours may affect any area of the body, but up to 75% occur in the hand and approximately 65% of these are in the fingertips,

particularly in the subungual space.<sup>[2,3]</sup> Diagnosis is mainly on clinical grounds although imaging has been reported to be useful in localising the lesion and determining its size. Magnetic resonance imaging (MRI) has been reported to be the most useful modality in this regard and can pick highly vascular lesions as small as 2 mm.<sup>[4]</sup> A complete surgical excision is the only effective treatment modality; however, the risk of post-operative nail deformity and recurrences are the major concerns in this regard. We present our experience with the management of subungual glomus tumours using the transungual excision approach.

## PATIENTS AND METHODS

### Patients

A total of 10 patients presenting with a clinically suspected subungual glomus tumour, over a period of 4 years (2009-2012) were included in this study. All patients consented to inclusion in the study and agreed to long-term follow-up. The principles of the 1975 Declaration of Helsinki with respect to the ethical treatment of study subjects were followed throughout the study. A record of clinical history and any apparent nail changes was kept [Figure 1a-d]. Plain radiographs

Video will be submitted shortly

Access this article online

Quick Response Code:



Website:  
www.jcasonline.com

DOI:  
10.4103/0974-2077.123401

Chander Grover, Ananta Khurana, Rajat Jain<sup>1</sup>, Vinita Rathi<sup>2</sup>

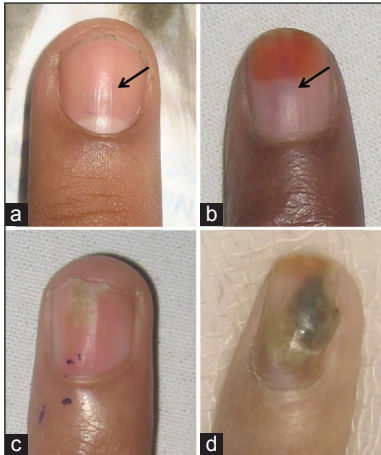Departments of Dermatology, and <sup>2</sup>Radiodiagnosis, University College of Medical Sciences and GTB Hospital, <sup>1</sup>Department of Radiodiagnosis, Maulana Azad Medical College and LNH Hospital, New Delhi, India

Address for correspondence:

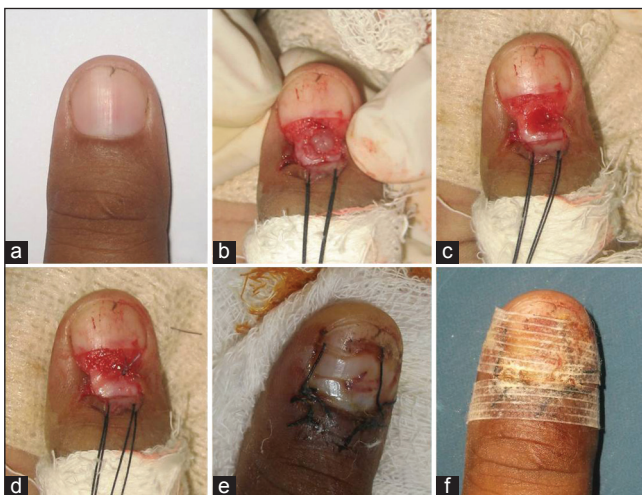Dr. Chander Grover, 420-B, Pocket 2, Mayur Vihar, Phase-1, New Delhi - 110 091, India. Email: chandergroverkubba@rediffmail.com

were done for all cases. An MRI was done for five of these due to resource constraints.

The lesion was localised on the basis of clinical signs that are the point of maximal tenderness (Love's test); the point of visible erythema of the nail plate; or the painful



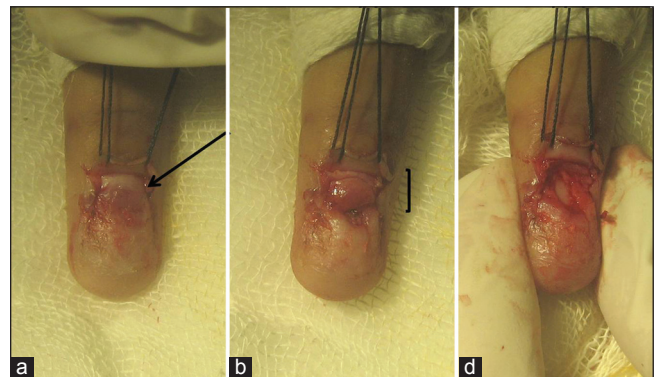
**Figure 1:** Varying clinical presentations of subungual glomus tumour. All the patients presented with complaints of pain in the involved digit with point tenderness (shown with an arrow) and cold sensitivity (a) Patient 2 presenting with severe pain with an apparently normal nail plate, (b) Patient 3 with a diffuse, erythematous to bluish discoloration visible over the nail plate surface, (c) Patient 4 with frank distal onycholysis, along with a larger erythematous, diffuse area visible over the nail plate. Slight swelling over the proximal nail fold can be appreciated, (d) Patient 6 presented with distal and lateral onycholysis, nail plate discoloration, subungual debris and partial destruction



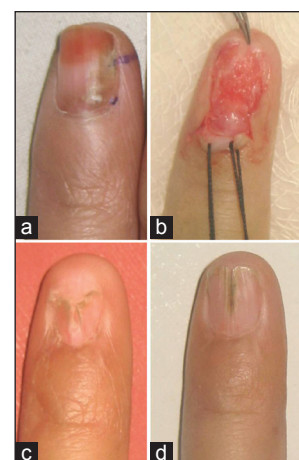
**Figure 3:** (a-f) Patient 10 presenting with subungual glomus tumour involving the thumb. Pre-operative localization with magnetic resonance imaging helped confirm the location of the tumour. Partial proximal nail avulsion is done. The proximal nail fold (PNF) is retracted and the tumour is removed. The resultant defect and the PNF are sutured. The avulsed nail plate is repositioned and secure dressing is applied

base of an erythronychial band. The surgical site was prepared antiseptically.

- The digit to be operated was anaesthetized with proximal nerve block using the 2% lignocaine hydrochloride with epinephrine (1:2,00,000) - 1% of lidocaine hydrochloride solution
- Digital exsanguination and tourniquet for relatively avascular operating field was done
- The nail plate overlying the tumour was carefully removed. For nail matrix glomus, the proximal nail fold (PNF) was also retracted (lateral release incisions and stay sutures) as shown in Figures 2-4
- As seen in Figure 5, blunt dissection with fine forceps enabled separation of the tumour from surrounding tissues in seven patients. Punch excision of a small lesion was performed in two cases [Figure 6], while in a single patient a longitudinal, fusiform excision was done [Figure 7]
- Subsequent defect was primarily repaired with 6-0 absorbable sutures

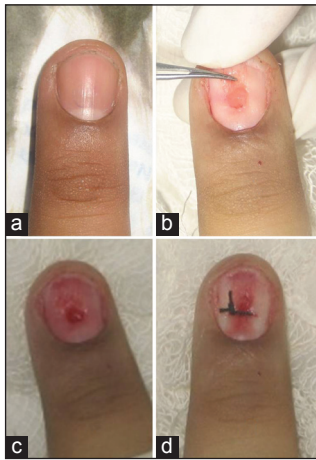


**Figure 2:** (a-c) Patient 4 presenting with a large subungual glomus tumour (11 mm) involving the nail matrix. The lesion is exposed with the help of nail plate avulsion and retraction of proximal nail fold. Post excision defect can be seen in Figure 2c

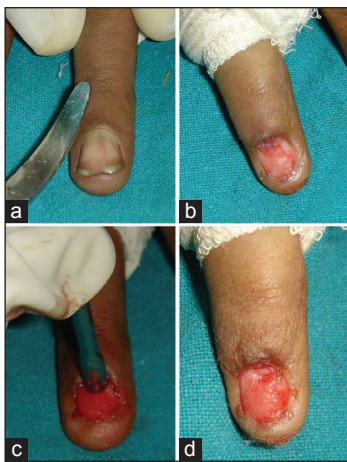

**Figure 4:** (a-d) A large subungual glomus tumour arising from the matrix is removed and the resultant defect is primarily repaired. However, on follow-up, a residual median nail plate defect is seen which persists in the distal part even on 1 year follow-up

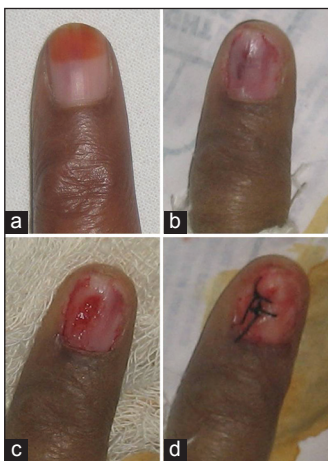



**Figure 5: (a-d)** A relatively small nail bed glomus tumour, removed with the help of blunt dissection. The surgical defect is closed in a longitudinal fashion (Patient 2)



**Figure 6: (a-d)** A more proximal, smaller lesion is excised with the help of a punch. The residual defect is small and could be closed primarily (Patient 1)



**Figure 7: (a-d)** A larger nail bed glomus tumour is excised in a longitudinal fashion. The resultant longitudinal defect is also closed primarily (Patient 3)

- The avulsed nail plate was trimmed and repositioned wherever possible [Figure 3]
- The lateral nail fold (LNF), if retracted was sutured back with 4-0 non absorbable sutures
- Dressing was done using antibiotic cream and gauze. The excised tissue was sent for histopathological confirmation.

Patients returned for post-operative visits at 2 days and then on a weekly basis until the site healed. Any non-absorbable sutures used were removed at the end of the 1<sup>st</sup> week. After complete healing, monthly review was done for assessing recurrence and post-operative nail plate deformity.

## RESULTS

Of the 10 patients included in the study, 7 were females and 3 were males. Age at presentation ranged from 24 years to 47 years, with a mean age of  $33.3 \pm 7.55$  years among females and 40 years for males. Most of the patients had glomus tumour involving the non-dominant hand (9 out of 10) with a single female patient having involvement of the dominant right hand. Among the digits involved, five patients had lesion on the fourth digit; three had involvement of the fifth digit, while two patients had thumb involvement. The duration of complaints at presentation ranged from 1 to 16 months (average duration 6.5 months). The details of the patients are summarised in Table 1.

On examination, Love’s sign was present in all patients (100%), while Hildreth’s test was positive in 4 (40%). Nail plate showed variable manifestations, with a longitudinal red band (erythronychia) being the most common, seen in 50% of cases. Other nail plate signs included subtle tumefaction in three, distal onycholysis in one, distal and lateral onycholysis in two and nail plate discoloration in two, sub-ungual hyperkeratosis in one and thinning in one [Figure 1]. Importantly, the nail plate was normal in three of our patients [Figure 1a]. Secondary nail fold features in the form of erythema and tumefaction were noticed in five cases (on the PNF in three cases and LNF in two cases).

X-ray of the involved digit was done for all the cases and it showed only cortical thinning in three patients and was normal in the rest. MRI was done in five affording patients. Only in three of these, the tumour could be well visualized (Table 1). MRI in these three patients showed the classical findings of low signal intensity on T1-weighted images, marked hyper intensity on T2-weighted images and strong enhancement after the injection of gadolinium-based contrast material [Figures 8a-b and 9a-e].

**Table 1: Clinical presentation and surgical outcome of patients with subungual glomus tumours involving the fingernails (n=10)**

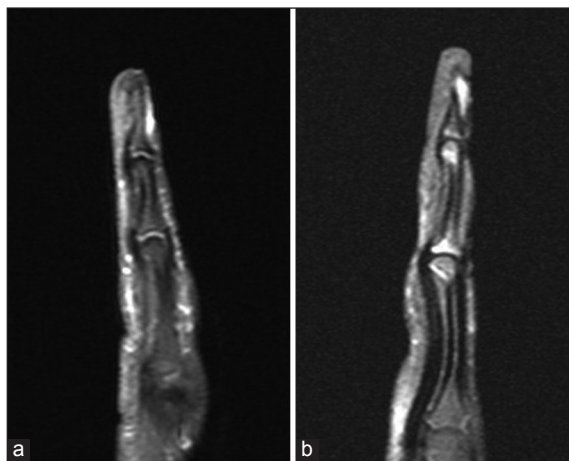
Sex	Age (in years)	Digit involved	Duration of symptoms (in months)	Clinical presentation (all the cases had pain, point tenderness and cold sensitivity)	Digital X-ray	MRI of the involved digit	Lesion location with surgical approach	Size of the excised lesion (in mm)	Duration of follow-up (in months)	Post-operative outcome
F	43	4-DH	16	Erythema and swelling visible over nail plate	NAD	Not done	Nail bed lesion with transungual, punch excision [Figure 6]	3 mm	14	No deformity, no recurrence
M	35	4-NDH	4	Only pain, no visible changes [Figure 1a]	NAD	Not done	Nail bed lesion with transungual, blunt excision [Figure 5]	5 mm	12	No deformity, no recurrence
F	47	5-NDH	7	Erythema and swelling visible over nail plate [Figure 1b]	NAD	Done, but lesion not visualized	Nail bed lesion with transungual, longitudinal excision [Figure 7]	7 mm	8	No deformity, no recurrence
F	28	4-NDH	1	Distal onycholysis, erythema and swelling over nail plate and proximal nail fold [Figure 1c]	Cortical thinning	Not done	Nail matrix lesion with transungual, blunt excision along with proximal nail fold retraction [Figure 2]	11 mm	12	Recurrence in a different quadrant, excised subsequently
F	29	4-NDH	12	Nail plate erythema	NAD	Done, but lesion not visualized	Nail matrix lesion with transungual, blunt excision along with proximal nail fold retraction	8 mm	12	No deformity, no recurrence [Figure 10]
F	25	5-NDH	6	Distal and lateral onycholysis, subungual hyperkeratosis, nail plate discoloration and swelling [Figure 1d]	Cortical thinning	Done, lesion visualized as a well demarcated markedly enhancing lesion below the nail plate in the distal phalanx [Figure 8]	Nail matrix lesion with transungual, blunt excision along with proximal nail fold retraction	7 mm	12	Post-operative residual nail deformity [Figure 4]
M	30	1-NDH	5	No visible changes	NAD	Not done	Nail bed lesion with transungual, punch excision	3 mm	5	Recurrence in a different quadrant, excised subsequently, post-operative residual nail deformity
F	24	5-NDH	6	Distal and lateral onycholysis, nail plate discoloration and swelling	Cortical thinning	Done, lesion visualised as hypointense on T1 and hyperintense on T2; located beneath the nail plate with associated cortical thinning [Figure 8]	Nail matrix lesion with transungual, blunt excision along with proximal nail fold retraction	6 mm	12	No deformity, no recurrence
M	37	4-NDH	4	No visible changes	NAD	Not done	Nail bed lesion with transungual, blunt excision	5 mm	12	No deformity, no recurrence

*(Table 1 Continued)*

**Table 1: (Continued)**

Sex	Age (in years)	Digit involved	Duration of symptoms (in months)	Clinical presentation (all the cases had pain, point tenderness and cold sensitivity)	Digital X-ray	MRI of the involved digit	Lesion location with surgical approach	Size of the excised lesion (in mm)	Duration of follow-up (in months)	Post-operative outcome
F	35	1-NDH	4	Nail plate thinning with partial erythronychia [Figure 3]	NAD	Done, lesion visualized as a well demarcated lesion, hypointense on T1 and hyperintense on long TR sequences [Figure 9]	Nail matrix lesion with transungual, blunt excision along with proximal nail fold retraction	6 mm	14	No deformity, no recurrence

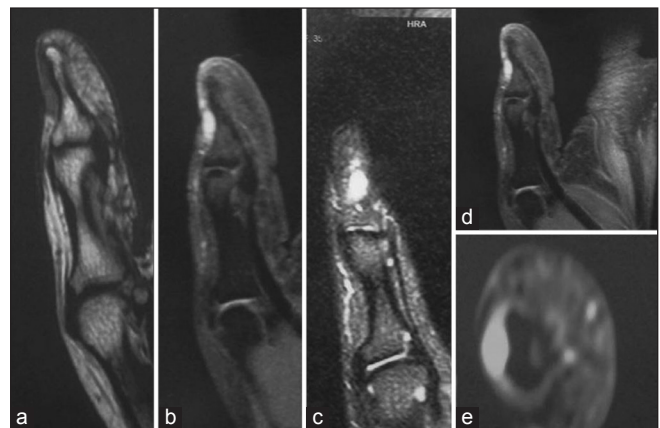
DH: Dominant hand, NDH: Non-dominant hand, NAD: No abnormality detected, MRI: Magnetic resonance imaging



**Figure 8: (a and b) Sagittal gadolinium-enhanced fat-saturated T1-weighted MR images, reveal a well-defined mass with homogenous enhancement beneath the nail plate (Patients 6 and 8)**

Surgical excision was performed by transungual route in all patients. The tumour was located over the nail bed in five and nail matrix in the other five patients. The excised tumours ranged in size from 3 mm to 11 mm (mean 6.1 mm). The post-operative period was uneventful, except for a mild continuous pain, persisting for about a week, which was reported by all the patients. The excised lesion was sent for histopathological evaluation which confirmed the clinical diagnosis in all 10 patients.

A prolonged post-operative follow-up was done for all cases. The period of follow-up ranged from 5 months to 14 months (mean follow-up duration of 9.9 months). Only two of our patients went on to develop a persistent longitudinal ridging of the nail plate as a residual defect post-surgery [Figure 4]. Rest of the eight patients did not develop any permanent, visible nail abnormality [Figure 10]. A recurrence of



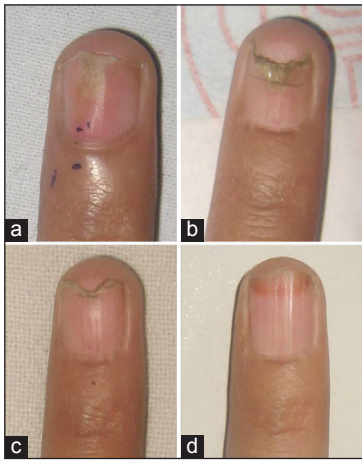
**Figure 9: (a-e) Glomus tumour in patient 10 presenting with a painful left thumb (a) Sagittal T1-weighted magnetic resonance (MR) image shows a focal lobulated hypointense lesion in the nail bed of the first distal phalanx (b and c) Sagittal T2-weighted MR (b) and short TI inversion recovery (c) Image shows the tumour with high signal intensity, (d and e) On gadolinium-enhanced fat-saturated T1-weighted MR image, the tumour shows prominent enhancement with a homogeneous pattern**

pain was reported in the same digit in two cases after a period of 5 and 12 months respectively; however, in both cases, it was attributed to an isolated lesion arising in a different quadrant as compared to the one previously operated. Both the recurrences were again dealt with surgically.

**DISCUSSION**

Glomus tumour was first described by Wood in 1812 and was named by Masson in 1924.<sup>[5]</sup> Although, the exact aetiology of glomus tumour is unknown, it has been proposed that a structural weakness in the glomus body could lead to reactive hypertrophy following trauma; or alternatively, they may represent hamartomas in which individual components are hypertrophied.<sup>[5]</sup> The glomus





**Figure 10:** (a-d) Post-operative growth of a normal nail plate. The residual defect is seen to grow out distally and an essentially normal nail plate can be seen at 8 months of follow-up

cells are specialized smooth muscle cells derived from Zimmerman pericytes, particularly concentrated around the dilated vascular spaces. In addition, nerve fibres and mast cells may be present in increased numbers. The tumour is exquisitely sensitive to changes in temperature which leads to contraction of myofilaments. This results in an increase in intracapsular pressure, transmitted by unmyelinated nerve fibres, leading to the perception of pain.<sup>[6]</sup>

Glomus tumours most commonly affect patients in third to fifth decades of life, as was also seen in our study, although cases have been described in all age groups.<sup>[7]</sup> A female predominance has been reported previously,<sup>[7]</sup> as was seen in our series as well. Patients with subungual glomus tumours often present to multiple specialties and quite often the diagnosis is delayed; hence, the duration of symptoms at presentation may be long. In our patients, however, the mean duration of symptoms was relatively less at 6.5 months (range 1-16 months). This may be because of the structure of our health system where patients can directly reach specialists, without having to be referred step by step.

Diagnosis of glomus tumours can largely be made on the basis of clinical signs and symptoms. In a series of 51 patients with glomus tumours of the hand, Van Geertruyden *et al.* noted spontaneous pain in 80% of patients, sensitivity to touch in 100% of patients, cold sensitivity in 63% and blue-reddish discoloration in 29% and nail deformity in 33%.<sup>[8]</sup> Pain may be described by the patient as severe and paroxysmal, often radiating to shoulder. Severe pain was the presenting feature in all our patients and all of them also had significant cold sensitivity. However, three of our patients had no signs suggestive of a subungual mass and only presented with

pain localised to subungual region. This is the perfect setting for misdiagnosis.

Love's sign and Hildreth's test are often helpful in achieving the diagnosis. Love's sign refers to severe localized tenderness elicited on applying pressure with a pinhead, along with relief of pain when the pressure is removed. Hildreth's test is performed by elevating the patients' arm to exsanguinate it. A tourniquet is placed over arm and inflated to 250 mm Hg. This causes reduction or abolition of lesional pain and tenderness. A test is positive when releasing the cuff causes a sudden return of pain. According to Bhaskaranand and Navadgi's series of 18 patients, Love's test was 100% sensitive and 78% accurate, while Hildreth's test was 71.4% sensitive, 100% specific and 78% accurate.<sup>[9]</sup> All ten of our patients (100%) also tested positive for Love's sign and Hildreth's test was positive in 40% of cases.

Radiology has a small but definite role in the management of glomus tumours. X-ray may reveal thinning or erosions of the underlying cortical bone, especially with larger lesions; however, the frequency of this observation ranges from less than 30% to up to 60% of cases in various series.<sup>[5]</sup> It may be useful for differentiating glomus tumours from subungual exostoses.<sup>[10,11]</sup> We found cortical thinning in three of our patients (30%), two of whom had lesions of size 6 mm each and the third had an 11 mm tumour. Ultrasonography has also been used to localise and assesses the size of glomus tumours pre-operatively. These are visible as well-circumscribed hypoechoic masses. The technique has limited utility for small, flattened lesions and in the artifacts that may be generated by the nail preventing glomus tumours being distinguished from other hypoechoic masses.<sup>[5]</sup> Doppler ultrasonography can identify low signals within the hypoechoic mass and is preferred over standard ultrasonography. Chen *et al.* have reported 100% detection rates and no false negative results with Doppler imaging in one series.<sup>[12]</sup>

MRI is a non-invasive technique that is most useful in evaluating glomus tumours pre-operatively. It can detect lesions as small as 2 mm. The lesions appear as hypointense on T1 and hyperintense on T2 images, with marked enhancement on injection of gadolinium contrast. A nidus appearance with a high signal central dot surrounded by a zone of less signal intensity is characteristic of glomus tumours.<sup>[13]</sup> Al-Qattan *et al.* reported a sensitivity of 90% and positive predictive value of 97% in their series of 42 patients. However, specificity was only 50% and negative predictive value 20%.<sup>[13]</sup> MR angiography gives a typical appearance of strong enhancement in the arterial phase and tumour blush that increases in size in the delayed

phase.<sup>[1,14]</sup> MRI can also be useful for assessment of patients with recurrence or incomplete resolution of symptoms following surgery.<sup>[15]</sup> However the high cost precludes its routine use. In our study, MRI was not helpful in detecting a glomus tumour, later confirmed pathologically, in three of the five patients in whom it was performed.

Histologically, glomus tumours are made up of three components: Glomus cells, vascular structures and smooth muscle cells; therefore, according to the predominant component, they can be categorised into three types. Solid glomus tumours (75% of cases) comprise of a few vascular structures and very few, if any, smooth muscle cells. Glomangiomas (20% of cases) have a prominent vascular component, whereas glomangiomyomas (5% of cases) show a predominance of vascular structures and smooth muscle cells.<sup>[5,16]</sup> Originally, glomus cells were believed to arise from endothelial cells; however, recent histologic evidence points towards their being a type(s) of smooth muscle cell.<sup>[17-19]</sup> Histochemical staining reveals glomus cells to be positive for vimentin and alpha-smooth muscle actin, but negative for desmin.<sup>[20,21]</sup> All our patients showed the typical findings associated with solid glomus tumours, but immunochemistry could not be performed because of resource constraints.

Treatment of glomus tumours is purely surgical. However, the major concerns are the risk of nail deformity and recurrences and rates of recurrence reported by various authors range from 4% to 15%.<sup>[8,22-24]</sup> Incomplete surgical removal may lead to persistent/recurring pain. However, it is now believed that most recurrences result from pre-existing synchronous satellite lesions not seen at the time of initial surgery and which become larger and symptomatic with time.<sup>[25]</sup> This was demonstrated well by Gandhi *et al.* in five patients of recurring glomus tumours, all of whom developed lesions in different locations of the same digit.<sup>[25]</sup> MRI may be useful in localising the recurrent lesions. Recurrence developed in two of our cases (20%). In both cases, the recurrent lesion was located in the same nail, however, in a different quadrant when compared to the previously excised one.

Two main approaches for the surgical excision of glomus tumours are – transungual and lateral (lateroungual or laterodigital Keyser-Littler approach).<sup>[26]</sup> We used the transungual approach in all our patients, as it provides for a better view of the whole subungual region and makes precise and complete excision possible. It is also useful when the exact location is not known beforehand. If the lesion is believed to be involving the nail matrix, an eponychial flap has to be raised allowing for a clearer view. It is prudent to inspect the whole subungual region for reasons mentioned above. Previous reports

have indicated a higher rate of the nail plate deformity with transungual approach when compared to lateral approaches.<sup>[26]</sup> This may be because of the nail bed incongruities created during the excision or formation of adhesions between matrix and PNF.<sup>[26]</sup> Careful handling of tissues during surgery and meticulous repair of the defect created by excision can largely prevent this outcome. This fact is substantiated in our series of cases, where only two patients developed a post-operative longitudinal ridging of the nail plate, owing largely to the initial large size of the lesions. Nail plate repositioning has also been used as a method to prevent adhesions of the eponychium to the matrix. It also favours repair of the nail bed and reduces the pain occurring when dressings are changed, as the wound is kept covered.<sup>[26]</sup> This proved to be helpful in our patients. Li *et al.* have reported the use of autologous fat grafting to repair the defect in nail bed with good results.<sup>[27]</sup> We simply used 6-0 absorbable sutures to close the defect and found encouraging outcomes as mentioned previously.

## CONCLUSION

The diagnosis of subungual glomus tumour is largely clinical. Radiological examination, including MRI may not offer much help in the majority of cases. Complete surgical excision offers the only prospect of complete cure. We found transungual approach to be a simple procedure, which can reduce the chances of recurrence by allowing examination of the entire subungual region. Nail deformities are minimal if adequate care is taken during surgery.

## REFERENCES

1. Baek HJ, Lee SJ, Cho KH, Choo HJ, Lee SM, Lee YH, *et al.* Subungual tumors: Clinicopathologic correlation with US and MR imaging findings. *Radiographics* 2010;30:1621-36.
2. Fornage BD. Glomus tumors in the fingers: Diagnosis with US. *Radiology* 1988;167:183-5.
3. Theumann NH, Goettmann S, Le Viet D, Resnick D, Chung CB, Bittoun J, *et al.* Recurrent glomus tumors of fingertips: MR imaging evaluation. *Radiology* 2002;223:143-51.
4. Koç O, Kivrak AS, Paksoy Y. Subungual glomus tumour: Magnetic resonance imaging findings. *Australas Radiol* 2007;51 Spec No.:B107-9.
5. Samaniego E, Crespo A, Sanz A. Key diagnostic features and treatment of subungual glomus tumor. *Actas Dermosifiliogr* 2009;100:875-82.
6. Rohrich RJ, Hochstein LM, Millwee RH. Subungual glomus tumors: An algorithmic approach. *Ann Plast Surg* 1994;33:300-4.
7. Song M, Ko HC, Kwon KS, Kim MB. Surgical treatment of subungual glomus tumor: A unique and simple method. *Dermatol Surg* 2009;35:786-91.
8. Van Geertruyden J, Lorea P, Goldschmidt D, de Fontaine S, Schuind F, Kinnen L, *et al.* Glomus tumours of the hand. A retrospective study of 51 cases. *J Hand Surg Br* 1996;21:257-60.
9. Bhaskaranand K, Navdag BC. Glomus tumours of the hand. *J Hand Surg* 2002;27B:229-31.
10. Kale SS, Rao VK, Bentz ML. Glomus tumor of the index finger. *J Craniofac Surg* 2006;17:801-4.

11. Takemura N, Fujii N, Tanaka T. Subungual glomus tumor diagnosis based on imaging. *J Dermatol* 2006;33:389-93.
12. Chen SH, Chen YL, Cheng MH, Yeow KM, Chen HC, Wei FC. The use of ultrasonography in preoperative localization of digital glomus tumors. *Plast Reconstr Surg* 2003;112:115-9.
13. Al-Qattan MM, Al-Namla A, Al-Thunayan A, Al-Subhi F, El-Shayeb AF. Magnetic resonance imaging in the diagnosis of glomus tumours of the hand. *J Hand Surg Br* 2005;30:535-40.
14. Drapé JL. Imaging of the tumors of the perionychium. *Hand Clin* 2002;18:655-70;671.
15. Drapé JL, Idy-Peretti I, Goettmann S, Wolfram-Gabel R, Dion E, Grossin M, *et al.* Subungual glomus tumors: Evaluation with MR imaging. *Radiology* 1995;195:507-15.
16. Gombos Z, Zhang PJ. Glomus tumor. *Arch Pathol Lab Med* 2008;132:1448-52.
17. Conant MA, Wiesenfeld SL. Multiple glomus tumors of the skin. *Arch Dermatol* 1971;103:481-5.
18. Laymon CW, Peterson WC Jr. Glomangioma (glomus tumor). A clinicopathologic study with special reference to multiple lesions appearing during pregnancy. *Arch Dermatol* 1965;92:509-14.
19. Taaffe A, Barker D, Wyatt EH, Bury HP. Glomus tumours: A clinicopathological survey. *Clin Exp Dermatol* 1980;5:219-25.
20. Tarnowski WM, Hashimoto K. Multiple glomus tumors. An ultrastructural study. *J Invest Dermatol* 1969;52:474-8.
21. Kaye VM, Dehner LP. Cutaneous glomus tumor. A comparative immunohistochemical study with pseudoangiomatous intradermal melanocytic nevi. *Am J Dermatopathol* 1991;13:2-6.
22. Maxwell GP, Curtis RM, Wilgis EF. Multiple digital glomus tumors. *J Hand Surg Am* 1979;4:363-7.
23. Carroll RE, Berman AT. Glomus tumors of the hand: Review of the literature and report on twenty-eight cases. *J Bone Joint Surg Am* 1972;54:691-703.
24. Gandon F, Legaillard P, Brueton R, Le Viet D, Foucher G. Forty-eight glomus tumours of the hand. Retrospective study and four-year follow-up. *Ann Chir Main Memb Super* 1992;11:401-5.
25. Gandhi J, Yang SS, Hurd J. The anatomic location of digital glomus tumor recurrences. *J Hand Surg Am* 2010;35:986-9.
26. Tada H, Hirayama T, Takemitsu Y. Prevention of postoperative nail deformity after subungual glomus resection. *J Hand Surg Am* 1994;19:500-3.
27. Li TS, Choong MY, Wu CI, Chen HC, Chung KC. Autologous fat graft to restore nail bed contour following resection of a subungual glomus. *J Hand Surg Am* 2011;36:726-8.

**How to cite this article:** Grover C, Khurana A, Jain R, Rathi V. Transungual surgical excision of subungual glomus tumour. *J Cutan Aesthet Surg* 2013;6:196-203.

**Source of Support:** Nil. **Conflict of Interest:** None declared.

#### Announcement

### “QUICK RESPONSE CODE” LINK FOR FULL TEXT ARTICLES

The journal issue has a unique new feature for reaching to the journal’s website without typing a single letter. Each article on its first page has a “Quick Response Code”. Using any mobile or other hand-held device with camera and GPRS/other internet source, one can reach to the full text of that particular article on the journal’s website. Start a QR-code reading software (see list of free applications from <http://tinyurl.com/yzlh2tc>) and point the camera to the QR-code printed in the journal. It will automatically take you to the HTML full text of that article. One can also use a desktop or laptop with web camera for similar functionality. See <http://tinyurl.com/2bw7fn3> or <http://tinyurl.com/3ysr3me> for the free applications.