

Persistence of Hyaluronic acid Filler for Subcutaneous Atrophy in a Case of Circumscribed Scleroderma

Dear Editor,

Focal scleroderma also called as “circumscribed morphea” seen predominantly in young adults is characterised by atrophy and loss of subcutaneous tissue leading to deformity and volume loss in the affected area. Its aetiology is not completely understood and it is estimated that 50% of cases go into remission within 2.7 years of the onset of the disease.^[1] After a stage of initial inflammation, there is a localised progressive fibrosis, atrophy with hypopigmentation or hyperpigmentation.

Volume loss, bone defects and hemifacial atrophy with paramedian or central deformities of face are associated with cosmetic concern for the patient.^[2] Various methods to augment or reconstruct the volume loss and deformity include direct resection and suturing, soft tissue fillers, autologous fat grafting, reconstructive flaps^[3] and or polyethylene implants.^[2,4]

Soft-tissue augmentation with the injectable fillers is a minimally invasive technique recently reported for circumscribed morphea.^[5-7]

A 24-year-old woman presented at our centre with a cosmetic concern for the deformity on the chin [Figure 1]. On examination she was found to have focal scleroderma or circumscribed morphea involving the chin and neck. The neck showed focal circumscribed pigmentation and sclerosis without any signs of inflammation, while the subcutaneous atrophy resulted in volume defect on left side of chin with loss of chin contour and a visible indentation at the mandibular bone as seen in Figure 1 and confirmed by X-ray. The lesions were stable and non progressive for more than 5 years without inflammation and the pigmentation at neck and clinically suggested a burnt-out morphea. The skin biopsy from neck confirmed inactive stage of morphea. The patient declined a CT scan for the same, and had, negative ANA and Anti-Ds DNA antibodies and anti-histone antibodies. Since patient presented for cosmetic concern and considering her potential age of marriage, the patient was counselled for temporary volume restoration of the chin with use of large particle size hyaluronic acid filler. Contraindications to fillers were ruled out. After an informed valid consent of the patient and under surface anesthesia patient was injected with Perlane^R- Q Med, 20 mg/ml which has particle size of 1000 microns. A bolus technique with a 30-G needle was used till volume correction was achieved. A total of 1ml was injected in a single session. Post-filler injection the area was cooled with ice compresses and molding

of filler was done for even placement and to prevent lumpiness. The post-treatment phase was managed with antibiotics for 5 days and topical antibacterial creams. The patient was followed up at 2-week intervals. There was satisfactory correction in the volume loss of the chin [Figures 2 and 3]. No additional filler injection was needed. For sclerotic changes over the neck patient was put on topical tacrolimus and emollients and sun protection. The patient had an uneventful phase free of any adverse effects and followed up regularly. At a follow-up after 9 months of injection the volume defect restoration showed persistence of correction as seen in Figures 4 and 5. The patient was satisfied with the result and declined any further skin biopsy.

The non-animal stabilised hyaluronic acid fillers (Perlane^R- Q Med) were considered due to their safety, no requirement for pre-testing, large particle size, lifting and volume restoring capacity, longevity due to minimal cross-linking and ability to reverse injection with hyaluronidase when required if result is undesirable. Perlane^R has a large particle size of 1000 microns and is approved for deep dermal and subcutaneous injections. The patient showed satisfactory correction of volume deformity with HA filler which was safe and effective and showed persistence for 9 months of follow-up with no signs of filler degradation. Reports claim expansion of the use of hyaluronic acid fillers to include scar atrophy, as persistence of a desired cosmetic appearance of volume restoration and appearance of the scar with sustained satisfaction 24 months after hyaluronic acid treatment, without the need for repeat injection.^[8] Thraeja and Richards *et al.* report successful correction of en coup de sabre and linear morphea with HA fillers,^[5,8]

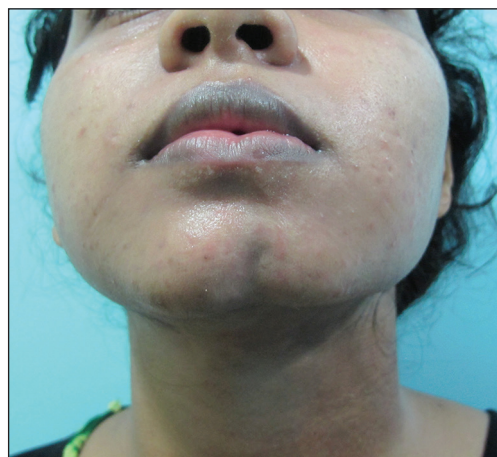

Figure 1: Circumscribed morphea with chin contour defect

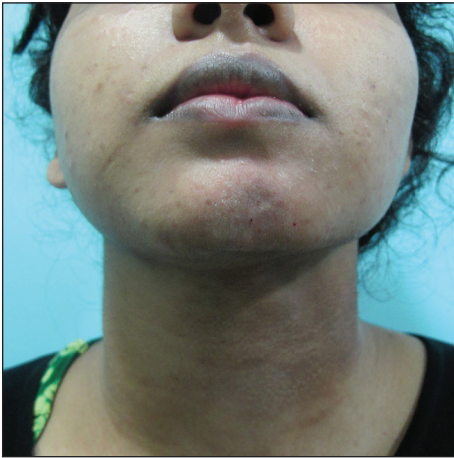


Figure 2: Circumscribed morphea immediately after HA filler injection

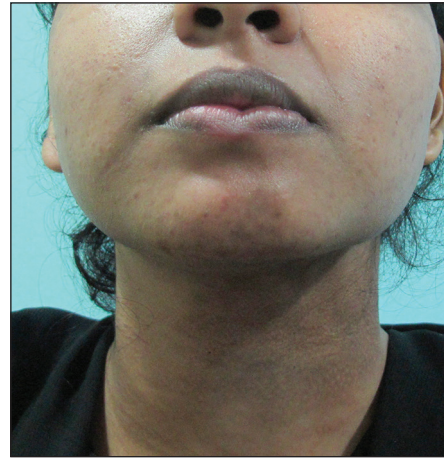

Figure 3: Circumscribed morphea- 1 week after HA filler

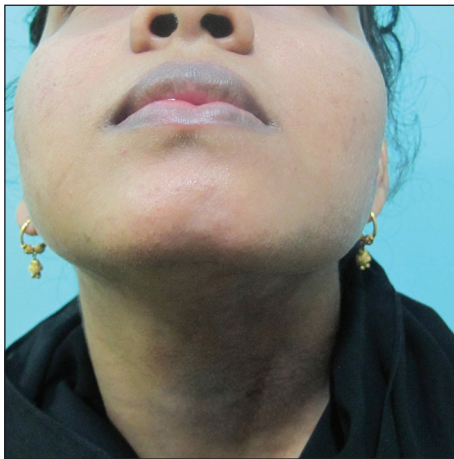

Figure 4: Persistence of filler injected for subcutaneous atrophy in morphea at 9 months post-treatment

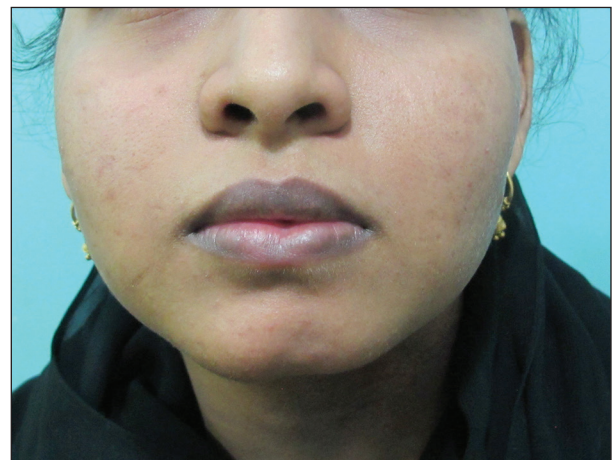

Figure 5: Persistence of filler at 9 months post-treatment done for morphea-induced chin contour defect

whereas Onesti reported the results were found to be upto 12 months in four patients with linear scleroderma treated with poly-L-lactic acid (PLLA).^[7]

Autologous dermal fat grafts resulted in the treated areas at level with the adjacent skin within 3 months. Follow-up for a period of 12 months showed a perfectly level and stable graft with no further resorption.^[9] Potential complications of fillers include bruising, lumpiness, infections and vascular occlusion, and were not seen in this patient. Faster degradation of filler in morphea was one of our greatest concerns which were not seen in our patient due to inactive nature of the disease. The volume correction was maintained by the patient till follow-up at 9 months. Longer follow-up is needed to evaluate persistence in this patient beyond 9 months and more studies with permanent fillers are needed. The HA fillers are a good minimally invasive temporary therapeutic option for volume defect correction in focal circumscribed morphea involving the face.

Shehnaz Z Arsiwala

Department of Dermatology Dermatocosmetic and Laser Centre,
Prince Aly Khan Hospital, Mumbai, Maharashtra, India
E-mail: drshenaz@gmail.com

REFERENCES

1. Zwischenberger BA, Jacobe HT. A systematic review of morphea treatments and therapeutic algorithm. *J Am Acad Dermatol* 2011;65:925-41.
2. Bielsa Marsol I. Update on the classification and treatment of localized scleroderma. *Actas Dermosifiliogr* 2013;104:654-66.
3. Karaaltin MV, Akpınar AC, Baghaki S, Akpınar F. Treatment of "en coup de sabre" deformity with adipose-derived regenerative cell-enriched fat graft. *J Craniofac Surg* 2012;23:e103-5.
4. Ozturk S, Acarturk TO, Yapici K, Sengezer M. Treatment of 'en coup de sabre' deformity with porous polyethylene implant. *J Craniofac Surg* 2006;17:696-701.
5. Thareja SK, Sadhwani D, Alan Fenske N. Encoupedesabre morphea treated with hyaluronic acid filler. Report of a case and review of the literature. *Int J Dermatol* 2013.
6. Choksi AN, Orringer JS. Linear morphea-induced atrophy treated with hyaluronic acid filler injections. *Dermatol Surg* 2011;37:880-3.

7. Onesti MG, Troccola A, Scuderi N. Volumetric correction using poly-L-lactic acid in facial asymmetry: Parry Romberg syndrome and scleroderma. *Dermatol Surg* 2009;35:1368-75.
8. Richards KN, Rashid RM. Twenty-four-month persistence of hyaluronic acid filler for an atrophic scar. *J Cosmet Dermatol* 2011;10:311-2.
9. Lapiere JC, Aasi S, Cook B, Montalvo A. Successful correction of depressed scars of the forehead secondary to trauma and morphea en coup de sabre by en bloc autologous dermal fat graft. *Dermatol Surg* 2000;26:793-7.

Access this article online	
Quick Response Code: 	Website: www.jcasonline.com
	DOI: 10.4103/0974-2077.155099