

## Squamous Cell Carcinoma Complicating Vitiligo in an Indian Man

An elderly man, a known case of generalized vitiligo of long duration, presented to us with an ulcerated exophytic growth arising from the vitiliginous skin. The histopathological study confirmed the clinical suspicion of squamous cell carcinoma. Cutaneous neoplasia arising from the vitiliginous skin is a rare situation. Lack of melanin leaves the skin vulnerable to ultraviolet radiation damage, which may predispose to cutaneous neoplasia. Therefore, the importance of photoprotection has been stressed upon through this illustration.

**KEYWORDS:** India, squamous cell carcinoma, vitiligo

### INTRODUCTION

Vitiligo is a chronic disorder with an estimated worldwide prevalence of 0.5–4%.<sup>[1]</sup> It has a complex etiopathogenesis, with the destruction of the melanocytes being the ultimate outcome. Melanin, an endogenous chromatophore, is thought to be protective against the development of pre-malignant and malignant cutaneous lesions, which may result from a prolonged ultraviolet (UV) radiation exposure. Occasional cases of nonmelanoma skin cancer (NMSC) arising in vitiligo with or without phototherapy have been documented<sup>[2-7]</sup> in the world literature; however, none have been reported from the Indian subcontinent so far.

### CASE REPORT

A 65-year-old man accessed our clinic with a non-healing ulcer over the right hand for the last 1 year. The lesion initiated as a pea-sized papule, which subsequently increased in size and ulcerated in the centre. The patient was a diagnosed case of generalized vitiligo for the past 30 years, for which, he had been treated with topical corticosteroids without any response. The patient did not receive any form of phototherapy or immunosuppressive

therapy. He was a daily wager, working outdoors for prolonged hours. He had never used photoprotective measures. The patient denied exposure to arsenic, X-ray irradiation and occupational carcinogens. He vehemently denied any intake of Ayurvedic medications for vitiligo. There was neither a history of vitiligo nor any malignancy in other family members.

Cutaneous examination revealed an exophytic growth, 4 cm across, present over the dorsal aspect of the right hand, adhered to the underlying subcutaneous tissue [Figure 1]. The surface of the growth was marked by ulceration in the centre. The rest of the cutaneous and systemic examination was normal. The histopathological examination of the sections from the margin of the ulcer revealed the presence of a tumour infiltrating the dermis and the subcutaneous tissue in the form of solid nests and sheets. The tumour cells were polygonal with eosinophilic cytoplasm. The nuclei were vesicular with prominent eosinophilic nucleoli. There was abundant keratinization in the centre of solid nests [Figure 2]. A diagnosis of well-differentiated keratinized squamous cell carcinoma (SCC) was made. The ulcerated nodule was excised with a 1-cm margin and the lesion was allowed to heal by secondary intention. The patient was advised to avoid sun exposure, follow adequate photoprotective measures and report for any suspicious lesion. No recurrence was noticed after a follow-up of 1 year.

### DISCUSSION

The prevalence of vitiligo in India has been speculated to vary from 0.1% to >8.8%.<sup>[8]</sup> SCC is the most common cutaneous malignancy in blacks and Asian Indians,

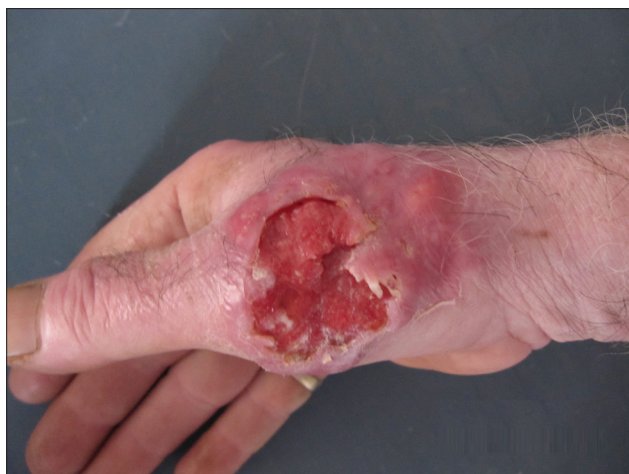Access this article online	
Quick Response Code: 	Website: www.jcasonline.com
	DOI: 10.4103/0974-2077.94340

**Amit Kumar Dhawan, Prashant Verma, Archana Singal, Sonal Sharma<sup>1</sup>**

Departments of Dermatology and STD, <sup>1</sup>Pathology, University College of Medical Sciences (University of Delhi) and Associated Guru Teg Bahadur Hospital, Dilshad Garden, Shahdara, New Delhi, India

Address for correspondence:

Dr. Prashant Verma, 9 State Bank Colony, G. T Karnal Road, Delhi - 110 009, India. E-mail: drprashant\_derma@yahoo.co.in

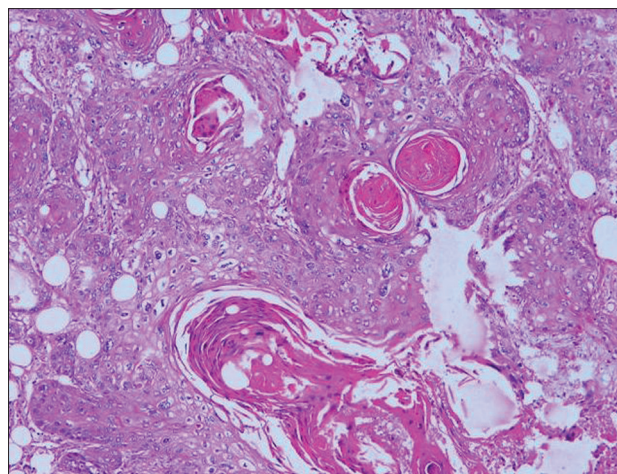


**Figure 1:** An exophytic growth, 4 cm across, present over the dorsal aspect of the right hand, adhered to the underlying subcutaneous tissue. The surface of the growth was marked by ulceration in the centre

accounting for 30–65% skin cancers in both races.<sup>[9]</sup> There are a number of factors, acquired and genetic, predisposing to SCC. UV radiation is considered to be the predominant risk factor for the development of SCC. A linear correlation has been shown between SCC and UV radiation exposure.<sup>[10]</sup> Accordingly, the incidence of SCC has been reported to double with each 8–10° decline in the geographical latitude and equator.<sup>[10]</sup> At the molecular level, UV radiation induces C-T single base and CC-TT tandem mutations and loss of the heterozygosity of p53. Two patients, one each of squamous and basal cell carcinoma with vitiligo, were reported. The tumours developed only 2 and 6 years after the development of vitiligo, and so, it has been mooted as to whether vitiligo was the contributing factor.<sup>[11]</sup> Similarly, another patient developed SCC at the age of 75 years, 2 years after the onset of vitiligo.<sup>[12]</sup> A higher incidence of NMSC, though not significant, was observed in a cohort of 477 Caucasian vitiligo patients<sup>[2]</sup> as compared to the age-adjusted control population. Besides, actinic keratosis<sup>[3]</sup> and keratoacanthoma centrifugum marginatum<sup>[13]</sup> have been documented in vitiligo patients. Photoprotective measures including sunscreens are seldom a part of vitiligo prescription, especially in developing nations. Partly, the inadequate use of sunscreens can be attributed to the economic status of the patients in developing countries like India. Therefore, the use of alternative physical measures of photoprotection needs to be stressed upon. Furthermore, phototherapy, being frequently used now-a-days to treat vitiligo, may serve as an independent risk factor for the occurrence of NMSC.<sup>[3,5,7]</sup>

## CONCLUSION

It is imperative to educate the patients to practice sufficient photoprotection, and to follow them up regularly to screen for any suspicious lesion.



**Figure 2:** Presence of the tumour infiltrating the dermis and the subcutaneous tissue in the form of solid nests and sheets. The tumour cells were polygonal with eosinophilic cytoplasm and vesicular nuclei with prominent eosinophilic nucleoli. There was abundant keratinization in the centre of solid nests (H and E, ×40)

## REFERENCES

1. Forschner T, Buchholtz S, Stockfleth E. Current state of vitiligo therapy-evidence-based analysis of the literature. *J Dtsch Dermatol Ges* 2007;5:467-75.
2. Hexsel CL, Eide MJ, Johnson CC, Krajenta R, Jacobsen G, Hamzavi I, et al. Incidence of nonmelanoma skin cancer in a cohort of patients with vitiligo. *J Am Acad Dermatol* 2009;60:929-33.
3. Buckley DA, Rogers S. Multiple keratosis and squamous carcinoma after PUVA treatment of vitiligo. *Clin Exp Dermatol* 1996;21:43-5.
4. Saarinen K, Lestringant GG, Masouye I, Frossard PM. Actinic damage and squamous cell carcinoma in sun-exposed skin affected by vitiligo. *Br J Dermatol* 2000;143:219-21.
5. Takeda H, Mitsuhashi Y, Kondo S. Multiple squamous cell carcinomas *in situ* in vitiligo lesions after long-term PUVA therapy. *J Am Acad Dermatol* 1998;38:268-70.
6. Seo SL, Kim IH. Squamous cell carcinoma in a patient with generalized vitiligo. *J Am Acad Dermatol* 2001;45(6 Suppl): S227-9.
7. Park HS, Lee YS, Chun DK. Squamous cell carcinoma in vitiligo lesion after long-term PUVA therapy. *J Eur Acad Dermatol Venereol* 2003;17:578-80.
8. Sehgal VN, Srivastava G. Vitiligo: Compendium of clinico-epidemiological features. *Indian J Dermatol Venereol Leprol* 2007;73:149-56.
9. Gloster HM, Neal K. Skin Cancer in Skin of Color. *J Am Acad Dermatol* 2006;55:741-60.
10. Johnson TM, Rowe DE, Nelson BR, Swanson NA. Squamous cell carcinoma of the skin (excluding lip and oral mucosa). *J Am Acad Dermatol* 1992;26 (3 Pt 2):467-84.
11. Lassus A, Apajalahti A, Blomqvist K, Mustakallio M, Kiistala U. Vitiligo and neoplasms. *Acta Derm Venereol* 1972;52:229-32.
12. Ortonne JP, Pelletier N, Chabanon M, Thivolet J. Vitiligo and cutaneous epitheliomas. *Ann Dermatol Venereol* 1978;105:1063-4.
13. Attili S, Attili VR. Keratoacanthoma centrifugum marginatum arising in vitiligo: A case report. *Dermatol Online J* 2006 28;12:18

**How to cite this article:** Verma P, Singal A, Sharma S, Dhawan AK. Squamous cell carcinoma complicating vitiligo in an Indian man. *J Cutan Aesthet Surg* 2012;5:36-7.

**Source of Support:** Nil. **Conflict of Interest:** None declared.