

# Comparative Study to Evaluate the Efficacy of Radiofrequency Ablation versus Trichloroacetic Acid in the Treatment of Xanthelasma Palpebrarum

Praveen Kumar Shanmugam Reddy, Sumathy Tharayil Kunneth, Shyam Prasad Arakali Lakshminarayana, Suparna Madivalara Yallappa, Ranganathan Chandrashekara, Shivaswamy Kanakapura Nanjundaswamy

Department of Dermatology, M. S. Ramaiah Medical College, Bengaluru, Karnataka, India

**Address for correspondence:** Dr. Praveen Kumar Shanmugam Reddy, 189, T2, 3<sup>rd</sup> Main, 1<sup>st</sup> Block, Koramangala, Bengaluru - 560 034, Karnataka, India.  
E-mail: drpraveen.1982@gmail.com

## ABSTRACT

**Background:** Xanthelasma palpebrarum (XP) is a metabolic disorder involving the eyelids. Radiofrequency (RF) surgery and trichloroacetic acid (TCA) applications have been listed among the procedures for XP, but comparative studies are not available. **Aim:** To compare the efficacy of radiofrequency surgery versus trichloroacetic acid application in the treatment of XP. **Settings and Design:** 20 consecutive cases of XP attending dermatology, medicine and endocrinology out-patient departments of M.S.Ramaiah teaching hospital were enrolled for the study. It was an open-label clinical trial conducted in our hospital for a duration of 1 year. **Materials and Methods:** 20 consecutive patients conforming to inclusion criteria were selected for the study. For each patient, lesions were treated with radiofrequency ablation on one side and TCA application on the other side. **Results:** RF ablation was done for 12 patients over right eye lesions and 8 patients over the left eye lesions. TCA applications were done for 8 patients over right eye lesions and 12 patients over left eye lesions. 70% of lesions treated with RF ablation had a score of improvement of 4 and 70% of lesions treated with TCA application had a score of improvement of 4, at 4 weeks of follow-up. At four weeks of follow-up 40% in RF group and 15% in TCA group had scarring and 45% in RF group and 30% in TCA group had pigmentation. **Conclusion:** RF ablation as compared to TCA application, required fewer sessions for achieving more than 75% clearance of lesions. However, TCA applications were associated with fewer complications comparatively.

**KEYWORDS:** Radiofrequency ablation, trichloroacetic acid, xanthelasma palpebrarum

## INTRODUCTION

Xanthelasma palpebrarum (XP)/xanthelasmata are the xanthomata that develop around the eyes. They most commonly affect the upper eyelids and the area around the medial canthus.<sup>[1]</sup> It is the most common type of xanthoma.<sup>[2]</sup> The clinical morphologies of xanthelasma can be categorised into macular, flat plaques and papulonodular types. Although essentially benign, treatment is of cosmetic importance. About 60% of patients have associated hypercholesterolaemia. Radiofrequency (RF) ablation and trichloroacetic acid (TCA) application<sup>[2]</sup> have been listed among the

procedures for XP, but comparative studies are not available. The present study was undertaken to compare the efficacy of RF surgery versus TCA application in the treatment of XP.

## SUBJECTS AND METHODS

Twenty consecutive cases of XP attending Dermatology, Medicine and Endocrinology Outpatient Departments (OPDs) of M. S. Ramaiah Medical College and

This is an open access article distributed under the terms of the Creative Commons Attribution-NonCommercial-ShareAlike 3.0 License, which allows others to remix, tweak, and build upon the work non-commercially, as long as the author is credited and the new creations are licensed under the identical terms.

**For reprints contact:** reprints@medknow.com

**How to cite this article:** Reddy PS, Kunneth ST, Lakshminarayana SA, Yallappa SM, Chandrashekara R, Nanjundaswamy SK. Comparative study to evaluate the efficacy of radiofrequency ablation versus trichloroacetic acid in the treatment of xanthelasma palpebrarum. *J Cutan Aesthet Surg* 2016;9:236-40.

### Access this article online

#### Quick Response Code:



**Website:**  
www.jcasonline.com

**DOI:**  
10.4103/0974-2077.197073

Teaching Hospital (MSRMTH) were enrolled in the study. It was an open-label clinical trial conducted in our hospital for duration of 1 year. Written informed consent was obtained from all the patients enrolled in the study.

The inclusion criteria included male and female patients with XP in the age group, 20–60 years with lesions on both eyelids.

Patients with known allergy to lignocaine, on anticoagulants/pacemakers/with known cardiac illness were excluded from the study. Also patients with atopy and periorbital dermatitis, diabetic patients with poor glycaemic control and patients with immunosuppression were excluded.

All patients attending the OPD's of Dermatology, General Medicine and Endocrinology at MSRMTH, were screened for XP, and clinical diagnosis was made by an examining dermatologist. Twenty consecutive patients conforming to inclusion criteria were selected for the study.

For each patient, lesions were treated with RF ablation on the one side and TCA (30%–70%) application on the other side. Patients were allotted randomly, and for a given patient, all the lesions on the one side were treated with radiofrequency and the other side were treated with TCA. Although the number of lesions was unequal on both sides, to maintain uniformity for comparison, all the lesions on one side were treated with either RF ablation or TCA application. The RF equipment used was from Ellman International, Inc., Oceanside, NY, USA., model Dento - Surg 90 F.F.P, Volts AC 220/240, 1.6 amps, frequency 3.8 MHz. The lesions were ablated till they turned brown, and the scab was removed with a saline gauze. The lesions were ablated till the pink tissue was seen. Procedures were repeated at weekly intervals if required based on the individual cases. The maximum duration of treatment was for 4 weeks. TCA was applied on the lesions following multiple puncture made on the lesions with a 26 G needle, 2 mm apart. The end-point of TCA application was frosting of lesions. Following the frosting, the lesions were thoroughly rinsed with normal saline. The lesions treated with RF/TCA were covered with 2% fusidic acid, and the applications were continued for 5 days following procedure. The clinical improvement was assessed on weekly basis with serial photographs. The results were scored on a 0–4 point scale:<sup>[4]</sup>

- 0 - No improvement
- 1 - Moderate result (<25% clearing)
- 2 - Satisfactory result (25%–50% clearing)
- 3 - Good result (50%–75% clearing)
- 4 - Excellent result (>75% clearing).

Patients were assessed for the presence of any scars, pigmentation, recurrence and Koebner's phenomenon. Final evaluation was done at the end of 4 weeks. Parameters studied included age, sex, duration of the disease, number of lesions, clinical morphology of lesions, associated medical conditions, other associated xanthomas, and lipid profile was ordered for each patient.

Appropriate response to the treatment was documented with serial photographs. Photographs were assessed by two investigators regarding the clinical improvement and associated complications. Final follow-up at 6 months after the last session was done.

### Ethics

Ethical clearance was obtained from the ethical review board of our institution.

### Method of statistical analysis

The following methods of statistical analysis have been used in this study. The results averaged (mean  $\pm$  standard deviation) for continuous data, and number and percentage for dichotomous data are presented in tables and figures. Proportions were compared using Chi-square test of significance.

In the above test,  $P < 0.05$  was accepted as indicating statistical significance. Data analysis was carried out using Statistical Package for Social Science package (SPSS Inc. Released 2009. PASW statistics for windows version 18.0).

### RESULTS

Twenty patients were enrolled for the study, of them 18 were female and 2 were male. The most common morphology seen was of flat plaque type. RF ablation was done for 12 patients over right eye lesions and 8 patients over the left eye lesions. TCA applications were done for 8 patients over right eye lesions and 12 patients over left eye lesions. At 1<sup>st</sup> week of follow-up [Table 1], 40% in TCA group had <50% improvement and 65% in RF group had 50%–75% improvement in lesions (score of >3). At 2<sup>nd</sup> week of follow-up [Table 1], 85% in TCA group had 50%–75% improvement and 25% in RF group had more than 75% improvement in lesions (score of 4). At 3<sup>rd</sup> week of follow-up [Table 1], 65% in TCA group had 50%–75% improvement and only 35% in TCA group had more than 75% improvement in lesions (score of 4). At 4<sup>th</sup> week of follow-up [Table 1], 70% in TCA group had 50%–75% improvement (score of 3) and 70% in RF group had more than 75% improvement in lesions (score of 4). At 4 weeks of follow-up [Table 2], 40% in RF group and 15% in TCA group had scarring and 45% in RF group and 30% in TCA group had pigmentation [Table 3].

**DISCUSSION**

XP is the most common type of xanthoma. It most commonly affects the upper eyelids and the area around the medial canthus. XP is most commonly seen in middle-aged and older adults with a peak incidence between 30 and 50 years. Women are more commonly affected than men. They are seen in people with normal circulating lipid levels, as well as familial hypercholesterolaemia, type III hyperlipoproteinaemia and chronic cholestasis.<sup>[1,2]</sup> All patients included in our study were normolipaemic.

XP can have various morphological patterns such as macular, papular, plaque type and nodular varieties. They are classified as Grade I if lesions are seen only on the upper eyelid, Grade II if lesions extend to the medial canthus area, Grade III if the lesions are seen on upper and lower eyelids and grade IV if there are diffuse lesions an medial as well as lateral aspects of upper and lower eyelids. Figures 1-3 illustrate three representative cases.

Although the classical treatment option remains surgical excision, alternatively, chemical cauterisation, cryosurgery and electrofulguration have all been tried in the past with mixed results.<sup>[3]</sup> Surgical excision of

XP is difficult, especially in cases where the lesions are multiple, close to the eyes and have indistinct borders. There is a risk of ectropion associated with surgical excision of lesions in the lower eyelid. For larger lesions, reconstruction with full thickness grafts or flaps may be necessary. There is also a transient risk of haematomas and infections associated with surgery.

The other modalities of treatment for XP include CO<sub>2</sub> laser,<sup>[4,5]</sup> Erb: Yag laser, Q-switched Nd: Yag laser,<sup>[6-8]</sup> pulse dye laser, potassium-titanyl-potassium laser, argon laser<sup>[9]</sup> and diode<sup>[10]</sup> lasers. These lasers have a disadvantage of being expensive.

TCA in varying strengths<sup>[8,11,12]</sup> is used in treatment of various morphological patterns of XP. TCA is a very cost-effective modality of treatment in XP, and there are few case reports and pilot studies which have demonstrated the efficacy of TCA in treatment of XP. RF cautery unit is also a very cost-effective modality of treatment in XP and is easily available with all practitioners. The TCA applications as well as RF cautery can be performed at multiple sessions until clearance of lesions.

In our study, the most common morphology was plaque type and 30% TCA was used for the same. There was a comparable difference in outcome observed in the percentages of improvement in each group, and the data analysis points out that RF showed a better improvement in score of lesions at 2<sup>nd</sup> week and TCA required multiple sessions to achieve a score of 4. The scarring and pigmentation were more in the RF group at 4 weeks of follow-up. There was no recurrence of

**Table 1: Various treatment groups with their outcome at weekly intervals correlated with percentage of improvement in lesions**

Outcome at weeks	Groups	<50% improvement	50%-75% improvement	>75% improvement	P
1 <sup>st</sup>	RF	7 (35)	13 (65)		0.743
	TCA	8 (40)	12 (60)		
2 <sup>nd</sup>	RF		15 (75)	5 (25)	0.69
	TCA		17 (85)	3 (15)	
3 <sup>rd</sup>	RF		9 (45)	11 (55)	0.203
	TCA		13 (65)	7 (35)	
4 <sup>th</sup>	RF		6 (30)	14 (70)	0.327
	TCA		9 (45)	11 (55)	

TCA: Trichloroacetic acid, RF: Radiofrequency

**Table 2: Scarring as a complication observed at 4 weeks of follow-up**

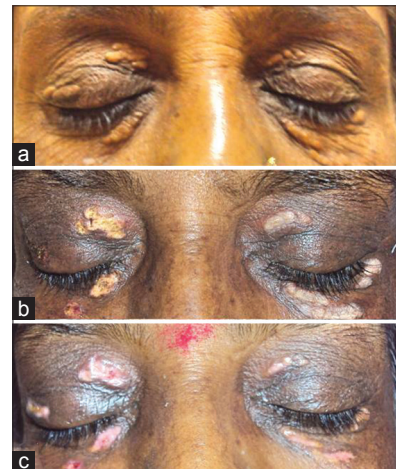Group	Scarring (%)	
	Present	Absent
RF	8 (40)	12 (60)
TCA	3 (15)	17 (85)

P=0.077. TCA: Trichloroacetic acid, RF: Radio frequency

**Table 3: Pigmentation as a complication observed at 4 weeks of follow-up**

Group	Pigmentation (%)	
	Present	Absent
RF	9 (45)	11 (55)
TCA	6 (30)	14 (70)

P=0.327. TCA: Trichloroacetic acid, RF: Radio frequency



**Figure 1: (a) Plaque type of xanthelasma palpebrarum distributed bilaterally over upper and lower eyelids. (b) Right eye lesions were treated with radiofrequency ablation and left eye lesions were treated with trichloroacetic acid (70%) applications. (c) Follow-up of lesions at 3<sup>rd</sup> week, lesions of the right eye show an improvement of three with scarring and the lesions of the left eye have healed with hypopigmentation**

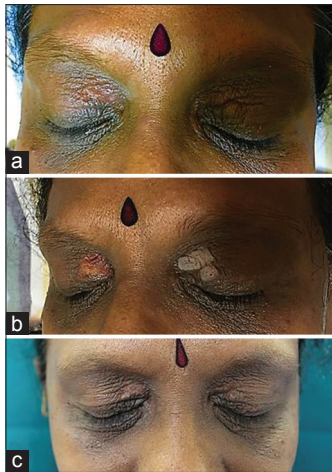


Figure 2: (a) Plaque type of xanthelasma palpebrarum distributed over upper eyelids on left and right side. (b) The right eye lesions were treated with radiofrequency ablations and left eye lesions with trichloroacetic acid (60%) applications. (c) At 4 weeks of follow-up, right eye lesions show a score of 4 and left eye lesions show a score of 4. The right side shows more hypopigmentation as compared to left eye

lesions at 6 months of follow-up. The outcomes of other studies<sup>[11,13,14]</sup> as compared to the present study are summarised in Table 4.

This study highlights the use of TCA, which is a very cost-effective modality of treatment for XP, but multiple sessions are required to achieve a score of 4. RF ablation requires fewer sessions for treating XP, and there were few side effects reported such as scarring and pigmentation (however not statistically significant as compared to TCA in our study).

TCA can be effectively used to treat even a plaque type of XP in a primary care setting by a dermatologist who has undergone a basic training in the procedure. This study also highlights the use of multiple puncture technique used in application of TCA. The various lasers as an option mentioned are very expensive and not affordable by common patients and some of them have varied results in treatment of XP.

RF surgery can be done by a dermatologist who has just started practice with a minimum setup and the number of sessions required is fewer and is a very cost-effective modality of treatment. In this era of lasers, the contemporary methods to treat the entity achieving similar results to lasers are highlighted.

The small sample size is a limitation of this study; however, a good number of lesions were treated and the effects were similar in all the lesions. This study was conducted as there

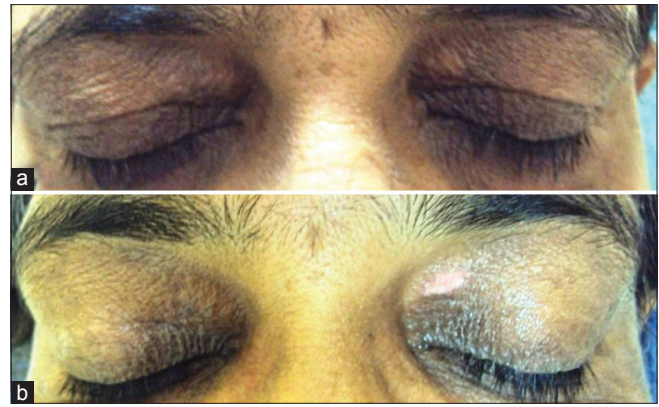

Figure 3: (a) Macular type of xanthelasma palpebrarum distributed over upper eyelids bilaterally. The right eye lesions were treated with 30% trichloroacetic acid application and left eye lesions were treated with radiofrequency ablation. (b) Score of 4 on right eye at 4 weeks and left eye lesion has healed with hypopigmentation

Table 4: Comparison of outcomes of various studies with trichloroacetic acid

Studies	Number of patients/lesions	Percentage of TCA used	Results	Follow-up
Cannon et al. <sup>[13]</sup> (2010)	102	95	Success rate: 61% at 31.8 months follow-up	Maximum: 31.8 months
Nahas et al. <sup>[14]</sup> (2009)	24	70	45.8% had excellent improvement	6 months
Haque et al. <sup>[11]</sup> (2006)	51	Various strengths	Macular lesions: 1 application Flat plaque lesions: 1-3 sessions with 50%-70% TCA	
Present study	20/63 lesions treated	Various strengths	50%-80% TCA applied based on the morphology of lesions	6 months

TCA: Trichloroacetic acid

are no reported data comparing the efficacy of RF versus TCA as a modality of treatment for XP.

### CONCLUSION

RF ablation required fewer sessions to achieve an improvement of more than 75% clearance of lesions compared to TCA applications, but statistically it was not significant. Scarring as a complication was comparatively lesser in TCA applications, with a 25% difference in association, as compared to RF, but even this association was not statistically significant. Our study also highlights the use of multiple puncture technique in application of TCA for XP, which is not reported before. However, with

larger sample data, these findings may be confirmed. TCA application is a very cost-effective modality and can be used in routine clinical practice, even in a primary care health centre for the treatment of XP.

### Financial support and sponsorship

Nil.

### Conflicts of interest

There are no conflicts of interest.

### REFERENCES

1. Sarkany RP, Breathnach SM, Seymour CA, Weismann K, Burns DA, Burns T, *et al.* Rook's Textbook of Dermatology. 8<sup>th</sup> ed. Vol. 3. Oxford: Wiley-Blackwell; 2010. Metabolic and Nutritional Disorders; p. 57: 60-75.
2. Jain A, Goyal P, Nigam PK, Gurbaksh H, Sharma RC. Xanthelasma palpebrarum-clinical and biochemical profile in a tertiary care hospital of Delhi. *Indian J Clin Biochem* 2007;22:151-3.
3. Bergman R. The pathogenesis and clinical significance of xanthelasma palpebrarum. *J Am Acad Dermatol* 1994;30(2 Pt 1):236-42.
4. Pathania V, Chatterjee M. Ultrapulse carbon dioxide laser ablation of xanthelasma palpebrarum: A case series. *J Cutan Aesthet Surg* 2015;8:46-9.
5. Lieb WE, Klink T, Münnich S. CO<sub>2</sub> and erbium YAG laser in eyelid surgery. A comparison. *Ophthalmologie* 2000;97:835-41.
6. Fusade T. Treatment of xanthelasma palpebrarum by 1064-nm Q-switched Nd: YAG laser: A study of 11 cases. *Br J Dermatol* 2008;158:84-7.
7. Kaliyadan F, Dharmaratnam AD. Q-Switched Nd: YAG in the Treatment of Xanthelasma Palpebrarum. *J Cutan Aesthet Surg* 2010;3(2):127-8.
8. Karsai S, Schmitt L, Raulin C. Is Q-switched neodymium-doped yttrium aluminium garnet laser an effective approach to treat xanthelasma palpebrarum? Results from a clinical study of 76 cases. *Dermatol Surg* 2009;35:1962-9.
9. Hintschich C. Argon laser coagulation of xanthelasmas. *Ophthalmologie* 1995;92:858-61.
10. Park EJ, Youn SH, Cho EB, Lee GS, Hann SK, Kim KH, *et al.* Xanthelasma palpebrarum treatment with a 1,450-nm-diode laser. *Dermatol Surg* 2011;37:791-6.
11. Haque MU, Ramesh V. Evaluation of three different strengths of trichloroacetic acid in xanthelasma palpebrarum. *J Dermatolog Treat* 2006;17:48-50.
12. Akhyani M, Daneshpazhooh M, Jafari AK, Naraghi ZS, Farahani F, Toosi S. Koebner phenomenon in xanthelasma after treatment with trichloroacetic acid. *Dermatol Online J.* 2006;12:12.
13. Cannon PS, Ajit R, Leatherbarrow B. Efficacy of trichloroacetic acid (95%) in the management of xanthelasma palpebrarum. *Clin Exp Dermatol* 2010;35:845-8.
14. Nahas TR, Marques JC, Nicoletti A, Cunha M, Nishiwaki-Dantas MC, Filho JV. Treatment of eyelid xanthelasma with 70% trichloroacetic acid. *Ophthal Plast Reconstr Surg* 2009;25:280-3.