

Old Wine in New Bottle: Lentigo Transplant for Beauty Spot Creation

Yogesh M. Bhingradia, Tejaswini S. Salunke¹

Shivani Skin Care and Cosmetic Clinic, Surat, Gujarat, ¹Deenanath Mangeshkar Hospital, Pune, Maharashtra, India

Abstract

Melanocytic nevi especially on the face, neck, and chest are considered a sign of beauty since historic times. Since historic times and in various cultures, these nevi are associated with beauty and attractiveness, thus called beauty spots. Artificial beauty marks have been fashionable since the medieval era. It requires repetitive use easily making it a cumbersome process. Tattooed beauty marks by medical professionals or tattoo artists are commonly done but require frequent touch-ups with a risk of complications. So we came up with a very innovative technique of tissue grafting of an existing lentiginous/melanocyte nevus to the desired site which gave a natural and permanent solution.

Keywords: Beauty spot creation, lentigo transplant, nevus transplant

Melanocytic nevi especially on the face, neck, and chest are considered a sign of beauty since historic times. It is also called a “mole” derived from the Latin term “mullus” which means a small dark spot.^[1] Since historic times and in various cultures, these nevi are associated with beauty and attractiveness, thus called beauty spots.

The appearance of moles is mostly genetically predisposed due to the proliferation of pigment cells—a malformation of the skin. Exposure to sunlight or medical substances can trigger the emergence of such spots too.

Artificial beauty marks have been fashionable since the medieval era. It can be done in several ways. An artificial beauty mark is a piece of cosmetic sticker that you can stick on your face and that looks similar to a beauty spot, but it is made from porcelain or plastic (bindi spot) instead of being an original part of your body. But it requires repetitive use as it is easily removable and can fall off easily, making it a cumbersome process after a few days. Semipermanent artificial beauty marks can be achieved by cosmetic surgery. Tattooed beauty marks by medical professionals or tattoo artists are commonly done. Though it is called permanent they usually fade off in a few months to years due to the breakdown of the pigment and metabolizing it out of the system thus requiring frequent touch-ups. Tattoo making is an art of precision requiring

skills and results vary from person to person. Complications caused by dyes like foreign body granulomas, and atypical mycobacterial infections cannot be ruled out. So we came up with a very innovative technique of tissue grafting of an existing lentiginous/ melanocyte nevus to the desired site which gave a natural and permanent solution.

PROCEDURE

The lentigo on the right cheek was selected to be transplanted [Figures 1 and 2]. Under local anesthesia, a skin biopsy punch was used for excision of the lentigo. The size chosen was exact to the size of the lentigo. In our case we chose a punch of size 1.5mm. The depth of the excision was up to 3mm. Similarly, the recipient site was chosen after a detailed discussion and consent of the patient. The patient chose the transplantation site above lips on the right site/[Figures 3 and 4]). The same size punch with the same depth was excised from the recipient site. Using surgical glue the punch with the lentigo was secured as the recipient site [Figures 3 and 4].

Address for correspondence: Dr. Tejaswini Sopanrao Salunke,
Deenanath Mangeshkar Hospital, Pune, Maharashtra, India.
E-mail: winialways@gmail.com

Access this article online

Quick Response Code:



Website:
www.jcasonline.com

DOI:
10.4103/JCAS.JCAS_104_22

This is an open access journal, and articles are distributed under the terms of the Creative Commons Attribution-NonCommercial-ShareAlike 4.0 License, which allows others to remix, tweak, and build upon the work non-commercially, as long as appropriate credit is given and the new creations are licensed under the identical terms.

For reprints contact: reprints@medknow.com

How to cite this article: Bhingradia YM, Salunke TS. Old wine in new bottle: Lentigo transplant for beauty spot creation. J Cutan Aesthet Surg 2023;16:359-61.

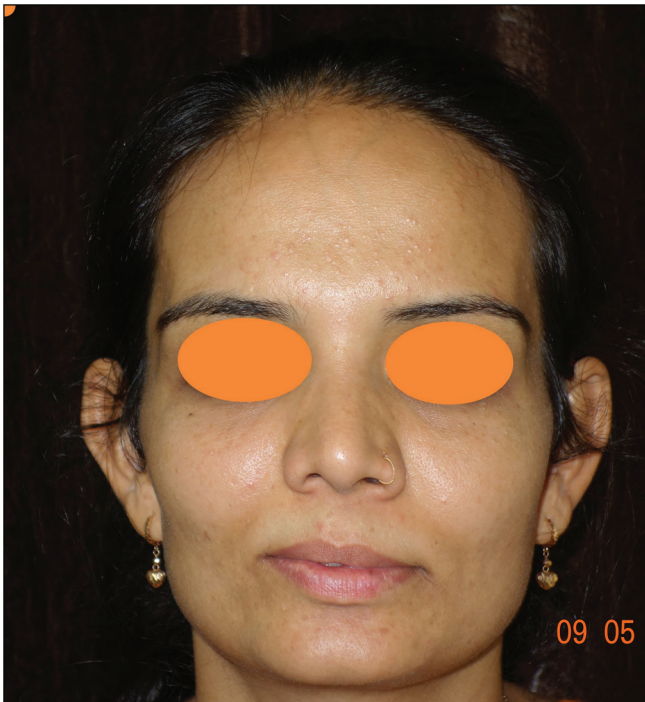

Figure 1: Front view of the face showing the lentigo over the right cheek

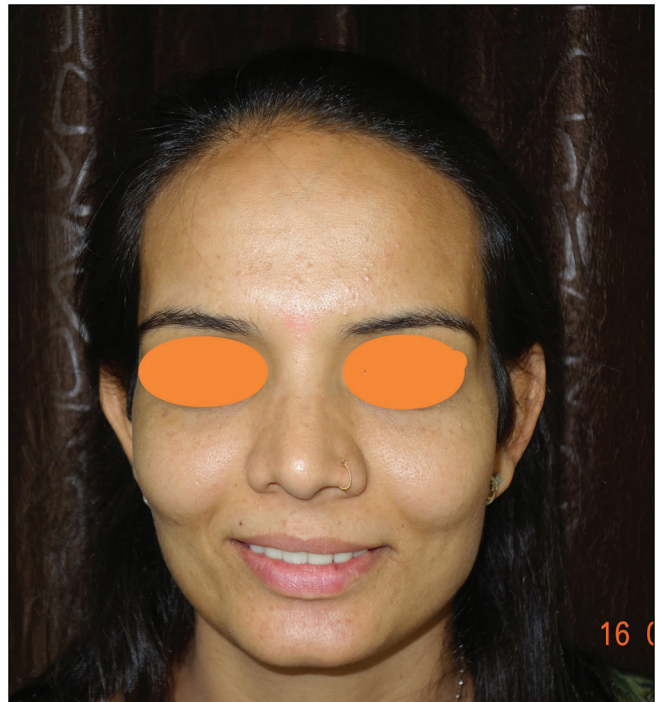


Figure 3: Front view of the face showing lentigo over the desired site (above upper lip on the right side)

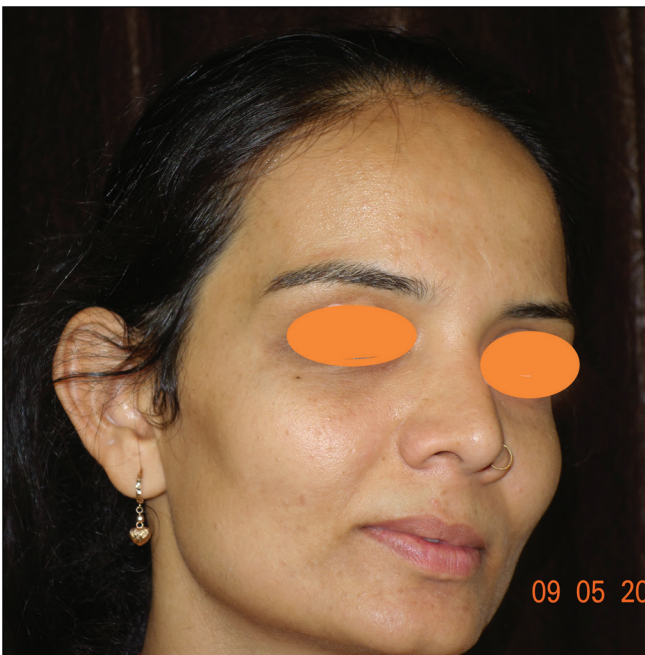

Figure 2: Side view of the face showing lentigo over right cheek

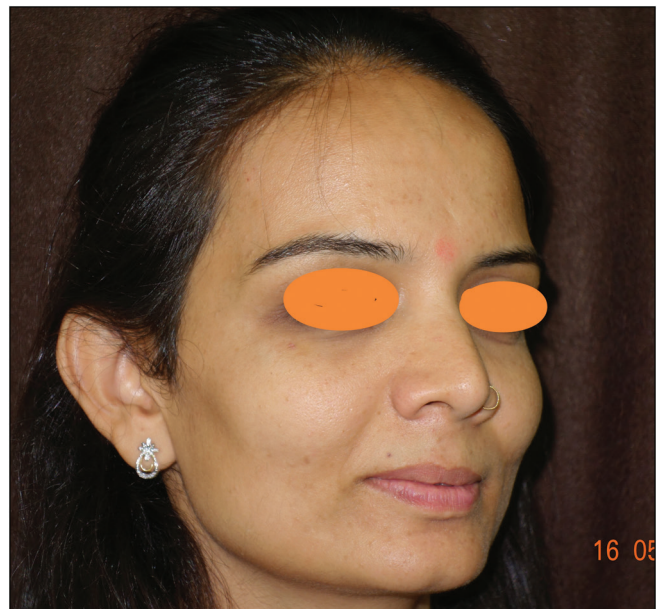

Figure 4: Side view of the face showing lentigo over the desired site (above upper lip on the right side)

The donor site was closed with a simple suture. The outcome of the procedure was instant, cosmetically rewarding with a completely natural look.

DISCUSSION

Tissue grafting procedures especially punch grafting is popularly used in vitiligo surgeries over the last one or two decades, especially in India.^[2] Follicular unit extraction

method used for hair transplant utilizes a similar mechanism where tissue grafts including the hair follicle are transplanted onto the recipient area.^[3,4]

When the graft is taken off, the piece of tissue is completely detached from the donor site and then placed on the vascular bed in the recipient holes. From this vascular bed, it derives its blood supply. Initially, the graft adheres to its new bed with the help of fibrin. There is the diffusion of nutrients through this fibrinous layer, which keeps the

graft alive initially. Within 2–3 days, capillary linkage occurs, with vascularization of the graft.

Just as in vitiligo and hair transplant surgeries the grafts are transplanted the same principle is used to transplant cosmetically appealing nevi or antigens to the desired site.

As dermatosurgeons, we need to understand that there is a growing overlap between medical treatment and traditional cosmetology. We should be able to understand patients' requirements and provide optimum care, modify some traditional techniques, and maximize outcomes.

Financial support and sponsorship

Not applicable.

Conflicts of interest

There are no conflicts of interest.

REFERENCES

1. Available from: <https://www.wordsense.eu/mulleus/>. [Last accessed on 2022 Jun 27].
2. Majid I. Grafting in vitiligo: How to get better results and how to avoid complications. *J Cutan Aesthet Surg* 2013;6:83-9.
3. Kerure AS, Deshmukh N, Agrawal S, Patwardhan NG. Follicular unit extraction [FUE]: One procedure, many uses. *Indian Dermatol Online J* 2021;12:381-8.
4. Rassman WR, Bernstein RM, McClellan R, Jones R, Worton E, Uyttendaele H. Follicular unit extraction: minimally invasive surgery for hair transplantation. *Dermatol Surg* 2002;28:720-8.