



Original Article

## Efficacy and safety of microneedling radiofrequency in patterned hair loss

Balakrishnan Nirmal<sup>1</sup>, S Shahin Mubeena<sup>1</sup>, Belavendra Antonisamy<sup>2</sup> 

<sup>1</sup>Department of Dermatology, Dermal Square skin hair nail clinic, Madurai, Tamil Nadu, India, <sup>2</sup>Department of Biostatistics, Christian Medical College, Vellore, Tamil Nadu, India.

**\*Corresponding author:**

Balakrishnan Nirmal, MD  
Consultant Dermatologist and  
Head, Dermal Square skin hair  
nail clinic, Madurai, India.

[nimu2swash@yahoo.co.in](mailto:nimu2swash@yahoo.co.in)

Received: 08 March 2023

Accepted: 13 August 2023

Published: 29 August 2024

**DOI**

10.25259/jcas\_44\_23

**Quick Response Code:**



### ABSTRACT

**Objectives:** We aimed to assess the improvement of patterned hair loss with microneedling radiofrequency (MNRF) and its adverse effects in patients.

**Material and Methods:** An open-label study was conducted to evaluate the efficacy and safety of MNRF for the treatment of androgenetic alopecia. Patients diagnosed with patterned hair loss received three MNRF treatment sessions once monthly. Efficacy was assessed by comparing before and after photographs and trichoscopy.

**Results:** Twenty-four patients were recruited. Excellent improvement in hair growth was observed in 14 patients, fair improvement in seven patients, and no improvement in three patients without significant adverse effects. Slight pain lasting for a day was the most common adverse event following MNRF.

**Conclusion:** Overall, significant improvement was observed in the majority of the patients without significant side effects.

**Keywords:** Microneedling radiofrequency, Patterned hair loss, Alopecia

### INTRODUCTION

Patterned hair loss is a common disorder of hair loss affecting both sexes characterized by miniaturization of hair follicles causing the transformation of terminal to vellus hairs resulting in patterned hair loss.<sup>1</sup> The disorder is not only a cosmetic concern but it also causes impairment of the quality of life of patients resulting in anxiety, depression, or even suicide.<sup>2</sup> Minoxidil and finasteride are the only US Food and Drug Administration (FDA)-approved medications for the treatment of patterned hair loss that constitute the backbone of therapy.<sup>3</sup> Other non-surgical therapies for patterned hair loss include dutasteride, spironolactone, platelet-rich plasma, microneedling, and low-level laser therapy.<sup>4-6</sup>

Microneedling, a concept introduced in 1995 by Orentreich, is a technique consisting of repeated puncturing of skin using sterile microneedles. Microneedling is proposed to improve hair growth through the release of growth factors.<sup>7</sup> Newer modalities combine mechanical puncturing of microneedling with fractional radiofrequency resulting in the release of energy from tips of microneedles called microneedling radiofrequency (MNRF). MNRF induces wound healing mechanisms through thermal damage. Following wounding, the stem cell population expresses molecular markers of follicle differentiation and activates the Wnt/ $\beta$ -catenin pathway resulting

This is an open-access article distributed under the terms of the Creative Commons Attribution-Non Commercial-Share Alike 4.0 License, which allows others to remix, transform, and build upon the work non-commercially, as long as the author is credited and the new creations are licensed under the identical terms.

©2024 Published by Scientific Scholar on behalf of Journal of Cutaneous and Aesthetic Surgery

in hair growth.<sup>8</sup> Energy-based devices have gained popularity due to limited non-invasive alternative therapeutic options available in the management of patterned hair loss.

## MATERIAL AND METHODS

### Aim and objectives

Our aim and objectives were to assess the efficacy of MNRF in the treatment of patterned hair loss concerning age, sex, and stage of hair loss. We also aimed to look at the most common adverse effects following the therapy.

### Study design

The study was designed as a prospective study using MNRF for the treatment of patterned hair loss in 24 patients from January 2021 to May 2022. Patients attending the dermatology outpatient department with a clinical diagnosis of patterned hair loss above 18 years and willing to participate in the study were included in the study. Pregnant ladies and lactating mothers were excluded from the study. Patients with concomitant scalp inflammatory disorders such as psoriasis and folliculitis were deferred from the procedure.

### Ethical considerations

A written and signed informed explanatory consent was taken from all the patients before initiation of therapy.

### Treatment protocol

Patients received 3 MNRF treatment sessions at once monthly intervals. A eutectic mixture of local anesthetic cream (25 mg prilocaine and 25 mg lidocaine) was applied topically to the scalp under occlusion for 60 min before the procedure. MNRF (Dermaindia, India) was delivered using a disposable tip containing 81 non-insulated microneedle electrodes, power of 2–6 W, microneedle penetrating depth of 1.5 mm, and pulse duration of 300 ms.

### Efficacy evaluation

#### Global assessment

Photographs were taken under controlled light by the same investigator (NB) in the same position. Two investigators (NB, SM) performed the clinical assessment based on the photographs taken at baseline and 1 month after 3<sup>rd</sup> session.

#### Trichoscopic assessment

Trichoscopic images (Escape, India) were taken at baseline, and 1 month after the last session at the same scalp location (15 cm from the glabella), and then the images were compared [Figure 1].

The assessment was measured on a seven-point scale and graded as follows:

- Excellent improvement (+3)
- Good improvement (+2)
- Fair improvement (+1)
- No change (0)
- Slightly worsened (–1)
- Moderately worsened (–2)
- Significantly worsened (–3).

Participants were also asked to give their assessment of the procedure using the same seven-point scale 1 month after the last session [Figures 2-6]

### Safety assessment

Patients were instructed to report any adverse events including bleeding, persistent pain, erythema, erosion, crusting, scaling, folliculitis and broken hair shafts following thermal damage. Patients were also asked to rate pain according to a visual analog pain scale (0 meaning no pain and 10 meaning the most severe pain).

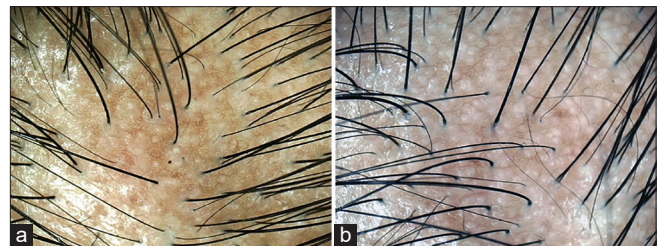
### Statistical analysis

Data were summarized as mean and standard deviation or median and range depending on the distribution of variables. Spearman rank correlation ( $\rho$ ) was performed between age and patient satisfaction score on improvement. A Chi-square test was performed to test the association between sex and alopecia grade with patient satisfaction score on improvement. Weighted-Kappa statistics were used to determine the interobserver agreement between investigators (1 and 2) and between investigators and patient satisfaction scoring.  $P < 0.05$  was considered statistically significant. Statistical analysis was performed using STATA/IC 16.0 (StataCorp, College Station, Texas 77845, USA).

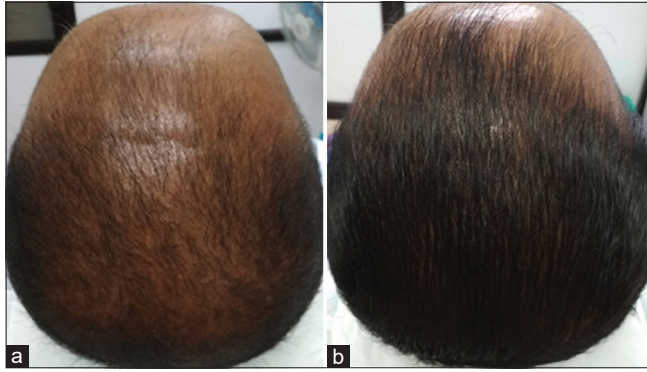
## RESULTS

### Patient demographics

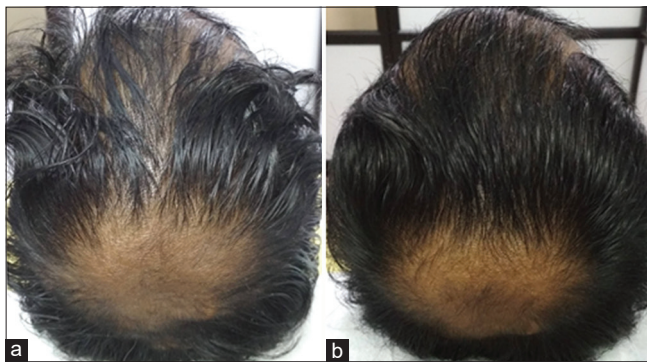
The median age of patients was 26.5 years (range 21–58) and 22 males and 2 females participated in the study [Table 1].



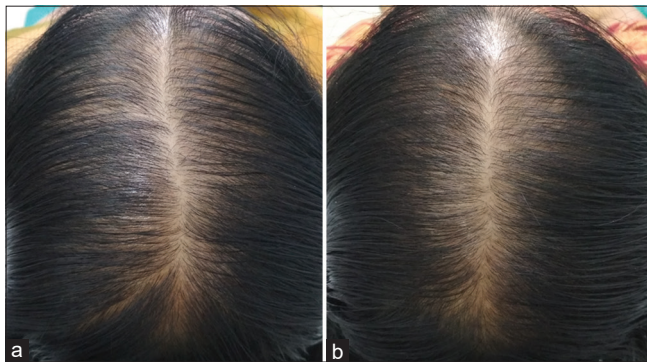
**Figure 1:** Trichoscopic evaluation (Escape, India  $\times 100$ ). (a) Before treatment. (b) After treatment showing fair improvement (+1).



**Figure 2:** Excellent improvement (+3). (a) Before treatment. (b) After treatment.



**Figure 3:** Good improvement (+2). (a) Before treatment. (b) After treatment.

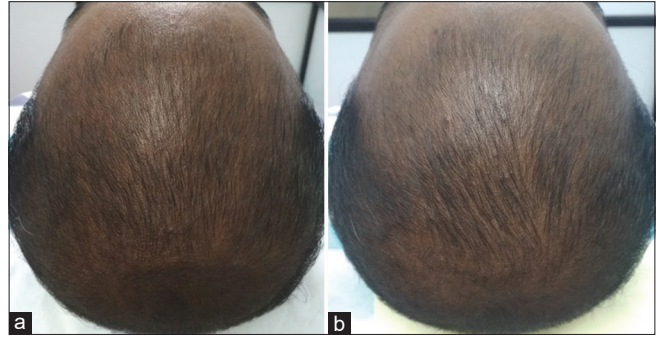


**Figure 4:** Fair improvement (+1). (a) Before treatment. (b) After treatment.

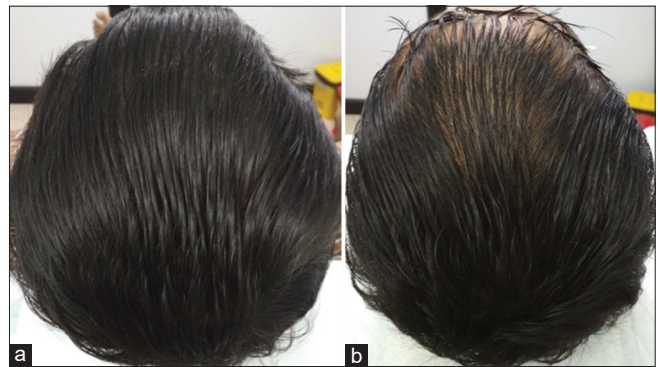The number of patients in each grade of alopecia includes Hamilton–Norwood scale Type III ( $n = 3$ ), Type IV ( $n = 9$ ), Type V ( $n = 7$ ), Type VI ( $n = 2$ ), Type VII ( $n = 1$ ), Ludwig scale Type II ( $n = 1$ ), and Type III ( $n = 1$ ).

**Comparison of patient satisfaction and inter-observer variation**

There was excellent/good improvement in 14 patients, fair improvement in seven patients, and no improvement/



**Figure 5:** No change (0). (a) Before treatment. (b) After treatment.



**Figure 6:** Slight Worsening (-1). (a) Before treatment. (b) After treatment.

**Table 1:** Characteristics of patients at baseline.

<b>Age</b>	Median=26.5 years (range 21–58)
<b>Sex</b>	Males=22 Females=2
<b>Grade of alopecia</b>	Hamilton–Norwood scale for males ( $n=22$ ) Type III=3 Type IV=9 Type V=7 Type VI=2 Type VII=1 Ludwig scale for females ( $n=2$ ) Type II=1 Type III=1

slight worsening in three patients. Global photographs showed clinical improvement in most participants, with hair regrowth in 91.67% (22/24) of participants [Table 2].

Kappa statistics was used to monitor the agreement between observers 1 and 2, patient and observer-1, and patient and observer-2. Weighted kappa scores between these three categories were 93.8%, 93.8%, and 89.6%, respectively, showing good agreement between them [Table 3].

**Table 2:** Grading of improvement by patient and observers.

Grading of improvement	Investigator 1	Investigator 2	Patient self-assessment
Excellent improvement (+3)	2	3	2
Good improvement (+2)	13	12	12
Fair improvement (+1)	7	5	7
No change (0)	0	3	3
Slight worsening (-1)	2	1	0
Moderate worsening (-2)	0	0	0
Significant worsening (-3)	0	0	0

Evaluation of improvement with respect to age, sex and alopecia grade.

There was no significant difference between age ( $P = 0.8771$ ), sex ( $P = 0.909$ ), and grade of alopecia ( $P = 0.895$ ) with clinical improvement.

### Adverse effects

Slight pain (average pain score 3) lasting for a day was the commonest adverse event following MNRF. One patient reported folliculitis and one reported scaling and dryness following treatment.

## DISCUSSION

MNRF produces its effects through dual mechanisms including mechanical wounding by microneedling and thermal injury by radiofrequency.<sup>8</sup> Following wounding, hair follicles express molecular markers of follicle differentiation through Wnt/ $\beta$ -catenin pathway activation. Cytokines (interleukins and tumor necrosis factor- $\alpha$ ) and inflammatory cells (macrophages) have an important role in the process. Microneedling causes upregulation of hair growth-related genes.<sup>9</sup> Moderate transient inflammation produces induction of the anagen phase. Wounding following thermal injury triggers the regeneration of hair follicles. MNRF causes inflammation resulting in increased blood flow and follicular vascularization. Radiofrequency released by MNRF results in the vibration of polar molecules and converts vibrating energy to thermal energy creating thermal zone columns. Fractional thermolysis and microchannels induced by MNRF facilitate the transdermal delivery of topicals through the creation of holes in the stratum corneum. In addition, MNRF can have a direct impact on bulge stem cells and dermal papilla.

Yu *et al.* reported combining MNRF with minoxidil to be more effective in terms of hair thickness, hair density, and slowing the progression of androgenetic alopecia in 19 patients attributed to direct effects of MNRF and increased efficacy of minoxidil as a result of enhanced penetration through thermal channels created by needles.<sup>8</sup> Lim *et al.* observed a significant increase in hair density, hair thickness, and hair count following MNRF in 19 out of 20 patients included in the study.<sup>10</sup>

**Table 3:** Agreement between investigators and investigator versus patient using weighted kappa statistics.

Comparison	Kappa analysis (%)
Investigator 1 versus Investigator 2	93.8
Investigator 1 versus patient	93.8
Investigator 2 versus patient	89.6

These results were in line with our study where 22 out of 24 patients (91.67%) of patients showed improvement following therapy. However, caution should be exerted not to damage the follicular and perifollicular structures using higher fluence, especially with non-insulated needles. The grading of improvement in our study was not significant with age, sex, and severity of alopecia suggesting that the improvement is independent of these variables.

## CONCLUSION

Good-excellent improvement was observed in the majority of the patients without significant side effects. Limitations of the study include not having a control group and a relatively small sample size. Future studies can be undertaken combining MNRF with platelet-rich plasma and growth factor concentrate as results can be mutually additive. The part of the scalp exhibiting maximum improvement with the procedure can also be evaluated in further studies. Thus, MNRF could potentially provide an effective and safe addition to the therapeutic armamentarium of patterned hair loss.

### Authors' Contributions

Nirmal B: Study conception and design, data collection, analysis and interpretation of results, manuscript preparation. S Shahin Mubeena: Analysis and interpretation of results. Belavendra Antonisamy: Analysis and interpretation of results, statistical analysis.

### Ethical approval

The research/study complied with the Helsinki Declaration of 1964.

### Declaration of patient consent

The authors certify that they have obtained all appropriate patient consent.

### Financial support and sponsorship

Nil.

### Conflicts of interest

There are no conflicts of interest.

### Use of artificial intelligence (AI)-assisted technology for manuscript preparation

The authors confirm that there was no use of artificial intelligence (AI)-assisted technology for assisting in the writing or editing of the manuscript and no images were manipulated using AI.

### REFERENCES

1. Kaliyadan F, Nambiar A, Vijayaraghavan S. Androgenetic alopecia: An update. *Indian J Dermatol Venereol Leprol* 2013;79:613-25.
2. Sehgal VN, Kak R, Aggarwal A, Srivastava G, Rajput P. Male pattern androgenetic alopecia in an Indian context: A perspective study. *J Eur Acad Dermatol Venereol* 2007;21:473-9.
3. York K, Meah N, Bhojru B, Sinclair R. A review of the treatment of male pattern hair loss. *Expert Opin Pharmacother* 2020;21:603-12.
4. Adil A, Godwin M. The effectiveness of treatments for androgenetic alopecia: A systematic review and meta-analysis. *J Am Acad Dermatol* 2017;77:136-41.
5. Nestor MS, Ablon G, Gade A, Han H, Fischer DL. Treatment options for androgenetic alopecia: Efficacy, side effects, compliance, financial considerations, and ethics. *J Cosmet Dermatol* 2021;20:3759-81.
6. Kanti V, Messenger A, Dobos G, Reygagne P, Finner A, Blumeyer A, *et al.* Evidence-based (S3) guideline for the treatment of androgenetic alopecia in women and in men - short version. *J Eur Acad Dermatol Venereol* 2018;32:11-22.
7. Kakizaki P, Contin LA, Barletta M, Machado CJ, Michalany NS, Valente NY, *et al.* Efficacy and safety of scalp microneedling in male pattern hair loss. *Skin Appendage Disord* 2023;9:18-26.
8. Yu AJ, Luo YJ, Xu XG, Bao LL, Tian T, Li ZX, *et al.* A pilot split-scalp study of combined fractional radiofrequency microneedling and 5% topical minoxidil in treating male pattern hair loss. *Clin Exp Dermatol* 2018;43:775-81.
9. Dhurat R, Sukesh M, Ganesh A, Ameet D, Anjali P, Poonam P. A randomized evaluator blinded study of effect of microneedling in androgenetic alopecia: A pilot study. *Int J Trichology* 2013;5:6-11.
10. Lim RK, Verner I, Wambier CG, Kolodchenko Y, Goren A. Nonablative radiofrequency for the treatment of androgenetic alopecia: An open-label study. *Dermatol Rev* 2021;2:1-3.

**How to cite this article:** Nirmal B, Shahin Mubeena S, Antonisamy B. Efficacy and safety of microneedling radiofrequency in patterned hair loss. *J Cutan Aesthet Surg.* 2024;17:189-93. doi: 10.25259/jcas\_44\_23