

Surgical Therapy by Sandwich Transplantation using a Dermal Collagen-Elastin Matrix and Full Thickness Split Grafts and Gait Rehabilitation with Individualized Orthosis

Painful callosities of the feet (PCOF) are a rare complaint in children with severe impairment of mobility and quality of life. There is no medical treatment available. We investigated the usefulness of a recently developed combined transplant technique—the sandwich transplantation with dermal collagen-elastin template in this rare condition. A 14-year-old boy suffered from PCOF for several years without any improvement by topical therapy, dermabrasion, and oral retinoids. He was unable to walk normally and suffered from severe pain. We performed a complete deep excision of the hyperkeratotic plantar tissue in general anaesthesia in combination with sandwich transplantation in the same setting. Dry sheets of collagen-elastin matrix (1 mm thickness) were placed on the soft tissue defects and covered by full-thickness mesh graft transplants from the upper leg. An individualized orthosis was produced for gait rehabilitation. Two weeks after surgery the gait-related pain was reduced remarkably. Using the orthosis, the boy was able to walk pain-free even on staircase. Surgery of PCOF with sandwich transplantation and gait rehabilitation appears to be a promising strategy for this rare condition.

KEYWORDS: Collagen-elastin template, pain, painful callosities of the feet, sandwich transplantation

INTRODUCTION

There are a number of skin diseases that can affect the feet including atopic dermatitis, psoriasis, mycosis, leprosy, blistering disorders, autoimmune connective tissue diseases etc., Hyperkeratotic plaques of soles may be a symptom of acquired (plantar warts, hyperkeratotic irritative contact dermatitis etc.) and inherited skin diseases (keratoderma, ichthyosis, psoriasis etc.).

Callosities develop as result of over-reactive keratinisation due to mechanical stress, either pressure and/or shear forces. Corns and calluses/clavi are the major types of callosities. Corns represent well circumscribed area of

traumatic hyperkeratosis with a translucent central core which often is painful. Callus or clavus describes a larger, less well defined, often painless hyperkeratotic plaque without a central core.

Painful callosities of feet (PCOF) are a very rare and not well understood condition among children. The condition has been included into dermatologic and pediatric handbooks but epidemiologic data are missing. In a podiatry screening project with almost 9,000 children in the District of Columbia to identify diseases of feet and problems with foot wear, not a single case of this condition had been observed.^[1]

PCOF are characterized by massive compact orthohyperkeratotic plaques located in plantar areas of support disabling normal walking. No associated symptoms of hair, nails, nerves or skin glands have been described. The disease is not inherited and no PCOF families have been described. The pathogenesis of this disease is poorly understood. Accelerated keratinocyte proliferation, decreased desquamation

Access this article online	
Quick Response Code: 	Website: www.jcasonline.com
	DOI: 10.4103/0974-2077.104917

Uwe Wollina, Birgit Heinig¹

Department of Dermatology and Allergology and ¹Centre of Physical Therapy and Rehabilitation, Academic Teaching Hospital Dresden-Friedrichstadt, Dresden, Germany

Address for correspondence:

Dr. Uwe Wollina, Department of Dermatology and Allergology, Academic Teaching Hospital Dresden-Friedrichstadt, Friedrichstrasse, Dresden, Germany.

E-mail: wollina-uw@khdf.de

and impaired differentiation a key findings. There is increased expression of certain adhesion molecules like corneodesmosin, desmoglein 1, and desmocollin 1 contributing to decreased desquamation.^[2] Callosities are increasing the focal stress in affected soft tissue.^[3] Obviously there is a participation of nerves/pain receptors in PCOF but scientific proof is lacking.

We report a 14 year-old boy with PCOF treated successfully by surgery.

CASE REPORT

A 14 year-old slim boy presented with a 6 year history of painful massive hyperkeratotic plaques on his soles making pain-free walking impossible [Figure 1]. Painkillers, dermabrasion of hyperkeratotic plaques by diamond mill, topical ointments with salicylic acid and urea, systemic antimycotics, and oral retinoids were all ineffective. Therefore, the family was seeking for help at our department. Family history was unremarkable.

We made a detailed clinical examination of the boy. On the toes, forefoot and heels massive plantar, yellowish, malodorous, compact hyperkeratotic plaques were visible. Nails and teeth were normal, hair was short. Mycological cultures were performed from these plaques and from the scalp hair. Trichomycosis was confirmed.

To establish diagnosis a deep skin biopsy was performed from the painful plantar region. Histopathological examination disclosed a massive compact orthohyperkeratosis without any dermal changes and without inflammatory infiltrates. No fungal elements were seen.

Musculature of calves was hypotrophic but joint mobility was not impaired. Peripheral sensory or motor neuropathy was excluded by the neurologist. He had a

toe and lateral gait and could only move with bended knees due to the massive pain. Muscular or osseous foot deformities were not found.

Pain scores were measured by visual analogue scale with 100 mm for the most severe pain and 0 mm for no pain at all [Table 1]. The combination of painful orthohyperkeratotic plaques of the plantar region associated with extreme pain, absence of associated symptoms and negative family history confirmed the diagnosis of PCOF.

Treatment and outcome: We performed a deep excision of the painful callosities in general anaesthesia. Soft tissue defects were closed by sandwich transplantation using a dermal elastin-collagen matrix (MatriDerm®; Dr. Suwelack Skin and Health Care AG, Billerbeck, Germany) covered by split full thickness skin. Details of this technique have been described elsewhere.^[4] In the present case we used the 1 mm thick dermal template dry not reconstituted before grafting [Figure 2a-c]. After graft take a foot-and-lower-leg (knee-ankle foot orthosis-KAFO) moulded orthosis was adjusted for the boy to support normal biomechanics of the feet and ankle during the rehabilitation process. Pain was markedly reduced after surgery [Table 1]. With the orthosis the first walking steps were possible after 2 weeks without the need of painkillers [Figure 3]. There was no malodour of the feet after surgery. Plantar grafts became partially necrotic but wound healing was uneventful after necrectomy. A physical mobilization programme with gait education was started during inpatient treatment and continued thereafter for 4 weeks.

In addition trichomycosis was treated by antimycotics and hair re-growth was observed.

DISCUSSION

PCOF are very rare but severely disabling. Pain is preventing any normal biomechanics of feet and ankle making movements almost impossible. PCOF callosities can deprive children of physical activities, childhood experiences, and a healthy life style. There is no topical or systemic drug therapy available for cure. Oral retinoids do not decrease the pain, although they may reduce hyperkeratosis in inherited forms of

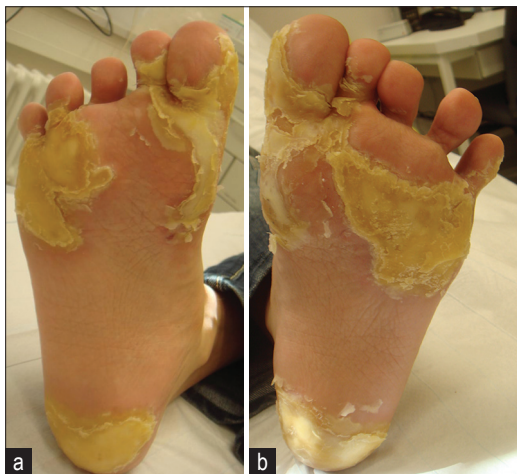

Figure 1: Painful callosities of the feet; (a) Right foot, (b) left foot

Table 1: Pain scores before and during therapy (Visual analogue scale)

	VAS	Day
Before treatment	10	0
After sandwich transplantation	6	6
After removal of steel brackets and use of orthosis	3	14
After necrectomy	2	28

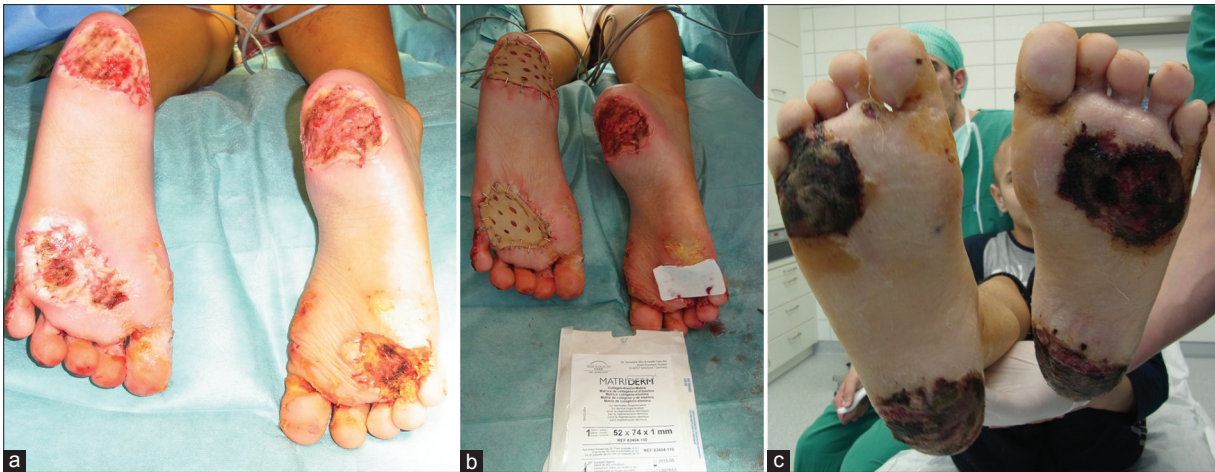

Figure 2: Surgery and sandwich transplantation. (a) Deep excision of plantar callosities. (b) Sandwich transplantation. (c) 18 days after transplantation

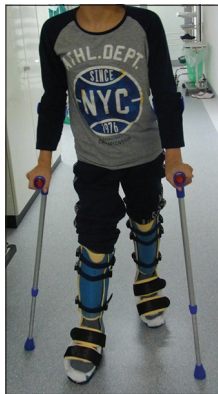

Figure 3: Almost normal and pain free gait with KOFA-orthosis 18 days after surgery

plantar hyperkeratosis (keratoderma). In the present case, however, they were of out of benefit. The disease affects normal physical development in children and adolescents and impairs psychological well being.

Painful callosities of the feet may have different background, i.e., primary or secondary. Most scientific data come from secondary type including treatment. Foot diseases become more frequent with age. Foot pain caused by corns, calluses, and callosities is common in the adult population in contrast to PCOF in children. Factors contributing to corns and calluses/clavi in the adult population are footwear, peripheral neuropathy, osteoarthritis, and obesity. The incidence of corns is 3-5 % in the adult population but reaches >10% in patients ≥ 75 years of life. There is general Belief that mechanical stress is involved but perception and copying with pain also contribute to its magnitude and the resulting impairment or disability.^[5,6]

In a randomized controlled trial in 38 patients with

painful plantar callosities in rheumatoid arthritis, scalpel debridement of hyperkeratoses improved pain, stride-strength, and walking speed but the effect was not statistically different from sham operation.^[3] In a recent trial, 59 patients with either chronic neurovascular, neurofibromatous and hard corns were randomized to either with standard sharp debridement or electrosurgery. A significant reduction of pain was achieved by electrosurgery at 6 months follow-up in 76% of patients. The complete response rate was 26% versus 4% in the control group.^[7]

Due to the rareness of PCOF in children no trials have been conducted. However, Atlan *et al.* (2011) reported a successful surgical therapy of constitutional painful callosities in an adult female by surgical excision, elastin-collagen matrix and split thickness skin grafts placed above. In this study adjuvant negative pressure therapy was applied above the graft to support graft take.^[8]

After radical excision of the PCOF we also employed a dermal elastin-collagen template in the present case combined with full thickness mesh graft in a sandwich technique.^[4,9] In contrast to superficial removal of hyperkeratotic horny layer the deep excision of the lesions down to the muscle fascia resulted in a rapid pain relief. In order to improve early rehabilitation in our adolescent boy a specifically tailored KAFO moulded orthosis was employed. It has been demonstrated recently that moulded orthoses produce larger reduction in loading rate and vertical impact force when compared with a control and to a posted non-moulded orthoses.^[10] Two weeks after surgery pain was markedly reduced and his gait normalized. He could now walk in an upright carriage. During the next two weeks he was able to climb stairs unaided. There will be a longer time necessary to establish a normal walking without KAFO moulded

orthosis but the progress he made in short time raises hopes of a normal life in future for this boy.

REFERENCES

1. Shapiro J, Rhee CS. Podiatry screening project for children in the District of Columbia. *Public Health Rep* 1970;85:803-8.
2. Kim SH, Kim S, Choi HI, Choi YJ, Lee YS, Sohn KC, *et al.* Callus formation is associated with hyperproliferation and incomplete differentiation of keratinocytes, and increased expression of adhesion molecules. *Br J Dermatol* 2010;163:495-501.
3. Davys HJ, Turner DE, Helliwell PS, Conaghan PG, Emery P, Woodburn J. Debridement of plantar callosities in rheumatoid arthritis: A randomized controlled trial. *Rheumatology (Oxford)* 2005;44:207-10.
4. Wollina U. One-stage reconstruction of soft tissue defects with the sandwich technique: Collagen-elastin dermal template and skin grafts. *J Cutan Aesthet Surg* 2011;4:176-82.
5. Verhoeven EW, Kraaijaat FW, van Weel C, van de Kerkhof PC, Duller P, van der Valk PG, *et al.* Skin diseases in family medicine: Prevalence and health care use. *Ann Fam Med* 2008;6:349-54.
6. Hawke F, Burns J. Understanding the nature and mechanism of foot pain. *J Foot Ankle Res* 2009;2:1.
7. Bevens JS, Bosson G. A comparison of electrosurgery and sharp debridement in the treatment of chronic neurovascular, neurofibrous and hard corns. A pragmatic randomized controlled trial. *Foot (Edinb)* 2010;20:12-7.
8. Atlan M, Naouri M, Lorette G, Estève E, Zakine G. [Original treatment of constitutional painful callosities by surgical excision, collagen/elastin matrix (MatriDerm®) and split thickness graft secured by negative wound therapy]. *Ann Chir Plast Esthet* 2011;56:163-9.
9. Wollina U, Meseg A, Weber A. Use of collagen-elastin matrix for hard to treat soft tissue defects. *Int Wound J* 2011;8:291-6.
10. Mills K, Blanch P, Chapman AR, McPoil TG, Vicenzino B. Foot orthoses and gait: A systematic review and meta-analysis of literature pertaining to potential mechanisms. *Br J Sports Med* 2010;44:1035-46.

How to cite this article: Wollina U, Heinig B. Surgical therapy by sandwich transplantation using a dermal collagen-elastin matrix and full thickness split grafts and gait rehabilitation with individualized orthosis. *J Cutan Aesthet Surg* 2012;5:277-80.

Source of Support: Nil. **Conflict of Interest:** None declared.

New features on the journal's website

Optimized content for mobile and hand-held devices

HTML pages have been optimized for mobile and other hand-held devices (such as iPad, Kindle, iPod) for faster browsing speed.

Click on **[Mobile Full text]** from Table of Contents page.

This is simple HTML version for faster download on mobiles (if viewed on desktop, it will be automatically redirected to full HTML version)

E-Pub for hand-held devices

EPUB is an open e-book standard recommended by The International Digital Publishing Forum which is designed for reflowable content i.e. the text display can be optimized for a particular display device.


Click on **[EPub]** from Table of Contents page.

There are various e-Pub readers such as for Windows: Digital Editions, OS X: Calibre/Bookworm, iPhone/iPod Touch/iPad: Stanza, and Linux: Calibre/Bookworm.

E-Book for desktop

One can also see the entire issue as printed here in a 'flip book' version on desktops.

Links are available from Current Issue as well as Archives pages.

Click on  View as eBook