

# Dual Toning Method with the Combination of Picosecond and Microsecond Nd:YAG in Refractory Melasma Unresponsive to Picosecond Alone

Le Hai, Bui Phuong, Le Ha, Vu Lam, Bui Van, Firas Al-Niaimi<sup>1</sup>

Dermatology Department, 108 Central Military Hospital, Hanoi, Vietnam, <sup>1</sup>Department of Dermatology, Aalborg University Hospital, Aalborg, Denmark

## Abstract

**Background:** Melasma is an acquired and treatment-resistant aging facial skin condition prevalent among the older Asian females. The Q-switched toning laser is the most widely used for the treatment of moderate to severe melasma in Asia. Recently, the picosecond laser has been introduced for various pigmentary disorders such as melasma. We evaluated the efficacy and safety of dual toning combined with 1064nm Nd:YAG picosecond and quasi-long-pulsed laser in the treatment of severe melasma. **Subjects and Methods:** Twenty Vietnamese females, mean age  $41.9 \pm 6.4$  years, Fitzpatrick skin type IV, with clinical diagnosis of severe dermal and mixed-type melasma were treated by at least eight sessions picosecond Nd:YAG 1064nm reducing Melasma Area and Severity Index (MASI) to less than 15%. Then they were treated with 3 sessions of dual toning combined picosecond Nd:YAG 1064nm laser having an energy and spot size of 0.6–0.8 J/cm<sup>2</sup> and 8mm with micropulsed mode Nd:YAG 1064nm laser (350  $\mu$ s) having an energy and spot size of 2.6 J/cm<sup>2</sup> and 15mm with ICD off. Mild and even erythema was the endpoint (40–42°C using the infrared thermometer). Treatments were given every 4 weeks. Improvement was rated by MASI at the baseline (T1), after eight sessions of picotoning (T2), and three sessions of dual toning (T3). **Results:** The mean MASI score of 20 patients at baseline (T1) was  $16.24 \pm 4.88$  (min 6.0; max 28.8); after at least eight picotoning sessions, the mean MASI was  $15.12 \pm 4.69$ , representing a  $7.44 \pm 4.41\%$  reduction in MASI score. The MASI score of the dual toning laser continued to decrease after three dual toning sessions from  $15.12 \pm 4.6$  to  $9.77 \pm 3.86$  (MASI score reduced by a mean of  $5.35 \pm 2.64$ ), achieving  $35.15 \pm 13.51\%$  reduction from T2 and  $40.17 \pm 12.14\%$  reduction from baseline MASI (T1). There were no unexpected side effects in any patients. **Conclusion:** The dual toning method using the 1064nm Nd:YAG picosecond and microsecond laser was safe and effective and well tolerated by all patients without downtime. However, larger number of studies should be conducted with more objective measurement techniques to confirm the results of this preliminary study.

**Keywords:** Laser Nd:YAG, melasma, picosecond laser, rejuvenation

## INTRODUCTION

Melasma is a commonly acquired, chronic hyperpigmentary disorder characterized by localized, symmetrical, irregular, and light-to-dark brown macules occurring in sun-exposed areas of the skin, particularly on the face. The condition is most commonly observed in females in their thirties with a higher prominence in darker skin types, especially Asians. The pathogenesis of melasma is very complicated and has not yet been fully elucidated, which as a result challenges in management of the condition.<sup>[1]</sup> Since 1983, based on Anderson and Parrish's concept of selective photothermolysis,<sup>[2]</sup> Q-switched laser (nanosecond pulse width) has been the gold standard

for treatment of hyperpigmentation including melasma, in addition to topical lightening agents.<sup>[3]</sup> Some authors had been combining Q-switched laser with microsecond Nd:YAG 1064nm laser in order to reduce the side effects of laser toning.<sup>[4]</sup> Over the past few years, the picosecond-pulsed laser systems were introduced with shortening pulse durations creating a largely photomechanical effect on the targeted tissue with the subsequent hypothesis that

**Address for correspondence:** Dr. Firas Al-Niaimi,  
Department of Dermatology, Aalborg University Hospital,  
Aalborg, Denmark.  
E-mail: [firas55@hotmail.com](mailto:firas55@hotmail.com)

This is an open access journal, and articles are distributed under the terms of the Creative Commons Attribution-NonCommercial-ShareAlike 4.0 License, which allows others to remix, tweak, and build upon the work non-commercially, as long as appropriate credit is given and the new creations are licensed under the identical terms.

**For reprints contact:** [reprints@medknow.com](mailto:reprints@medknow.com)

**How to cite this article:** Hai L, Phuong B, Ha Le, Lam Vu, Van B, Al-Niaimi F. Dual toning method with the combination of picosecond and microsecond Nd:YAG in refractory melasma unresponsive to picosecond alone. *J Cutan Aesthet Surg* 2021;14:101-6.

### Access this article online

#### Quick Response Code:



**Website:**  
[www.jcasonline.com](http://www.jcasonline.com)

**DOI:**  
10.4103/JCAS.JCAS\_30\_20

applying a 1064 nm picosecond Nd:YAG (PSNY) laser to treat melasma should achieve better result compared to Q-switched Nd:YAG (QSNY) laser.<sup>[5,6]</sup>

## MATERIALS AND METHODS

### Subjects

A total of 20 Vietnamese females with Fitzpatrick skin type IV, age ranging from 31 to 58 years (mean 41.9 ± 6.4 years), with the clinical diagnosis of dermal and mixed-type melasma were treated in the laser and cosmetic department of the 108 Central Military Hospital, Vietnam, during the period of August 2018 to October 2019. Patient demographics are given in Table 1.

The exclusion criteria included skin lesions in the treated area; pregnant or breastfeeding; photosensitivity; and the use of oral contraceptive pills, hormone replacement, topical bleaching or chemical peeling within last 1 month.

Patients were informed of the study procedures, risks, benefits, potential complications, and side effects. Informed consent was obtained prior to treatment.

### Study design

The study was designed to assess the efficacy of the combination of picotoning laser with sub-millisecond (microsecond) Nd:YAG in the treatment of severe melasma

in Vietnamese patients who were unresponsive to or had poor response to picotoning alone. Poor response was defined as a Melasma Area and Severity Index (MASI) reduction of less than 15% following the eight sessions of picotoning at 4-week interval.

A total of 20 patients were identified, all of whom had less than 15% MASI score reduction, and were treated with the combination of Nd:YAG picotoning followed immediately by sub-millisecond Nd:YAG in the same session at monthly intervals. A total of three treatments were performed, following which the improvement was evaluated using the MASI score at baseline (T1), at the session before using dual toning technique (T2) (after at least eight sessions using only picotoning) and after the third session using dual toning (T3—from 9th to 12th session combining picotoning and long-pulsed Nd:YAG [LPNY]) by two blinded independent dermatologists.

Statistical analysis was performed using SPSS version 21.0 software package (Armonk, NY, USA). Descriptive statistics were presented as mean ± standard deviation. The statistical significance value was accepted as *P* < 0.05.

### Laser treatment

The first part of the treatment was picotoning using the parameters 1064 nm Nd:YAG (PicoWay; Candela, Weyland, Massachusetts, USA) with a spot size

**Table 1: Patient demographics**

No.	Age	Sex	Diagnosis	MASI T1	MASI T2	MASI T3	Improvement of MASI (% T2/T1)	Improvement of MASI (% T3/T2)
1	46	F	Mixed melasma and aging skin	15.9	15.6	6	1.9	61.5
2	48	F	Mixed melasma and aging skin with many deep wrinkles	16.2	14.4	9	11.1	37.5
3	43	F	Mixed melasma and ABNOM	14	12.4	9.6	11.4	22.6
4	31	F	Mixed melasma and ABNOM	13.5	12	9.6	11.1	20.0
5	46	F	Mixed melasma and ABNOM	13.2	12	9	9.1	25.0
6	33	F	Mixed melasma	15.3	14.4	6	5.9	58.3
7	47	F	Mixed melasma and aging skin	24	23.1	18.3	3.8	20.8
8	39	F	Mixed melasma and ABNOM	13.6	12	6	11.8	50.0
9	49	F	Mixed melasma, wrinkles, and large pores	15.5	15.3	11.4	1.3	25.5
10	40	F	Mixed melasma, ABNOM, and aging skin	16.1	15	11	6.8	26.7
11	35	F	Mixed melasma	6	4.8	3.6	20.0	25.0
12	39	F	Mixed melasma, mottled hypopigmentation, and aging skin	28.8	26	19.3	9.7	25.8
13	40	F	Mixed melasma and ABNOM	16.3	15.2	10.5	6.8	30.9
14	37	F	Mixed melasma	15.2	14	10.6	7.9	24.3
15	39	F	Mixed melasma and ABNOM	10.4	9.8	5.4	5.8	44.9
16	38	F	Mixed melasma and aging skin	16.2	15.3	11.4	5.6	25.5
17	44	F	Mixed melasma and ABNOM	14.8	14.6	9	1.4	38.4
18	58	F	Mixed melasma, mottled hypopigmentation, and aging skin	21	19.7	8.2	6.2	58.4
19	38	F	Mixed melasma, mottled hypopigmentation, and aging skin	22.5	21.6	12.4	4.0	42.6
20	40	F	Mixed melasma	16.2	15.0	9.0	7.4	40.0

F = female, ABNOM = Acquired bilateral naevus of Ota macules

of 8 mm, 0.6–0.8 J/cm<sup>2</sup> pulse energy based on skin type and severity of pigmentation,<sup>[7]</sup> and 10 Hz pulse repetition. Two to three passes were made over the entire hyperpigmentation area of the face with a 20–30% overlap. The clinical endpoint was immediate lightening of hair follicles or mild erythema without petechiae.

The treatment protocol for the dual toning technique was as follows: initially, treated with picotoning as described above and followed immediately by microsecond Nd:YAG (clarity, Lutronic) with a 15 mm spot size, 0.35 ms, and 2.6 J/cm<sup>2</sup>, repetition rate of 10 Hz, and cooling off. Multiple passes were made to stack pulses (painting motion technique) with the desired endpoint being mild and even erythema of the whole face. Infrared thermometer is used to measure the temperature on the facial skin surface with the aim to reach a temperature of 40–42°C. A cooling pack was applied following the dual toning session and patients were able to return immediately to their usual daily activities. Patients were instructed to apply a UVA/B sunscreen with an SPF of at least 30 on daily basis as well as a moisturizing cream. Patients received a total of three combined treatments at monthly basis.

Any possible complications and side effects (erythema, edema, burning, petechiae, acute urticaria, post-inflammatory hypopigmentation, and hyperpigmentation) were recorded.

### Assessment of response

Two blinded independent dermatologists reviewed the clinical photographs to determine the degree of improvement and scored the MASI, as well as any complications. In addition, all patients completed a questionnaire to assess their subjective satisfaction with the laser treatment using a five-point grading system

as follows: very satisfied, satisfied, somewhat satisfied, dissatisfied, and very dissatisfied.

## RESULTS

The mean MASI score of 20 patients at baseline (T1) was 16.24 ± 4.88 (min 6.0; max 28.8); after at least eight picotoning sessions, the mean MASI was 15.12 ± 4.69, representing a 7.44 ± 4.41% reduction in MASI score. The MASI score of the dual toning laser continued to decrease after three dual toning sessions from 15.12 ± 4.69 to 9.77 ± 3.86 (MASI score reduced by a mean of 5.35 ± 2.64), reducing 35.15 ± 13.51% from T2 and 40.17 ± 12.14% from baseline MASI (T1) [Figure 2].

In addition to the objective improvement in the melasma, patients also noted an improvement in skin tone, smoother skin texture, and uniform pigmentation or a photorejuvenation effect [Figure 3].

All patients had no adverse or unexpected side effects. Erythema was mild and transient lasting for 30 min to 2 h and could easily be covered by makeup. No patient reported excess pain during dual toning treatment.

## DISCUSSION

The prevalence of melasma varies with the ethnicity of the population<sup>[8]</sup> and contributes to 4–10% of new cases in dermatological clinics.<sup>[9]</sup> The etiopathogenesis of melasma has not yet been fully elucidated. To better understand such challenges, some authors have reviewed diverse histologic features of melasma such as basement membrane disruption,<sup>[10]</sup> solar elastosis, increased vascularization, and an increased number of mast cells.<sup>[11]</sup> A variety of treatment options have been suggested for the management of melasma. These include topical medications (such as hydroquinone, azelaic acid, arbutin, kojic acid, and tranexamic acid), chemical

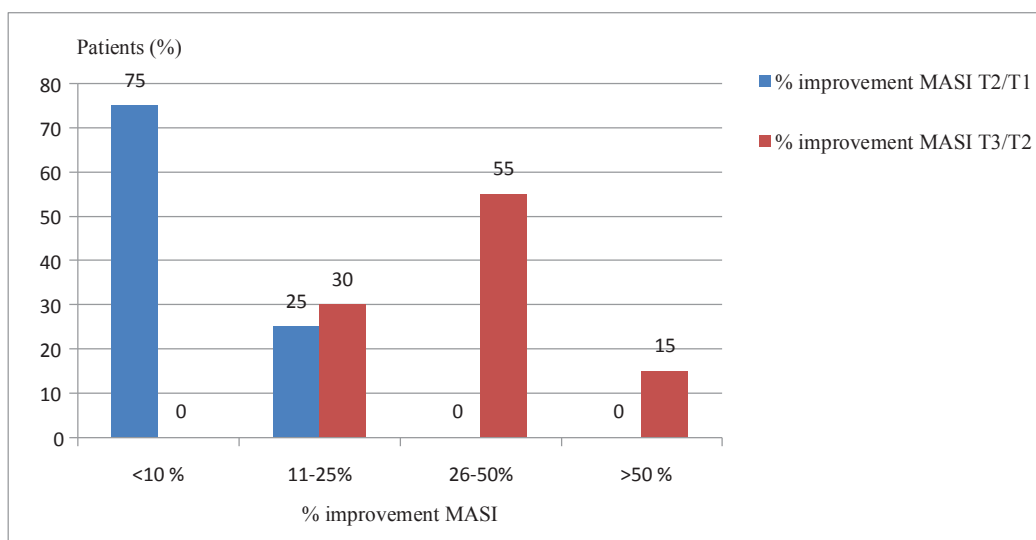


Figure 1: Percentage improvement of MASI after eight sessions of PSNY toning (T2/T1) and after three sessions of dual toning (T3/T2)

peels, oral medications (antioxidants and tranexamic acid), lasers, and lights.<sup>[12]</sup> The laser and light treatments were reserved for patients with refractory melasma who failed to respond to topicals and chemical peels.<sup>[3]</sup> Goldberg and Metzler<sup>[13]</sup> first suggested the concept of “laser toning” that uses multiple passes with low-fluence QSNY and has been accepted as a new gold standard of melasma treatment in Asia and is recognized as the most effective treatment for patients with moderate to severe or the dermal or mixed-type melasma.<sup>[14,15]</sup> Kim *et al.*<sup>[16]</sup> used the same technique in zebrafish skin to selectively destroy the melanosomes without cell death. This opened up a new and safe modality of the treatment of melasma. Since then, many reports were published especially from Asia. Sim *et al.*<sup>[17]</sup> used laser toning to treat melasma in 50 Asian patients with an improvement rate of 50–74%, whereas Choi *et al.*<sup>[18]</sup> reported two of 20 patients developing mottled hypopigmentation and rebound hyperpigmentation. Over the past few years, the picoseconds-pulsed laser systems were introduced to treat tattoo and benign hyperpigmentation, including melasma. Picosecond laser pulses create a largely photomechanical effect on the targeted tissue, accompanied by a diminished photothermal effect. The physical effects associated with optical breakdown are plasma formation and shock wave generation leading to photo disruption. This allows for more safety during treatment as the major effect on the

tissue does not rely on simply heating it to a high degree and accepting the risks involved.<sup>[5,6]</sup> Some authors<sup>[6-19]</sup> believe that applying a picosecond laser to treat melasma achieves better result compared to QSNY so that we may have the same or higher efficacy in decreasing the amount of melanin. Laser toning can be combined with various other topical or physical treatment modalities, even different lasers to obtain better efficacy and to increase the safety of treatment by minimizing complications. Some researches considered quasi-long pulse or sub-millisecond pulse 1064nm Nd:YAG laser as the “genesis technique” and is used for nonablative skin rejuvenation via collagen remodeling and neocollagenesis. Furthermore, it also promotes wound healing by inducing heat shock protein and transforming growth factor beta and by reducing the levels of the proinflammatory cytokine interleukin-8.<sup>[14]</sup> Thus, microsecond Nd:YAG laser does not directly target melanosomes hence it has not been shown to effectively treat melasma as a standalone modality, instead it might improve the altered dermal environment of melasma hence the synergism with laser toning.<sup>[4,14-20]</sup> According to this theory, we decided to combine PSNY toning with microsecond 1064nm Nd:YAG and our results scientifically improved. Since 2017, in our department, all patients having melasma were treated with picotoning Nd:YAG laser. A proportion of patients with severe melasma did not respond to picotoning laser (5%—data

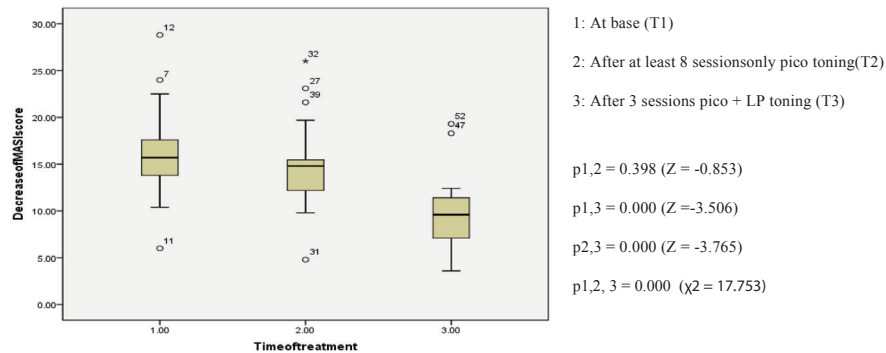


Figure 2: Average of MASi improvement according to T1, T2, and T3 treatments

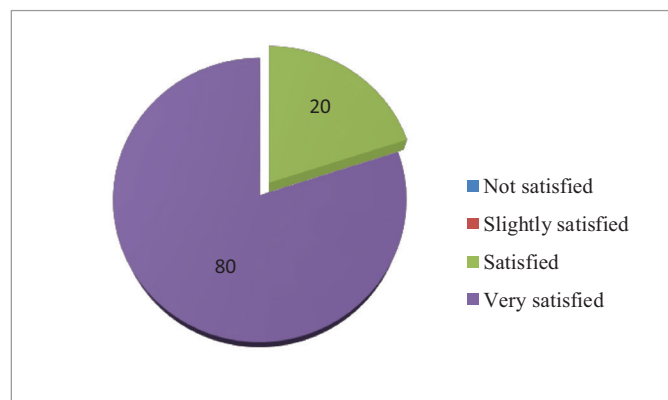


Figure 3: Estimated satisfaction level

not included in this paper; with MASI  $>8.7^{[21]}$ ). In our study, there were 20 patients with MASI at baseline (T1) of  $16.24 \pm 4.88$  (min 6.0; max 28.8); after at least eight picotoning sessions, the mean MASI was  $15.12 \pm 4.69$ , representing a  $7.44 \pm 4.41\%$  reduction in MASI score. These results mean that these patients responded poorly to picotoning. In our study, the MASI score continued to decrease significantly after three dual toning sessions to  $9.77 \pm 3.86$  (MASI score reduced by a mean of  $5.35 \pm 2.45$ ) underscoring the synergistic value of combining both modalities [Figures 1 and 2]. Our data show that after three sessions using dual toning technique, the improvement in MASI score with the reduction of  $35.15 \pm 13.51\%$  from T2 and  $40.17 \pm 12.14\%$  from baseline MASI (T1) is an effective treatment for dermal and mixed-type melasma. It is highly unlikely that the MASI would drop this significantly with picotoning alone given the poor response in the previous eight sessions. We firmly believe it is the synergistic effect as evidenced by the marked improvement as soon as the combination treatment commenced. It is possible that in some patients with melasma a combination approach targeting both the melanosomes and the dermal microvascular component is needed rather than the melanosomes alone.

In addition, all patients had a significantly improved skin quality compared to picotoning alone [Figures 4 and 5]. The improvement of our MASI score is higher than that of Kim *et al.*<sup>[15]</sup> where after five Q-switched pulse-to-pulse

(QS-PTP) laser treatments in 22 female patients, the MASI score was reduced ( $5.46 \pm 2.9$  to  $4.35 \pm 1.99$ ) about 20.3%. And Kang *et al.*<sup>[4]</sup> combined QSNY and LPNY when treating 30 females of similar age as in our study or Kim's study; however, when evaluating the results of treatment after 6 weeks of the last treatment, the author assessed the level of improvement by five levels of color improvement (visual scale grades). They noted that 10% did not improve, 23% improved from 11% to 25%, and 67% improved from 26% to 50%. In our study, 100% of the patients had an improved MASI score. Thus, the dual mode of low-fluence PSNY and microsecond Nd:YAG may exert synergistic effects in the treatment of melasma.

Additionally, in nonablative laser treatment, degeneration of collagen fibers requires the temperature of 55–65°C in the dermis, which is equal to 40–42°C on the skin surface.<sup>[20-22]</sup> In our study, we used infrared thermometer to measure the temperature on the skin surface following the laser treatment.

Besides, the interval between treatments also plays an important role. Wattanakrai *et al.*<sup>[23]</sup> suggested that to minimize complications, use of too many (more than five approaching up to 10 treatments) or too frequent (every week) QSNY laser sessions should be discouraged. Although picotoning laser has reduced the thermal effects, the skin needs time to recover and eliminate pigmentation so we decided to use dual toning technique with longer intervals.

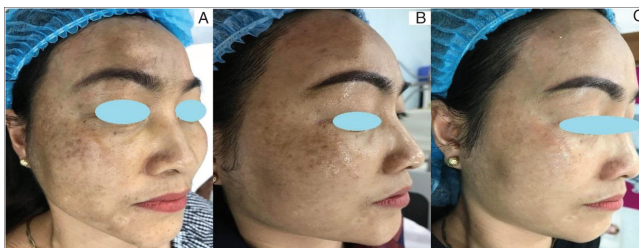
We considered that further increasing the number of treatment sessions may show a better effect because of the reduction in MASI with ongoing treatments. We were keen to initially not exceed a maximum of 12 sessions as this was the maximum number of treatments used in two studies that combined QSNY with microsecond Nd:YAG in melasma.<sup>[4,14]</sup> We will assess next session and follow-up longer. To the best of our knowledge, this is the first study to examine the safety and efficacy of the dual toning technique combining picosecond laser and microsecond laser in the treatment of melasma in Asian patients.

## CONCLUSIONS

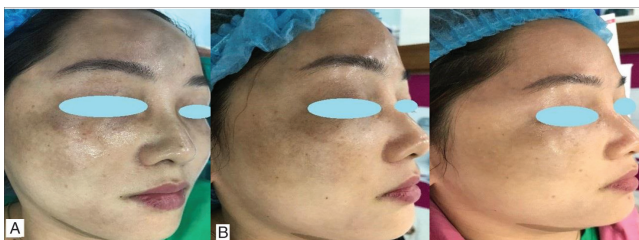Dual toning combining Nd:YAG picosecond with microsecond-pulsed laser may represent a good solution for Asian patients with severe melasma, achieving skin lightening together with skin rejuvenation to restore a healthy skin. This combination can be beneficial particularly in nonresponders to picotoning alone. The approach is effective, side effect free, well tolerated, and minimally invasive with no downtime for the patient. However, larger controlled studies should ideally involve more patients to confirm the results of this preliminary study.

## Financial support and sponsorship

Nil.



**Figure 4:** Clinical findings in a 46-year-old female patient (patient No. 5). (A) MASI score at baseline condition was 13.2. (B) After eight sessions of picotoning the MASI score was 12. (C) After three sessions of dual toning, that is, Nd:YAG pico + Nd:YAG long-pulse with micropulse mode with MASI score of 9 (reduced 25%)



**Figure 5:** Clinical findings in a 33-year-old female patient (patient No. 6). (A) MASI score at baseline condition was 15.3. (B) After eight sessions of picotoning the MASI score was 14.4. (C) After three sessions of dual toning, that is, Nd:YAG pico + Nd:YAG long-pulse with micropulse mode with MASI score of 6 (reduced 58.3%)

### Conflicts of interest

There are no conflicts of interest.

### Obtained of patient consent

The authors certify that they have obtained all appropriate patient consent forms. In the form the patient(s) has/have given his/her/their consent for his/her/their images and other clinical information to be reported in the journal. The patients understand that their names and initials will not be published and due efforts will be made to conceal their identity, but anonymity cannot be guaranteed.

### REFERENCES

1. Passeron T. Melasma pathogenesis and influencing factors—An overview of the latest research. *Eur Acad Dermatol Venereol* 2013;27:5-6.
2. Anderson R, Parrish A. Selective photothermolysis Anderson and Parish 1983. *Science* 1983;220:524-7.
3. Trivedi MK, Yang FC, Cho BK. A review of laser and light therapy in melasma. *Int J Womens Dermatol* 2017;3:11-20.
4. Kang HY, Kim JH, Goo B. The dual toning technique for melasma treatment with the 1064nm Nd:YAG laser: A preliminary study. *Laser Ther* 2011;20:189-94.
5. Kasai K. Picosecond laser treatment for tattoos and benign cutaneous pigmented lesions (secondary publication). *Laser Ther* 2017;26:274-81.
6. Lee MC, Lin YF, Hu S, Huang YL, Chang SL, Cheng CY, *et al.* A split-face study: Comparison of picosecond alexandrite laser and Q-switched Nd:YAG laser in the treatment of melasma in Asians. *Lasers Med Sci* 2018;33:1733-8.
7. Shah SD, Aurangabadkar SJ. Laser toning in melasma. *J Cutan Aesthet Surg* 2019;12:76-84.
8. Deshpande SS, Khatu SS, Pardeshi GS, Gokhale NR. Cross-sectional study of psychiatric morbidity in patients with melasma. *Indian J Psychiatry* 2018;60:324-8.
9. Achar A, Rathi SK. Melasma: A clinico-epidemiological study of 312 cases. *Indian J Dermatol* 2011;56:380-2.
10. Esposito ACC, Brianezi G, de Souza NP, Santos DC, Miot LDB, Miot HA. Ultrastructural characterization of damage in the basement membrane of facial melasma. *Arch Dermatol Res* 2020;312:223-227.
11. Kwon SH, Hwang YJ, Lee SK, Park KC. Heterogeneous pathology of melasma and its clinical implications. *Int J Mol Sci* 2016;17:824.
12. Sarkar R, Aurangabadkar S, Salim T, Das A, Sha S, Majid I, *et al.* Lasers in melasma: A review with consensus recommendations by Indian Pigmentary Expert Group. *Indian J Dermatol* 2017;62:585-90.
13. Goldberg D, Metzler C. Skin resurfacing utilizing a low-fluence Nd:YAG laser. *J Cutan Laser Ther* 1999;1:23-7.
14. Choi CP, Yim SM, Seo SH, Ahn HH, Kye YC, Choi JE. Retrospective analysis of melasma treatment using a dual mode of low-fluence Q-switched and long-pulse Nd:YAG laser vs. low-fluence Q-switched Nd:YAG laser monotherapy. *J Cosmet Laser Ther* 2015;17:2-8.
15. Kim JY, Choi M, Nam CH, Kim JS, Kim MH, Park BC, *et al.* Treatment of melasma with the photoacoustic twin pulse mode of low-fluence 1,064nm Q-switched Nd:YAG laser. *Ann Dermatol* 2016;28:290-6.
16. Kim JH, Kim H, Park HC, Kim IH, *et al.* Subcellular selective photothermolysis of melanosomes in adult zebrafish skin following 1064-nm Q-switched Nd:YAG laser irradiation. *J Invest Dermatol* 2010;130:2333-5.
17. Sim JH, Park YL, Lee JS, Lee SY, Choi WB, Kim HJ, *et al.* Treatment of melasma by low-fluence 1064nm Q-switched Nd:YAG laser. *J Dermatolog Treat* 2014;25:212-7.
18. Choi JE, Lee DW, Seo SH, Ahn HH, Kye YC. Low-fluence Q-switched nd:YAG laser for the treatment of melasma in Asian patients. *J Cosmet Dermatol* 2018;17:1053-8.
19. Schmults CD, Phelps R, Glodberg DJ. Nonablative facial remodeling erythema reduction and histologic evidence of new collagen formation using a 300- microsecond 1064-nm Nd:YAG laser. *Arch Dermatol* 2004;140:1373-6.
20. Chiba C, Usui A, Hara H, Ishi Y. Clinical experience in skin rejuvenation treatment in Asians using a long-pulse Nd:YAG laser. *J Cosmet Laser Ther* 2009;11:134-8.
21. Seleit I, Bakry OA, Masoud E, *et al.* Identification of genotypes and allelic frequencies of vitamin D receptor gene polymorphism (TaqI) in Egyptian melasma patients. *Indian Dermatol Online J* 2017;8:443-8.
22. Alam M, Dover JS. Nonablative laser and light therapy: An approach to patient and device selection. *Skin Therapy Lett* 2003;8:4-7.
23. Wattanakrai P, Mornchan R, Eimpunth S. Low-fluence Q-switched neodymium-doped yttrium aluminum garnet 1,064nm laser for the treatment of facial melasma in Asians. *Dermatol Surg* 2010;36:76-87.