



Correspondence

Versatile use of acupuncture needles for radiofrequency ablation in skin appendageal and other disorders

Nikhil Mehta¹ , Ayush Jain¹, Sanjeev Gupta², Somesh Gupta¹ 

¹Department of Dermatology and Venereology, All India Institute of Medical Sciences, New Delhi, ²Department of Dermatology and Venereology, Maharishi Markandeshwar Institute of Medical Sciences and Research, Mullana, Haryana, India.

***Corresponding author:**

Somesh Gupta,
Department of Dermatology
and Venereology, All India
Institute of Medical Sciences,
New Delhi, India.

someshgupta@hotmail.com

Received: 09 May 2024
Accepted: 24 September 2024
Epub Ahead of Print: 04 December 2024
Published:

DOI
[10.25259/jcas_49_24](https://dx.doi.org/10.25259/jcas_49_24)

Quick Response Code:



Supplementary video available
online:
[https://dx.doi.org/10.25259/
jcas_49_24](https://dx.doi.org/10.25259/jcas_49_24)

Dear Editor,

Numerous radiofrequency procedures necessitate the utilization of thin needle electrodes, such as epilation electrodes. These specialized electrodes, designed for precision in therapeutic interventions, exhibit inherent constraints including a prohibitive cost, machine-specific limitations, a confined spectrum of available dimensions, and a lack of flexibility. Moreover, the epilation electrodes are time-consuming, as they are inserted in only one hair follicle at a time, and require time for sterilization in between patients.¹ The sterilization process may often be incomplete. Indirect electrosurgery, in which any radiofrequency electrode is applied to a secondary disposable electrode, alleviates a lot of these problems.²

We utilized acupuncture needles as secondary electrodes for indirect electrosurgery in a diverse array of procedures with good results. Composed predominantly of copper or stainless steel, materials congruent with those employed in the construction of radiofrequency electrodes, acupuncture needles are conveniently packaged in sterile enclosures, each equipped with individual sheaths, and are easily disposable. Copper is a better electrical and thermal conductor and, hence, heats up less at the same power compared to stainless steel, minimizing any unwanted damage due to heated electrodes. We prefer stainless steel electrodes, as most of the radiofrequency probes and electrodes are composed of stainless steel, and using the same material throughout prevents thermal damage to the point of contact of materials with different electrical conductivity/resistance. Notably, these needles are cost-effective and come in various thicknesses and lengths (2.5–4.5 cm), including dimensions suitable for thin radiofrequency electrodes. The cost of 100 acupuncture needles is around 300 rupees (about 3.5 USD), while the cost of a single epilation needle specific to the device is usually around 100 rupees (about 1.2 USD), and it is not usually available as a single piece, and has to be bought as a set from the device manufacturer. The commonly used 31G gauge, measuring 0.25 mm, results in minimal lateral current spread (damage zone of 1–2 mm), making it ideal for very fine lesions.

Usage of acupuncture needles for epilation has already been published. They are useful, particularly in cases where lasers targeting melanin chromophores prove ineffective, like excess white facial hairs,³ and follicular occlusion diseases such as hidradenitis suppurativa, where these needles facilitate permanent hair loss by replacing follicles with minute scars. This approach represents a minimally invasive therapeutic or prophylactic surgery, offering a pragmatic alternative to radical excisions. Usage of multiple needles simultaneously enhances procedural efficiency compared to the traditional one-by-one deployment of single epilation needles for each follicle.¹

This is an open-access article distributed under the terms of the Creative Commons Attribution-Non Commercial-Share Alike 4.0 License, which allows others to remix, transform, and build upon the work non-commercially, as long as the author is credited and the new creations are licensed under the identical terms.

©2024 Published by Scientific Scholar on behalf of Journal of Cutaneous and Aesthetic Surgery

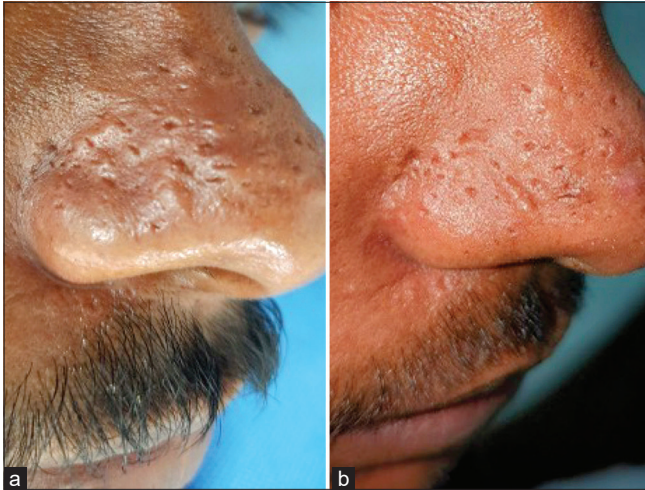

Figure 1: Result of radiofrequency epilation using acupuncture needles for papular acne scars in a patient with previous scarring due to syringe needle-based radiofrequency ablation. (a) Before and (b) after 1 session. No pigmentation or scarring was seen using thin acupuncture needles, in contrast with the previous session with syringe needle needle-based ablation.

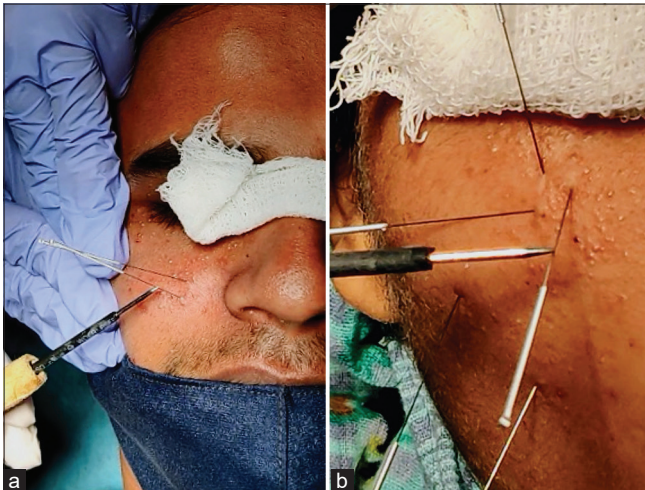

Figure 2: Acupuncture needles for intralesional radiofrequency of multiple solid lesions. (a) Acupuncture needles are placed simultaneously over multiple small solid lesions which can be burnt with minimum peripheral damage and pigmentation in milia or syringomas. (b) Close up view.

Other novel applications include intralesional radiofrequency procedures in small but multiple lesions. In these instances, the utilization of thinner acupuncture needles minimizes epidermal damage, lateral spread, and resultant scarring in contrast to direct electrode insertion. Following the strategic insertion of multiple needles together from diverse angles, the heads can then be delicately touched with any available radiofrequency probe in low-power cutting or coagulation mode, ensuring precision. It also saves time compared to using a single needle to target individual lesions one-by-one.

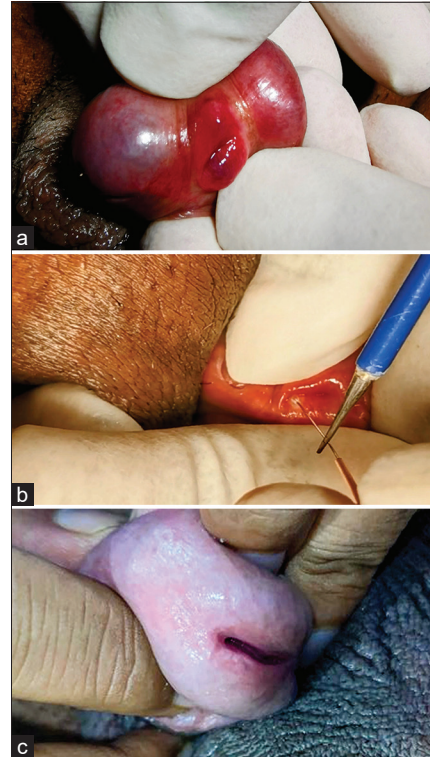
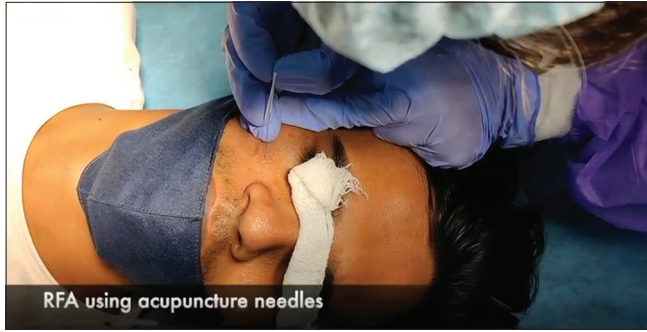

Figure 3: (a-c) Usage of long bent acupuncture needles to access intrameatal warts.

Indications span a spectrum of dermatological conditions, including papular acne scars [Figure 1],⁴ trichoepitheliomas, syringomas [Figure 2],⁵ eccrine and apocrine tumors, steatocystomas, as well as small vascular malformations such as angiokeratomas and venous lakes [Supplementary Video 1].

Difficult-to-access areas present another novel application domain where acupuncture needles excel, such as intrameatal warts and high vaginal warts. In these scenarios, lengthier needles (35–45 mm) prove invaluable in reaching areas inaccessible using conventional electrodes. Notably, these needles can be easily bent or curved to conform to the requisite procedural shape, obviating the necessity for microscopic camera devices while ensuring optimal visualization, which cannot be done for electrodes accompanying the machine [Figure 3].

For targeting multiple appendageal lesions simultaneously, short length (25 mm) needles should be used to prevent crowding, cross-contact, and falling off due to weight, while for bending or fashioning various acupuncture needles into customized electrodes, lengthier needles (35, 45 mm) should be used, to allow sufficient length for bending and handling. The side-effects include risk of pigmentation and scarring, compared to insulated electrodes, especially if acupuncture needles curve/bend and come in contact with normal skin. It can be minimized



Supplementary Video 1: Usage of the acupuncture needles as an alternative to RF electrodes, being used to treat syringomas.

with adequate care, or using forceps to stabilize and direct the needles.

In conclusion, acupuncture needles emerge as a cost-effective and disposable alternative to thin needle electrodes, providing a universal solution compatible with any radiofrequency machine. Their versatility extends across a spectrum of both conventional and innovative indications, rendering them a pragmatic choice in diverse clinical settings.

Authors' contributions

All the authors contributed equally in all the aspects of the manuscript.

Ethical approval

Institutional Review Board approval is not required as the study is a retrospective study.

Declaration of patient consent

The authors certify that they have obtained all appropriate patient consent.

Financial support and sponsorship

Nil.

Conflicts of interest

There are no conflicts of interest.

Use of artificial intelligence (AI)-assisted technology for manuscript preparation

The authors confirm that there was no use of artificial intelligence (AI)-assisted technology for assisting in the writing or editing of the manuscript and no images were manipulated using AI.

REFERENCES

1. Mehta N, Khan E, Gupta S. Radiofrequency epilation using acupuncture needles to decrease the disease burden in hidradenitis suppurativa. *Dermatol Surg* 2022;48:788.
2. De D, Gupta S, Malhotra AK. Indirect electrosurgery. *Dermatol Surg* 2006;32:1424.
3. Gupta S, Shankar Jangra R, Gupta S. A simple and swift radiofrequency-based epilation technique for gray and blonde hair. *J Am Acad Dermatol* 2020;82:e7-8.
4. Seok J, Choi SY, Park KY, Jang JH, Bae JH, Kim BJ, *et al.* Depressed scar after filler injection successfully treated with pneumatic needleless injector and radiofrequency device. *Dermatol Ther* 2016;29:45-7.
5. Huang LP, Zhang L, Wang XL, Liu XC, Jiang TY, Lin BW. A technique for periorbital syringomas: Intralesional radiofrequency ablation. *Int J Ophthalmol* 2012;5:181-5.

How to cite this article: Mehta N, Jain A, Gupta S, Gupta S. Versatile use of acupuncture needles for radiofrequency ablation in skin appendageal and other disorders. *J Cutan Aesthet Surg*. doi: 10.25259/jcas_49_24