



## Case Series

# Success of Mohs surgery in the treatment of basal cell carcinoma in a tier two city in India

Kusumika Kanak<sup>1</sup>, Simran Tuli<sup>2</sup>, Vidyadhar R. Sardesai<sup>2</sup> 

<sup>1</sup>Department of Dermatology and Venereology, Dr Kanak's skin care, <sup>2</sup>Department of Dermatology, Venereology and Leprosy, Bharati Vidyapeeth (Deemed to be University) Medical College, Pune, Maharashtra, India.

### \*Corresponding author:

Simran Tuli,  
Department of Dermatology,  
Venereology and Leprosy,  
Bharati Vidyapeeth (Deemed to  
be University) Medical College,  
Pune, Maharashtra, India.

[simrant3596@gmail.com](mailto:simrant3596@gmail.com)

Received: 19 July 2023  
Accepted: 27 November 2023  
Epub Ahead of Print: 12 September 2024  
Published: 11 February 2025

DOI  
[10.25259/jcas\\_121\\_23](https://doi.org/10.25259/jcas_121_23)

### Quick Response Code:



## ABSTRACT

Basal cell carcinoma (BCC) represents the commonest cutaneous malignancy globally. Its diagnosis in patients with skin of color is often delayed due to its low prevalence which reduces clinical suspicion and its indolent course. Studies on BCC in India are few. Considering that it is a locally invasive tumor commonly seen in the head and neck region, its management calls for the complete clearance of the cancer accompanied by minimal cosmetic disfigurement. One modality fitting the said requirements is Mohs micrographic surgery. However, the facilities for the same are limited in our country. We report here cases of histologically confirmed BCC managed successively with Mohs surgery, a technique associated with low recurrence rates while also being aesthetically superior when compared to traditional surgical excision.

**Keywords:** Basal cell carcinoma, India, Mohs surgery

## INTRODUCTION

Non-melanoma skin cancers (NMSCs), the most common of which is basal cell carcinoma (BCC), have occupied only a small space in the perception of dermatologists in the country, probably due to their lower incidence in Indians in contrast to Caucasians and the presumed protective effect of eumelanin.<sup>1-3</sup>

There is a paucity of studies on BCC from India. Furthermore, esthetic outcomes and recurrence rates of the various treatment modalities have not been adequately evaluated in Indian patients.<sup>2</sup>

Increasing job opportunities in developing cities have led to an increase in the population of expatriates. This, along with better intercity connectivity and increased awareness among people, has led to the detection of a greater number of NMSCs, especially BCC.

Surgery is the keystone of treatment for BCC.<sup>4</sup> Mohs micrographic surgery (MMS) is a specialized form of tissue-preserving surgery in which cure rates close to 100% are achieved with minimal tissue removal.<sup>5</sup>

## CASE SERIES

We performed MMS on multiple cases of BCC in Indians as well as expatriates, of which three have been described here.

This is an open-access article distributed under the terms of the Creative Commons Attribution-Non Commercial-Share Alike 4.0 License, which allows others to remix, transform, and build upon the work non-commercially, as long as the author is credited and the new creations are licensed under the identical terms.

©2025 Published by Scientific Scholar on behalf of Journal of Cutaneous and Aesthetic Surgery

### Case 1

An 83-year-old Indian lady presented with a non-healing ulcer near the right ear. The lesion began as a hyperpigmented papule that eventually grew in size and ulcerated [Figure 1a]. The patient could not seek medical help due to the COVID-19 pandemic. She consulted us in 2022, 2 years after the onset of the lesion. Mohs surgery was performed following histopathological confirmation of diagnosis. Simple closure was done [Figure 1b and c]. A 6-month follow-up showed no recurrence.

### Case 2

A Brazilian national aged 46 years presented in 2019 with a history of a small papular lesion near the inner canthus of the right eye, which had gradually increased in size over a few months, with an associated history of occasional bleeding [Figure 2a]. A biopsy was done to confirm the diagnosis and MMS was performed. This was followed by closure using a rhomboid flap by a plastic surgeon [Figure 2b and c]. The

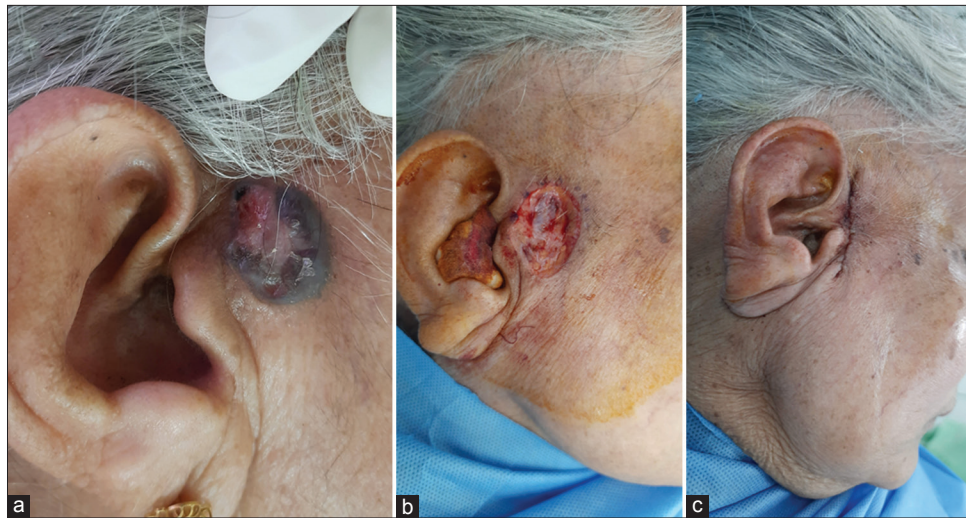patient gave no history of recurrence till 2022, the time of last contact with the patient.

### Case 3

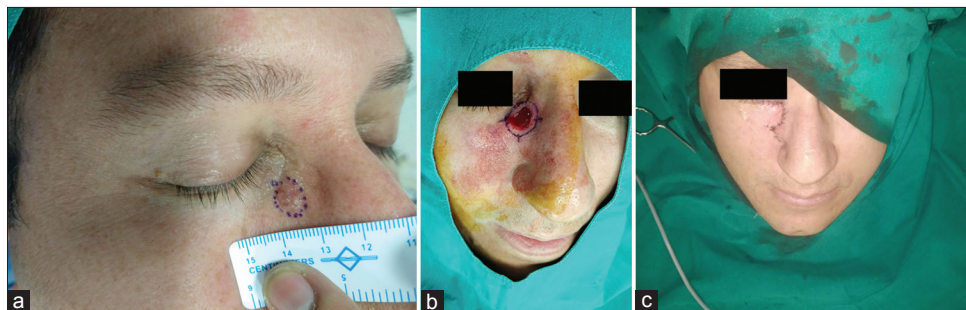
A 65-year-old from a rural area in India was referred to us in 2018 with an ulcer on the tip of the nose for many years. Two sessions of electrocauterization and three of radio frequency removal had been carried out in the past. However, the lesion kept recurring. The current presentation was that of a non-healing ulcer with bloody discharge [Figure 3a]. Histopathological confirmation was followed by curettage and MMS. Plastic surgery was done for repair. Paramedian forehead flap was used [Figure 3b-d]. The patient followed up till 2023 with no evidence of recurrence [Figure 3e].

We were able to perform the procedure on patients from Brazil, Italy, and India.

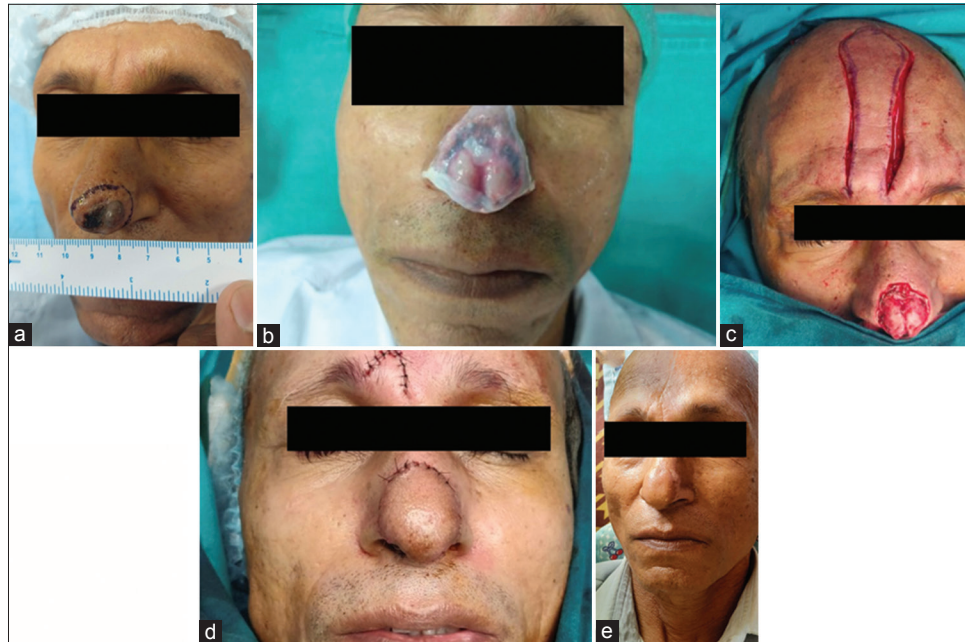It was observed that Indian patients too presented with BCC, highlighting the need to bear in mind the possibility of BCC in patients of skin color. In cases that presented with recurrence



**Figure 1:** Case 1- (a) A pigmented noduloulcerative basal cell carcinoma, (b) intraoperative picture of case 1, and (c) post-operative closure without flap.



**Figure 2:** Case 2-(a) basal cell carcinoma at the inner canthus of the right eye, (b) intraoperative picture of case 2, and (c) closure using a rhomboid flap.



**Figure 3:** Case 3-(a) A recurrent pigmented noduloulcerative basal cell carcinoma on tip of the nose, (b) intraoperative picture of case 3 with collagen dressing, (c) paramedian forehead flap, (d) post-operative image, and (e) follow-up image in 2023 with no recurrence.

following prior treatment with non-excisional ablative techniques and conventional surgical excision, one such example being case three, MMS proved to be of benefit. An interesting observation was a lower age of presentation in expatriates, which could be attributed to their greater awareness of BCC.

Despite limited infrastructure, with certain modifications, Mohs surgery was performed successfully. No recurrences were reported, with the follow-up period being up to 5 years in some patients.

## DISCUSSION

BCC is a locally invasive tumor that rarely metastasizes.<sup>2</sup> The most common etiologic factor is ultraviolet radiation.<sup>3</sup> The cancer runs an indolent course and is usually ignored by patients, who consequently do not seek medical attention for long periods. In addition, due to its rarity in the Indian population, it may not be diagnosed promptly by primary care physicians, causing further delay in diagnosis.<sup>2</sup>

Most lesions are found on the head and neck, indicating a propensity towards sun-exposed areas, and elucidating the need for esthetically elegant treatment modalities.<sup>3</sup>

The lynchpin of management is surgical extirpation, which can be achieved through non-excisional ablative techniques, conventional surgical excision, and MMS.<sup>1</sup> Conventionally, surgical excision using an elliptical excision with a 4 mm surgical margin of clinically normal skin was done.<sup>6</sup>

Mohs surgery has now become the preferred therapeutic modality. It was reported to have the lowest recurrence rate of any treatment modality in a large prospective series.<sup>7</sup>

MMS originally required *in situ* tissue fixation before excision. Future modifications led to the use of fresh tissue techniques exclusively. A thin margin of tissue surrounding the clinically visible portion of the lesion is removed, followed by fresh tissue frozen histology. This procedure is repeated until the tumor achieves negative histologic margins.<sup>4</sup>

For embedding, a mold is taken depending on the size of the tissue. Initially, a small amount of liquid paraffin is placed. Then, maintaining the integrity of the specimen, it is put in a proper orientation mold. The tissue is at all times in one plane and is parallel to the bottom of the mold. The specimen is then covered completely with liquid paraffin. Immediate cooling is done to avoid the crystallization of paraffin. For sectioning, the tissue sample needs to be frozen at  $-15 - -25^{\circ}\text{C}$ . Once the correct temperature is reached the cryostat slices the specimen to a thickness of  $5\ \mu\text{m}$ . The microtome creates many sections of a single tissue.

In the cases operated, we took a section width of 3–4 mm.

MMS allows precise microscopic control over tumor margins, aiding tissue conservation, and resulting in smaller surgical defects as compared to standard excision.<sup>4</sup> This makes it an ideal choice for functionally and cosmetically sensitive locations such as the head, neck, genitalia, hands, and feet.<sup>5</sup>

## CONCLUSION

We observed that recurrence rates were consistently and notably lower with Mohs in comparison to surgical excision treatment. The cosmetic result was found to be superior. An index of suspicion for BCC should be maintained even in patients of skin color. We could treat patients with BCC with the most beneficial option available to them with a high degree of patient satisfaction.

**Authors' contributions:** Dr. Kusumika Kanak: Concepts, design, definition of intellectual content, data acquisition, literature search, manuscript preparation, manuscript editing, manuscript review, guarantor. Dr. Simran Tuli: Concepts, design, definition of intellectual content, literature search, manuscript preparation, manuscript editing, manuscript review, guarantor. Dr. Vidyadhar R. Sardesai: Concepts, design, definition of intellectual content, literature search, manuscript editing, manuscript review, guarantor.

**Ethical approval:** Institutional Review Board approval is not required.

**Declaration of patient consent:** The authors certify that they have obtained all appropriate patient consent.

**Financial support and sponsorship:** Nil.

**Conflicts of interest:** There are no conflicts of interest.

**Use of artificial intelligence (AI)-assisted technology for manuscript preparation:** The authors confirm that there was no use of artificial intelligence (AI)-assisted technology for assisting in the writing or editing of the manuscript and no images were manipulated using AI.

## REFERENCES

1. Panda S. Nonmelanoma skin cancer in India: Current scenario. *Indian J Dermatol* 2010;55:373-8.
2. Mahajan S, Kalaivani M, Sethuraman G, Khaitan BK, Verma KK, Gupta S. A retrospective comparative study of outcome with surgical excision and repair versus nonsurgical and ablative treatments for basal cell carcinoma. *Indian J Dermatol Venereol Leprol* 2021;87:348-56.
3. Bradford PT. Skin cancer in skin of color. *Dermatol Nurs* 2009;21:170-7, 206; quiz 178.
4. Bali S, Deif EA, Rajeev A. Treatment of basal cell carcinoma: An overview. *J Skin Sex Transm Dis* 2022;4:171-7.
5. Mansouri B, Bicknell LM, Hill D, Walker GD, Fiala K, Housewright C. Mohs micrographic surgery for the management of cutaneous malignancies. *Facial Plast Surg Clin North Am* 2017;25:291-301.
6. Quazi SJ, Aslam N, Saleem H, Rahman J, Khan S. Surgical margin of excision in basal cell carcinoma: A systematic review of literature. *Cureus* 2020;12:e9211.
7. Narayanan K, Hadid OH, Barnes EA. Mohs micrographic surgery versus surgical excision for periocular basal cell carcinoma. *Cochrane Database Syst Rev* 2014;2014:CD007041.

**How to cite this article:** Kanak K, Tuli S, Sardesai VR. Success of Mohs surgery in the treatment of basal cell carcinoma in a tier two city in India. *J Cutan Aesthet Surg*. 2025;18:19-22. doi: 10.25259/jcas\_121\_23